Second Case

DISEASE *Pyaemic Sinus Thrombosis*

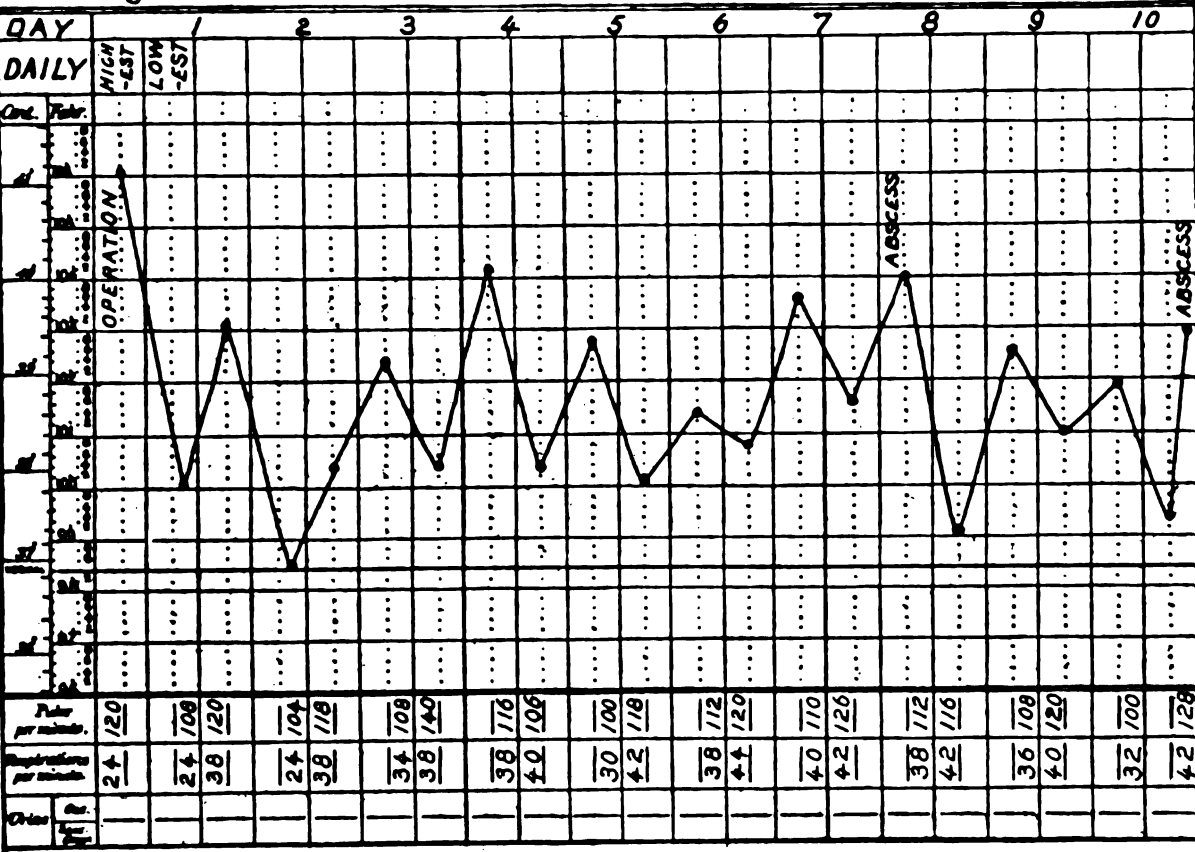

THE DAILY FLUCTUATIONS HEREAFTER WERE INSIGNIFICANT EXCEPT UPON THE FORMATION OF TWO ABSCESSES, WHEN THERE WAS A SHARP RISE OF SEVERAL DEGREES FOLLOWED BY IMMEDIATE DECLINE UPON EVACUATING THE PUS



ARCHIVES

OF

OTOLOGY

EDITED IN ENGLISH AND GERMAN

BY

DR. H. KNAPP
OF NEW YORK

DR. O. KÖRNER
OF ROSTOCK

DR. A. HARTMANN AND DR. U. PRITCHARD
OF BERLIN OF LONDON

VOLUME XXVII

NEW YORK
G. P. PUTNAM'S SONS, 27 & 29 WEST 23D STREET
AND NEW ROCHELLE, N. Y.
LONDON: 24 BEDFORD STREET, STRAND
WIESBADEN: J. F. BERGMANN'S Verlag
PARIS: J. B. BAILLIÈRE, 19 Rue Hautefeuille
1898

CONTENTS OF VOLUME XXVII.

NUMBER I.

PAGE

1. Observations Made in the Caisson of the New East River Bridge as to the Effects of Compressed Air upon the Human Ear. By **John C. Lester**, M.D., and **Vincent Gomez**, M.D. . . . 1

2. A Case of Internal-Ear Deafness, Following Mumps, Treated with Pilocarpine—Recovery. By **F. W. Jollye**, F.R.C.S., D.P.H. 20

3. A Case of Bezold Mastoiditis with Extension to the Posterior Part of the Neck. By Dr. **J. Guttman** 23

4. A Contribution to the Symptomatology and Treatment of Pyæmic Sinus Thrombosis, Based upon Three Successfully Operated Cases. By **Fred. Whiting**, M.D. 26

5. Systematic Report on the Progress of Otology in the Second Quarter of the Year 1897. Compiled by Dr. **Arthur Hartmann.** Translated by Dr. ARNOLD H. KNAPP 72

6. Report on the Section for Otology at the XII. International Medical Congress, Moscow, August 19–26, 1897. By Dr. **Zwingmann**, Kursk. Translated by Dr. ARNOLD H. KNAPP, New York 95

7. Report of the Transactions of the Section of Ophthalmology and Otology in the New York Academy of Medicine. Otological Part of the Meeting of January 17, 1898 108

8. Book Reviews 111
   Lehrbuch der Ohrenheilkunde. By Prof. L. Jacobson.

9. Miscellaneous Notes 113

10. Contents of the Latest Numbers of the *Zeitschrift für Ohrenheilkunde* 113

VOL. XXVII. No. 1.

ARCHIVES OF OTOLOGY.

OBSERVATIONS MADE IN THE CAISSON OF THE NEW EAST RIVER BRIDGE AS TO THE EFFECTS OF COMPRESSED AIR UPON THE HUMAN EAR.

By JOHN C. LESTER, M.D.,

FELLOW OF THE AMERICAN ACADEMY OF MEDICINE; FELLOW OF THE AMERICAN LARYNGOLOGICAL, RHINOLOGICAL, AND OTOLOGICAL SOCIETY; ASSISTANT SURGEON, NEW YORK EYE AND EAR INFIRMARY; ASSISTANT SURGEON, ST. BARTHOLOMEW'S CLINIC, ETC.,

AND

VINCENT GOMEZ, M.D.,

OPHTHALMOLOGIST TO THE ALMSHOUSE, WORKHOUSE, AND INCURABLE HOSPITALS; ASSISTANT SURGEON, NEW YORK EYE AND EAR INFIRMARY; INSTRUCTOR IN DISEASES OF THE EAR, NEW YORK POLYCLINIC, ETC.

THROUGH the courtesy of the officials of the new East River Bridge, we have been accorded the privilege of making some extended observations and experiments as to the influence of compressed air upon the ear. The results which we have obtained seem to us of sufficient interest to warrant publication. In order to eliminate, as far as possible, the so-called personal equation, we deemed it of importance, at the outset, to select our subjects from persons sufficiently intelligent to give accurate and reliable statements. All the cases reported were carefully examined under conditions peculiarly favorable for obtaining the best possible records; for example, the majority of cases were examined after a period of rest. Besides, all of them were in an average state of health.

For purposes of comparison all the cases, with one exception, were examined prior to their entrance into the caisson. This was done to obviate any neurotic element on the part of the patient, as well as to eliminate any changes that might have been produced in their physical status by being subjected to unusual conditions.

Our method of recording the cases has been in accordance with a table prepared by the writers, and published in the *New York Eye and Ear Infirmary Reports*, January, 1897. The ages of the cases examined range from twenty to forty-five. Their occupations were as follows: Physicians, 5; mechanical engineer, 1; foreman, 1; electrical engineer, 1.

The tuning-forks employed were the Hartman series plus the C–1, or Contra C, fork. The same set was employed in every case; the average reaction of the forks in this set was obtained after carefully examining several persons with normal organs of hearing, and for purposes of comparison the averages thus obtained are herewith presented:

c	c^{I}	c^{II}	c^{III}	c^{IV}
23	24	28	37	19
12	13	15	15	13

The Galton whistle employed was the one modified by Dench, a description of which may be found in this writer's book on *Diseases of the Ear*.[1]

To obtain exact records for the Schwabach, or absolute duration test, a stop-watch of special construction, suggested by the writers, was employed. The normal hearing distance for this watch is seventy-two inches.

The more or less marked differences in the results obtained in Cases 6 and 7, as compared with the rest of the cases, is explained by the fact that both these cases were examined on a holiday, when the pressure was reduced one half an atmosphere. This, to us, though accidental, has been especially interesting as establishing the fact that the hearing power, both for bone and aërial conduction, is reduced directly in proportion to the atmospheric pressure.

Cases 1, 2, 3, 4, and 5 were examined under a pressure of two and one half atmospheres. Cases 6 and 7, as before indicated, were examined under a pressure of two atmospheres. The rule observed by the engineers of the new East River Bridge in regard to the amount of pressure employed, is one pound of pressure for each two feet of depth.

[1] *Diseases of the Ear*, Dench, p. 156.

The actual size of the caisson proper in which these experiments were conducted is, in length, seventy-six feet; breadth, sixty feet; depth, eight feet. The number of men who can work at a given time in this place—which, as will be seen, contains 36,480 cubic feet—is fifteen. In one atmosphere of pressure it is entirely possible for a man in average health to continue work for about eight hours. In a pressure of two atmospheres about four hours is the limit. Thus it will be seen that the hours of labor which the average man can endure are in direct proportion to the depth of the caisson and to the amount of air pressure. This has been absolutely determined to be .43 of a pound for each vertical foot of excavation.

An interesting fact which we might mention in this connection, is the remarkably high temperature of the compressed air in the receiving tank. We would estimate this to be about 148° F. The air, after leaving the tank through specially constructed tubes, is conducted through a water-cooler, and from there it is forced into the caisson proper, where it has a temperature of about 70° F. The humidity of the atmosphere in the caisson is 100 per cent., or saturation.

Before presenting reports of the individual cases seriatim, a statement of the sensations experienced by the writers during their entrance and exit from the caisson, as well as the phenomena noted during their stay in the caisson proper, cannot be devoid of interest.

First, as to the morale. No one, we are sure, whether he be phlegmatic or neurotic, or whether he have a combination of both courage and enthusiasm, can fail to experience a certain degree of trepidation at the moment of entering an iron cylinder which is less than three feet in diameter. The sensations of fear are doubly increased as one descends into the "lock" by means of a very narrow iron ladder. But three persons can occupy the "lock" proper at one time. The closing of the "lock," the absolute Erebus-like darkness, and the gradual introduction of compressed air, which enters through a valve at the floor with a tremendous hissing noise, greatly adds to the person's confusion. It is

at this point that the greatest mental excitement is experienced; and it is not to be wondered at that so many, when they contemplate their uncanny and weird surroundings—standing as they do on a piece of iron about five inches in width extending from the side of the cylinder, with a door opening downward—are so struck with fear that they refuse absolutely to proceed farther. This occurred in Case 8, whose examination, prior to his entrance within the "lock," showed a condition of chronic middle-ear catarrh, with incipient sclerosis of the drum-membrane. This case is reported in an incomplete form for the purpose of showing the extreme nervous disturbance which is apt to occur in one in whom the neurotic element predominates, and in whom there are pathological processes present in the organs of hearing.

After the closing of the "lock," the air almost immediately becomes vitiated, and consequently oppressive. The gradual entrance of the compressed air at this point is especially grateful, reassuring, and stimulating; but as the pressure is increased the sensations vary with the idiosyncrasies of the subject. For instance, one of the writers, who had, in early life, sustained a fracture of the inferior maxillary bone, experienced an acute lancinating pain in this region. The pain subsided when the pressure became equalized. Both of the writers, at first, experienced a slight sensation of fulness in both ears, which was relieved, in the beginning, by keeping the mouth open. As the pressure increased, this sensation of fulness was accompanied by a distinct, forcible "pushing in" of the drum-membranes to such an extent that rupture seemed imminent. These sensations were, however, overcome by repeatedly performing Valsalva's experiment. Notwithstanding the enormous pressure to which the tympanic membranes were subjected, neither of the writers experienced either pain or vertigo. This is likewise true of the other members of the party, whose records will be found in another portion of this article.

There was coupled with this sensation of fulness of the drum-membrane, a violent, very high-pitched, hissing tin-

nitus. In the case of one of the writers the tinnitus was at first of a roaring character. The respiratory organs were in no way embarrassed. But if one is suffering from a coryza, or any catarrhal condition of the respiratory tract, especially the upper air passages, he will not be able to remain in the caisson for any length of time. Moreover, any acute catarrhal condition of the upper air passages precludes the possibility of an individual entering the caisson. Even those who have worked for years in caissons, and who are accustomed to these conditions, are unable to continue work when suffering from even a slight cold.

Although we did not intend to make any observations on the general circulation, still the disturbance of the heart's action was so marked that we were led, in a general way, to observe the pulse-rate in the majority of our cases. The average radial pulse-rate before entering the caisson was seventy-six per minute, and after making our exit from the caisson it was one hundred and twenty per minute. The tinnitus, the conscious depression of the drum-membrane, and the extreme sensation of fulness in the ear subsided on entering the caisson proper.

Among the striking phenomena noted on entering the caisson were the peculiar pitch, timbre, and intensity of the voice, and autophony. Difficulty in speaking was also noted, as well as the impossibility of whistling the higher notes. The time spent in the caisson—three hours—was unattended with any unpleasant sensations, and it was possible to conduct the examinations with as great accuracy as could have been done under more favorable circumstances. The same phenomena experienced on entering the caisson were experienced in our exit from it, except that they were less marked in every instance.

After leaving the "lock" and reaching our dressing-rooms —it having been necessary to wear waterproof clothing in the caisson—a marked feeling of exhaustion, depression, and muscular fatigue was observed, which continued for different periods, varying in duration from eight to forty-eight hours. Of these the muscular fatigue was the most pronounced.

In all the cases examined the hearing distance for the

watch, whisper, speech, etc., was determined by actual measurement, employing for this purpose the extra long tape-measure used by surveyors. The watch used has already been referred to, also the Galton's whistle, and likewise the tuning-forks.

In taking the hearing distance for the whisper and speech, notice was taken of Bezold's recent investigations, who found that the low tones in the words "one hundred" are perceived with the greatest difficulty in affections of the conducting apparatus.[1] In acute inflammations of the middle ear he found a characteristic loss for "fifteen" and "three." He states that the loss of the word "seven" is especially unfavorable from a prognostic standpoint, as indicating labyrinthine disease.

The logographic value of certain consonants, as determined by Blake, who found that the relative intensity of consonant sounds varied, was also employed in our tests. It will be recalled that according to Blake's table the T sound, being the one of greatest intensity, is denominated 100, G and B being about the middle register of intensity, and M the lowest, which is represented by 9 in the scale.

Besides employing test sentences to determine the hearing distance for the whisper and speech, as used by many, we also used numbers of two figures, as recommended by Siebenmann.[2] In using the Galton's whistle care was taken to warn the subject to distinguish between the blowing sound and the actual note of the whistle. In taking the watch, whisper, and speech, the ear, not being examined, was occluded, and the subject was so placed that the ear under examination was, as nearly as possible, in direct line with the source of sound.

To obviate the possibility of the person anticipating the various test words, numbers, etc., they were not employed consecutively, but at random. Moreover, when taking the bone conduction the forks were placed upon the mastoid process on a line with the superior border of the external

---

[1] "On the Present State of the Various Tests for Hearing," ARCHIVES OF OTOLOGY, vol. xxv., No. 2, p. 274.

[2] ARCHIVES OF OTOLOGY, vol. xxii., p. 1.

auditory canal, in order to ascertain the bone conduction from a definite location in each case, and in a position relatively near the mastoid antrum. In taking the Weber test the C fork was used and placed upon the central incisors of the upper jaw, it having been ascertained that this test, taken in this position, is more reliable than when taken at the vertex or at the glabella.

The histories and findings in the individual cases, as per order of their examination, will now be presented.

CASE I.—Physician, age 41, physical condition good.

The functional examination on August 29, 1897, revealed the following conditions of the organs of hearing:

Right ear.—Watch, 80″; whisper, 41′; speech, 41′; Politzer's acoumeter, 41′; Galton's whistle, 2.5; lower-tone limit, 16; Weber's test, negative.

Reaction to tuning-forks:

	C	c	c^{I}	c^{II}	c^{III}	c^{IV}
Rinné:	a. c.	a. c.	a. c.	a. c.	a. c.	a. c.
Schwabach:	55	31	35	34	30	18
	12	12½	10½	7	11	7

Left Ear.—Watch, 80″; whisper, 41′; speech 41′; Politzer's acoumeter, 41′; Galton's whistle, 2.3; lower-tone limit, 16; Weber's test, negative.

Reaction to tuning-forks:

	C	c	c^{I}	c^{II}	c^{III}	c^{IV}
Rinné:	a. c.	a. c.	a. c.	a. c.	a. c.	a. c.
Schwabach:	57	24	26	32	30	20½
	12	10	11	9	10	11

Otoscopic examination:

Right Ear.—Slight retraction of the drum-membrane; light reflex somewhat reduced in size; general appearance, normal.

Left Ear.—The same as right.

Examination in the caisson on September 1, 1897, gave the following results:

Right Ear.—Watch, 3″; whisper, 22′; speech, 32′; Politzer's acoumeter, 25′; Galton's whistle, .9; lower-tone limit, 16; Weber's test, negative.

Reaction to tuning-forks:

	C	c	c^{i}	c^{ii}	c^{iii}	c^{iv}
Rinné:	a. c.	a. c.	a. c.	a. c.	a. c.	a. c.
Schwabach:	18	15	10	8½	8½	4
	6	5	1	0	0	0

Left Ear.—Watch, 3″; whisper, 32′; speech, 32′; Politzer's acoumeter, 25′; Galton's whistle, 1.4; lower-tone limit, 16; Weber's test, negative.

Reaction to tuning-forks:

	C	c	c^{i}	c^{ii}	c^{iii}	c^{iv}
Rinné:	a. c.	a. c.	a. c.	a. c.	a. c.	a. c.
Schwabach:	15	8	7½	7½	5	4
	5	3	1	0	0	0

Otoscopic examination:

Right Ear.—Marked retraction of the drum-membrane; light reflex dull, small, and central; moderate injection of malleolar plexus and membrana flaccida.

Left Ear.—The same as right, except that there was more retraction of the drum-membrane.

In this case there was more or less difficulty in perceiving the consonants G and L.

CASE 2.—Physician, age 24, physical condition good.

The functional examination made on August 29, 1897, gave the following results:

Right Ear.—Watch, 60″; whisper, 41′; speech, 41′; Politzer's acoumeter, 41′; Galton's whistle, 1.9; lower-tone limit, 16; Weber's test, negative.

Reaction to tuning-forks:

	C	c	c^{i}	c^{ii}	c^{iii}	c^{iv}
Rinné:	a. c.	a. c.	a. c.	a. c.	a. c.	a. c.
Schwabach:	50	23	24	25	23	7
	9	11	7	12	11	14

Left Ear.—Watch, 60″; whisper, 41′; speech, 41′; Politzer's acoumeter, 41′; Galton's whistle, 1.7; lower-tone limit, 16.

Reaction to tuning-forks:

	C	c	c^{i}	c^{ii}	c^{iii}	c^{iv}
Rinné:	a. c.	a. c.	a. c.	a. c.	a. c.	a. c.
Schwabach:	36	20	22	24	22	13
	10	12	8	9	9	6

Otoscopic examination :

Both drum-membranes were apparently in a normal condition. On September 1, 1897, the examination made in the caisson resulted as follows :

Right Ear.—Watch, 2″ ; whisper, 25′ ; speech, 32′ ; Politzer's acoumeter, 32′ ; Galton's whistle, 1.5 ; lower-tone limit, 16 ; Weber's test, negative.

Reaction to tuning-forks :

	C	c	c^{I}	c^{II}	c^{III}	c^{IV}
Rinné :	a. c.	a. c.	a. c.	a. c.	a. c.	a. c.
Schwabach :	24	15	10	13	10	4
	7	5	7	0	3	0

Left Ear.—Watch, 2″ ; whisper, 25′ ; speech, 32′ ; acoumeter, 32′ ; Galton's whistle, 1.8 ; lower-tone limit, 16 ; Weber's test, negative.

Reaction to tuning-forks :

	C	c	c^{I}	c^{II}	c^{III}	c^{IV}
Rinné :	a. c.	a. c.	a. c.	a. c.	a. c.	a. c.
Schwabach :	23	11	9	17	5	3
	9	7	0	0	0	0

Otoscopic examination :

Right Ear.—Moderate retraction of drum-membrane ; hammer handle appears foreshortened and rotated on its long axis ; congestion of malleolar plexus, especially of upper third. Congestion also of membrana flaccida.

Left Ear.—Appearances about the same as the right.

Case 3.—Physician, age 30, physical condition is explained in foot-note.[1] Examination on September 1, 1897, in the caisson revealed the following facts :

Right Ear.—Watch, 3″ ; whisper, 27′ ; speech, 32′ ; acoumeter, 25′ ; Galton's whistle, 1.9 ; lower-tone limit, 16 ; Weber's test, negative.

Reaction to tuning-forks :

	C	c	c^{I}	c^{II}	c^{III}	c^{IV}
Rinné :	a. c.	a. c. = b. c.	a. c.	a. c.	a. c.	a. c.
Schwabach :	13	7	10	8	6	4
	10	7	7	0	2½	1

[1] This case was suffering, at the time of the examination, with chronic nephritis of two years' standing. Owing to his sudden departure from the city, we were unable to make more than one examination.

Left Ear.—Watch, 3″; whisper, 27′; speech, 32′; acoumeter, 25′; Galton's whistle, .9; lower-tone limit, 16.

Reaction to tuning-forks:

	C	c	c^{I}	c^{II}	c^{III}	c^{IV}
Rinné:	a. c.	a. c.	a. c.	a. c.	a. c.	a. c.
Schwabach:	12	10	7	6½	4	3
	9	7	4	2½	1½	0

Otoscopic examination:

Right Ear.—Very slight retraction of drum-membrane; some congestion of lower portion of malleolar plexus.

Left Ear.—About the same as the right ear.

CASE 4.—Engineer, age 20, physical condition good.[1] Examination made in the caisson September 1, 1897, resulted as follows:

Right Ear.—Watch, 3″; whisper, 32′; speech, 32′; acoumeter, 25′; Galton's whistle, 1.2; lower-tone limit, 16; Weber's test, negative.

Reaction to tuning-forks:

	C	c	c^{I}	c^{II}	c^{III}	c^{IV}
Rinné:	a. c.	a. c.	a. c.	a. c	a. c.	a. c.
Schwabach:	15	10	12	9	8	4
	8	10	8	3	4	0

Left Ear.—Watch, 3″; whisper, 32′; speech, 32′; acoumeter, 26′; Galton's whistle, 1.2; lower-tone limit, 16.

Reaction to tuning-forks:

	C	c	c^{I}	c^{II}	c^{III}	c^{IV}
Rinné:	a. c.	a. c.	a. c.	a. c.	a. c.	a. c.
Schwabach:	17	8	11	7	5	4
	10	7	7	3	3	0

Otoscopic examination:

Right Ear.—Marked retraction of drum-membrane; the membrane diffusely dull; light reflex absent; hammer handle foreshortened and rotated forward; injection of malleolar plexus and of Schrapnell's membrane.

Left Ear.—Same as right.

On September 10, 1897, the examination made outside of the caisson resulted as follows:

[1] This case was examined first in the caisson, and several days after (September 10, 1897) was examined again under normal conditions.

Right Ear.—Watch, 60″; whisper, 40′; speech, 40′; acoumeter, 35′; Galton's whistle, 1.6; lower-tone limit, 16.

Reaction to tuning-forks:

	C	c	c^{i}	c^{ii}	c^{iii}	c^{iv}
Rinné:	a. c.	a. c.	a. c.	a. c.	a. c.	a. c.
Schwabach:	27	22	16	16	19	20
	17	14	10	5	6	4

Otoscopic examination:

Right Ear: Very moderate retraction of drum-membrane; light reflex small and poorly defined; drum-membrane diffusely dull, but not injected.

Left Ear.—Watch, 60″; whisper, 40′; speech, 40′; acoumeter, 35′; Galton's whistle, 1; lower-tone limit, 16.

Reaction to tuning-forks:

	C	c	c^{i}	c^{ii}	c^{iii}	c^{iv}
Rinné:	a. c.	a. c.	a. c.	a. c.	a. c	a. c.
Schwabach:	22	20	16	20	17	17
	15	14	12	5	5	9

Case 5.—Foreman, age 45, physical condition good. Examination in caisson on September 1, 1897[1]:

Right Ear.—Watch, 2″; whisper, 30′; speech, 40′; acoumeter, 20′; Galton's whistle, 1.4; lower-tone limit, 16; Weber's test, negative.

Reaction to tuning-forks:

	C	c	c^{i}	c^{ii}	c^{iii}	c^{iv}
Rinné:	a. c	a. c.	a. c.	a. c.	a. c.	a. c.
Schwabach:	15	10	12	18	17	8
	3	7	7	0	0	0

Left Ear.—Watch, 2″; whisper, 30′; speech, 40′; acoumeter, 18′; Galton's whistle, 1.3; lower-tone limit, 16.

Reaction to tuning-forks:

	C	c	c^{i}	c^{ii}	c^{iii}	c^{iv}
Rinné:	a. c	a. c.	a. c.	a.c.	a. c.	a. c.
Schwabach:	18	8	8	14	15	9
	12	7	8	0	0	0

[1] Has been engaged in caisson work for more than twenty years. First examination made in caisson, September 1, 1897.

Otoscopic examination:

With the exception of a slight retraction of the drum-membrane, there were no changes noticed.

On September 10, 1897, a second examination of this case outside of the caisson resulted as follows:

Right Ear.—Watch, 20″; whisper, 40′; speech, 40′; acoumeter, 27′; Galton's whistle, 1.9; lower-tone limit, 16; Weber's test, negative.

Reaction to tuning-forks:

	C	c	c^{i}	c^{ii}	c^{iii}	c^{iv}
Rinné:	a. c.	a. c.	a. c.	a. c.	a. c.	a. c.
Schwabach:	23	15	16	19	18	16
	12	9	10	6	4	9

Left Ear.—Watch, 16″; whisper, 40′; speech, 40′; acoumeter, 26′; Galton's whistle, 1.9; lower-tone limit, 16.

Reaction to tuning-forks:

	C	c	c^{i}	c^{ii}	c^{iii}	c^{iv}
Rinné:	a. c.	a. c.	a. c.	a. c.	a. c.	a. c.
Schwabach:	20	15	18	18	19	16
	9	11	9	8	7	5

Vowels and consonants were badly heard, especially A and D.

Case 6.—Physician, age 25, physical condition good. Examination, August 29, 1897:

Right Ear.—Watch, 60″; whisper, 41′; speech, 41′; acoumeter, 41′; Galton's whistle, 1.8; lower-tone limit, 16.

Reaction to tuning-forks:

	C	c	c^{i}	c^{ii}	c^{iii}	c^{iv}
Rinné:	a. c.	a. c = b. c.	a. c.	a. c.	a. c.	a. c.
Schwabach:	53	25	23	32	29	22
	9½	9	7½	11	18	9

Left Ear.—Watch, 60″; whisper, 41′; speech, 41′; acoumeter, 41′: Galton's whistle, 1.8; lower-tone limit, 16; Weber's test, negative.

Reaction to tuning-forks:

	C	c	c^{i}	c^{ii}	c^{iii}	c^{iv}
Rinné:	a. c.	a. c.	a. c.	a. c.	a. c.	a. c.
Schwabach:	45	25	24	30	33	16
	14	8	11	12	6	7

On September 1, 1897, examination in the caisson:

Right Ear.—Watch, 4″; whisper, 32′; speech, 32′; acoumeter, 21′; Galton's whistle, 1.9; lower-tone limit, 16; Weber's test negative.

Reaction to tuning-forks:

	C	c	c^{I}	c^{II}	c^{III}	c^{IV}
Rinné:	a. c.	a. c.	a. c.	a. c.	a. c.	a. c.
Schwabach:	25	23	14	16	24	12
	15	8	7	8	8	8

Left Ear.—Watch, 4″; whisper, 32′; speech, 32′; acoumeter, 22′; Galton's whistle, 1.9; lower-tone limit, 16.

Reaction to tuning-forks:

	C	c	c^{I}	c^{II}	c^{III}	c^{IV}
Rinné:	a. c.	a. c.	a. c.	a. c.	a. c.	a. c.
Schwabach:	40	30	23	25	25	13
	13	9	13	7	8	5

Otoscopic examination:

Right Ear.—Impacted cerumen, rendering it impossible to see the drum-membrane.

Left Ear.—Moderate retraction of the drum-membrane; light reflex normal; congestion of malleolar plexus and of membrana flaccida. In testing the whisper distance in the caisson, T and G could not be heard at the recorded distance (32 feet).

CASE 7.—Electrical engineer, age 30, physical condition good.

September 1, 1897. The various tests made in the caisson resulted as follows:

Right Ear.—Watch, 2″; whisper, 20′; speech, 32′; acoumeter, 20′; Galton's whistle, 2.6; lower-tone limit, 16; Weber's test, negative.

Reaction to tuning-forks:

	C	c	c^{I}	c^{II}	c^{III}	c^{IV}
Rinné:	a. c.	a. c.	a. c.	a. c.	a. c.	a. c.
Schwabach:	30	16	14	17	18	10
	12	7	6	6	4	4

Left Ear.—Watch, 6″; whisper, 32′; speech, 40′; acoumeter, 12′; Galton's whistle, 2.4; lower-tone limit, 16; Weber's test, negative.

Reaction to tuning-forks :

	C	c	c^{i}	c^{ii}	c^{iii}	c^{iv}
Rinné :	a. c.	a. c.	a. c.	a. c.	a. c.	a. c.
Schwabach :	30	17	12	17	19	4
	17	7	4	3	5	3

Otoscopic examination :

Right Ear.—Marked retraction of membrana tympani ; light reflex limited to the region of the umbo ; marked peripheral injection of the drum-membrane and of the malleolar plexus.

Left Ear.—Same as right, with the exception of the peripheral injection. C and G could not be heard at the recorded distance at which he heard the whisper (32 feet). On September 11, 1897, an examination was made outside the caisson under normal conditions.

Right Ear.—Watch, 16″ ; whisper, 32′ ; speech, 42′ ; acoumeter, 40′ ; Galton's whistle, 1.7 ; lower-tone limit, 16 ; Weber's test, negative.

Reaction to tuning-forks :

	C	c	c^{i}	c^{ii}	c^{iii}	c^{iv}
Rinné :	a. c.	a. c.	a. c.	a. c.	a. c.	a. c.
Schwabach :	34	21	24	20	34¼	25
	11	11½	7	5	7½	10

Left Ear.—Watch, 18″ ; whisper, 32′ ; speech, 40′ ; acoumeter, 28′ ; Galton's whistle, 1.8 ; lower-tone limit, 16.

Reaction to tuning-forks :

	C	c	c^{i}	c^{ii}	c^{iii}	c^{iv}
Rinné :	a. c.	a. c.	a. c.	a. c.	a. c.	a. c.
Schwabach :	28	22	29	21	28½	21½
	8	15	10	8	8½	7

Otoscopic examination :

Both drum-membranes slightly retracted ; light reflex small and central ; drum-membrane otherwise normal.

Case 8.—Physician, age 43, general condition good, but of a nervous temperament. An examination made on August 29, 1897, revealed the following facts :

Right Ear.—Watch, light pressure ; whisper, 16′ ; speech, 8′ ; acoumeter, 0 ; Galton's whistle, 1.9 ; lower-tone limit, 512 ; Weber, +.

Reaction to tuning-forks:

	C	c	c^{i}	c^{ii}	c^{iii}	c^{iv}
Rinné:	b. c.	b. c.	b. c.	b. c.	b. c.	a. c.
Schwabach:	0	0	0	7	7	8
	14	16	11	11	9	8

Left Ear.—Watch, contact; whisper, 24′; speech, 29′; acoumeter, 12′; Galton's whistle, 2.2; lower-tone limit, 64.

Reaction to tuning-forks:

	C	c	c^{i}	c^{ii}	c^{iii}	c^{iv}
Rinné:	b. c.	a. c.	a. c.	a. c.	a. c.	a. c.
Schwabach:	21	21	25	23	29	16
	18	15	10	10	13	10

Otoscopic examination:

Right Ear.—Very marked retraction of drum-membrane; drum-membrane dull; no light reflex; scar tissue marked; movement of drum and malleus limited; short process prominent, and long process foreshortened; ossicles firmly bound together and mucous membrane apparently thickened.

Left Ear.—Incipient changes of a similar character are beginning to take place in this ear.

For purposes of further study and analysis, we have summarized that portion of the foregoing records which has a direct relation to the functional examination.

We were, unfortunately, unable to obtain corresponding or duplicate tests in two of our cases, one having been examined in the caisson only, and the other being unable, from causes already mentioned in another portion of this article, to enter the caisson for further investigation. The averages obtained from the functional examinations are presented in tabular form, from which deductions will be drawn later on.

Right Ear.—Average for air-conduction before entering the caisson:

C	c	c^{i}	c^{ii}	c^{iii}	c^{iv}
$31\frac{6}{7}$	$18\frac{5}{7}$	$19\frac{6}{7}$	$22\frac{8}{7}$	$4\frac{13}{14}$	$15\frac{1}{2}$

Averages for bone-conduction before entering the caisson:

C	c	c^{i}	c^{ii}	c^{iii}	c^{iv}
$10\frac{1}{14}$	$12\frac{1}{14}$	$9\frac{1}{7}$	$7\frac{5}{7}$	$8\frac{13}{14}$	$6\frac{5}{7}$

Left Ear.—Averages for air-conduction before entering the caisson:

C	c	c^{i}	c^{ii}	c^{iii}	c^{iv}
34	$20\frac{1}{7}$	$20\frac{1}{14}$	$22\frac{5}{7}$	$25\frac{9}{28}$	$17\frac{1}{14}$

Averages for bone-conduction before entering the caisson:

C	c	c^{i}	c^{ii}	c^{iii}	c^{iv}
$13\frac{3}{7}$	$11\frac{1}{14}$	$9\frac{2}{7}$	$7\frac{1}{7}$	$7\frac{7}{14}$	$6\frac{4}{7}$

Right Ear.—Averages for air-conduction after entering the caisson:

C	c	c^{i}	c^{ii}	c^{iii}	c^{iv}
$21\frac{1}{7}$	$14\frac{4}{7}$	12	$13\frac{3}{4}$	$13\frac{5}{14}$	$6\frac{6}{7}$

Averages for bone-conduction after entering the caisson:

C	c	c^{i}	c^{ii}	c^{iii}	c^{iv}
$11\frac{2}{7}$	$7\frac{2}{7}$	$6\frac{2}{7}$	$2\frac{6}{7}$	$3\frac{11}{14}$	3

Left Ear.—Averages for air-conduction after entering the caisson:

C	c	c^{i}	c^{ii}	c^{iii}	c^{iv}
$22\frac{3}{7}$	14	$14\frac{5}{14}$	$12\frac{4}{7}$	$11\frac{4}{7}$	$7\frac{4}{7}$

Averages for bone-conduction after entering the caisson:

C	c	c^{i}	c^{ii}	c^{iii}	c^{iv}
$9\frac{3}{7}$	$7\frac{2}{7}$	$5\frac{3}{7}$	$3\frac{11}{14}$	$3\frac{5}{14}$	2

Watch:

Right Ear.—$38\frac{3}{7}''$. Average before entering caisson.
" " $7\frac{4}{7}''$. Average after entering caisson.
Left Ear.—$41\frac{5}{7}''$. Average before entering caisson.
" " $2\frac{4}{7}''$. Average after entering caisson.

Whisper:

Right Ear.—$37\frac{2}{7}'$. Average before entering caisson.
" " $30'$. Average after entering caisson.
Left Ear.—$36\frac{2}{7}'$. Average before entering caisson.
" " $26\frac{2}{7}'$. Average after entering caisson.

Speech:

Right Ear.—$36\frac{1}{7}'$. Average before entering caisson.
" " $31'$. Average after entering caisson.
Left Ear.—$39\frac{1}{7}'$. Average before entering caisson.
" " $32'$. Average after entering caisson.

The average for the *lower-tone limit*, both in and out of the caisson, was 16 D. V., except in Case 8; in this case the lower-tone limit was 512. D. V.

Politzer's Acoumeter:

Right Ear.—34′ Average before entering caisson.
" " 17⅞′. Average after entering caisson.
Left Ear.—32′. Average before entering caisson.
" " 27¼′. Average after entering caisson.

Galton's Whistle:

Right Ear.—1.928. Average before entering caisson.
" " 1.585. Average after entering caisson.
Left Ear.—1.871. Average before entering caisson.
" " 1.514. Average after entering caisson.

Weber's test presented no lateralization; the fork, c^1, with one exception, being heard equally well in both ears.

From the facts obtained and from observations which we have been able to make, the following conclusions may be formulated:

That for aërial and bone-conduction the reaction of the tuning-forks is markedly diminished, this being especially true of the higher notes.

That bone-conduction is affected to a greater degree than aërial conduction.

That this is probably due to a hyperæsthesia of the labyrinth or some analagous disturbance, the effects of which are more pronounced on the lower portion of the cochlea.

That the hearing power both for aërial and bone-conduction is reduced directly in proportion to the atmospheric pressure.

That the lower-tone limit was unaffected, being 16 D. V. in all the cases, both before and after entering the caisson.

That there was no lateralization in Weber's test, it being negative in all the cases before and after entering the caisson.

That the hearing distance for both the whisper and speech was markedly decreased in the caisson.

That certain vowel and consonant sounds are heard with difficulty, or not at all. For example: In one case the letters P and G were not heard at all; in another, C and G

were not heard; another case failed to hear G and L, and still another failed to hear A and B.

That the hearing distance for the watch decreased in all cases in the ratio of nearly one to twenty (1–20).

That the effects of the aforesaid labyrinthine disturbances persist for varying intervals—from twenty-four to forty-eight hours—in persons not accustomed to the action of compressed air.

That a pressure of one half an atmosphere is sufficient to cause depression of the drum-membrane.

That a pressure of two atmospheres causes marked disturbance of the drum-membrane, accompanied with congestion of the malleolar plexus and of the membrana flaccida.

That in some cases this depression is sufficient to cause displacement of the ossicular chain and persistent tinnitus.

That in descending into the caisson—while in the "lock"—there is great danger of the drum-membrane being ruptured, if care is not taken to perform Valsalva's experiment.

That persons suffering with coryza, a slight cold, or congestion of the naso-pharyngeal mucous-membrane from any cause, must not attempt to enter the caisson.

That this has been found to be equally true of persons who have been accustomed to entering and re-entering the caisson for years.

That persons affected with chronic ear disease, especially the sclerosing types, must likewise avoid entering the caisson.

That those affected with labyrinthine disease, especially if the semicircular canals are involved, should be cautioned not to enter the caisson, owing to the great danger of vertiginous symptoms occurring while in the "lock."

That the effect on the heart and general circulation is such as to render it dangerous for those with a weakened or diseased circulatory apparatus to enter the "lock" or caisson.

That the action of the heart is accelerated, the radial pulse being increased from seventy, or thereabouts, to one hundred and twenty beats a minute.

That persons of a hyperæsthetic or neurotic temperament should avoid entering the caisson.

That the compressed air offers sufficient resistance to prevent whistling, especially the high notes.

That the atmosphere of the caisson, although generally humid, causes extreme dryness of the fauces and all exposed mucous surfaces.

A CASE OF INTERNAL EAR DEAFNESS FOLLOWING MUMPS TREATED WITH PILOCARPINE—RECOVERY.

By F. W. JOLLYE, F.R.C.S., D.P.H.

THIS case seems worthy of record owing to the comparative rareness of nerve deafness following mumps, and especially from the fact of a perfect cure following the subcutaneous injection of pilocarpine when a previous treatment with other remedies for five weeks had in no wise ameliorated the symptoms.

On January 28, 1896, a little girl aged 13½ years, who with the rest of the family was just convalescent from mumps, fell down, after getting out of bed in the morning, and was quite unable to rise by herself, owing to severe giddiness. On seeing her soon afterwards I found her in bed, complaining of a diffuse pain over the right side of the head and of giddiness on sitting up. She had no feeling of nausea and did not complain of earache or deafness, but on getting her out of bed I found that she had to be held up to prevent her falling; there seemed to be no tendency to fall in any one direction. The pupils were equal and reacted to light, and she had perfect use of her limbs. The prominent symptom of vertigo made me test her hearing with my watch, and I found that there was inability to hear the watch in the right ear when it was put anywhere on her skull, or when she held it between her teeth. The tuning-fork was not heard by aërial or bone-conduction. There were no signs of mischief observable in the middle ear by the use of the speculum. She had never had any previous ear trouble. For the next few days she had hot fomentations and counter-irritation behind the ear, and was given a bromide and antipyrin mixture and

kept quiet in bed; she also had a calomel purge at the commencement and her ear was inflated by means of Politzer's bag. During the next few weeks her giddiness improved very slightly, as also did the pain, and from being at first continuous became more paroxysmal in character and often came on in the night and prevented her sleeping. The deafness remained, however, absolute on the right side, and so I determined to try the subcutaneous injection of pilocarpine. On March 2, 1896, I commenced these injections, following the advice given by Mr. Field in his book on *Diseases of the Ear* as to beginning with small doses, covering the head of the patient over with a shawl to prevent catching cold, and giving some stimulant at the time. The first dose was $\frac{1}{24}$ gr., the second $\frac{1}{12}$, and the dose was gradually increased daily until on the 14th she was having gr. $\frac{1}{8}$ of nitrate of pilocarpine. This dose was continued every day for about another week, when the patient first stated that she could hear the watch when pressed upon the mastoid, and she could now stand alone, but was afraid to walk. I then gave her a mixture of sulph. of quinine gr. $\frac{1}{8}$ with nitrate of pilocarpine gr. $\frac{1}{4}$, to be taken three times a day, intending to go back to the injection if the symptoms did not continue to improve. She took this mixture for a fortnight without any bad symptoms and with a distinct improvement in her hearing, and I then left off the pilocarpine and continued the quinine for another six weeks. At the end of this time she could hear my watch two or three inches away from the ear, and her giddiness was so much better that she could walk around the room, provided she could keep near some article of furniture to put the hand on in case of need; but it was well into the summer before she had enough confidence in her walking powers to go out alone. I examined her in September, 1897, and found that the hearing on both sides was perfect.

The disease in this case, as in the majority following mumps, was unilateral, and there seems to be no relation between the severity of the mumps and the liability to ear mischief, for the patient had a very mild attack and was not ill enough to be kept in bed or to have medical treatment, and all swelling had disappeared for several days before the vertigo set in.

I inflated the middle ear during the treatment, owing to my belief that perhaps the mischief in the internal ear might

be secondary to some catarrh or congestion of the middle ear. The slight rise of pulse and temperature might have been due to the pain the child suffered, which, curiously, was not referred to the ear at all but to the whole side of the head, emphasizing the fact that the state of the ear should always be examined into in all cases of obscure head symptoms, especially in children.

A CASE OF BEZOLD MASTOIDITIS WITH EXTENSION TO THE POSTERIOR PART OF THE NECK.

By Dr. J. GUTTMAN,

ASSISTANT SURGEON OF THE N. Y. OPHTHALMIC AND AURAL INSTITUTE.

THIS type of mastoiditis, where the pus in the morbid mastoid process has the tendency to break through the lower-inner table of the mastoid process, and then to form a deep subfascial abscess in the retro-maxillary fossa, was first authoritatively described, eighteen years ago, by Bezold. As examples of this kind of mastoiditis recorded in literature are not numerous, I think it not superfluous to add the history of a typical case to their number.

Mr. E. Sch. was seen by me for the first time on January 15, 1896. According to his statement his left ear had, with only short intermissions, been. discharging for the last eight years. Three weeks ago he had caught a severe cold, and since then his otorrhœa had been more profuse. A swelling, extending along the side of the neck, developed behind his left ear. At present he suffers from a severe pain in the left side of his head, especially in the occiput.

Present Condition.—The patient, who is twenty-one years old, has a healthy, robust constitution. Pulse 90, temperature 100°. The nose and throat show a stage of chronic hypertrophy, which is especially marked in the lower turbinated bodies of both sides. The auricle is pushed forward. The skin over the mastoid process, particularly in the lower part, is red and swollen. This swelling continues downward, fills out the retro-maxillary fossa, and spreads in the direction of the sterno-cleido-mastoid muscle to a distance of about 2″ from the tip of the mastoid process. Fluctuation is not quite distinct. By examination with the ear-

speculum the auditory canal proved to be quite normal, the tympanic membrane was deficient in its greater part, and there was a purulent discharge from the middle ear. After the pus had been washed out, the mucous-membrane of the middle ear appeared red and swollen, and covered with small granulations. The posterior and upper wall of the canal did not bulge. The mastoid process was quite painful on pressure. Hearing power of the right ear normal, of the left about $\frac{18}{20}$ for the watch. I ordered cleansing of the ear, and advised an operation. As the swelling and the pain in his head did not subside in the following four days, the patient came to the N. Y. Ophthalmic and Aural Institute, and consented to an operation.

I made the usual incision behind the upper wall of the auditory canal to the tip of the mastoid process, with the intention of first entering the antrum. After the slight bleeding had been checked the bone was laid bare. It showed a white and quite healthy appearance. By chiselling off the upper layers of the bone, I found it to be of a hard, ivory-like structure. After I had chiselled a hole about 15 *mm* deep I reached the antrum, which was very small and filled with granulations; but no pus was present. I then chiselled a canal to the tip of the mastoid process. The tissue here was much softer and the cells were larger. After chiselling away the lower-inner wall, pus appeared, especially by pressure upon the abscess below. By probing this sinus the abscess showed a length of 4 *cm* downward and 2.5 *cm* backward towards the cervical vertebræ, deep under the muscles of the nape of the neck. By inserting a director I opened the abscess downward and backward, then inserted a drain, and packed the whole wound. On the third day the bandage was removed. There was no fever, the headache had ceased, and the patient felt much improved. The healing of the wound proceeded without any disturbance, so that two weeks after the operation the patient was discharged from the hospital. Three days after the discharge of the patient I was suddenly called to his house, and found him suffering from intense pain in his right hand, with fever of 103°. The day after his right hand began to swell, and a deep phlegmon on his right hand developed. This was promptly operated upon. As the patient had kept his room ever since his discharge from the hospital, and had had no occasion to wound his hand, it is quite difficult to find the cause of this phlegmon. The patient, of course, attributed it to the wound behind his left ear, and

blamed the surgeon. The discharge of his ear had entirely ceased, and his hearing power had been restored to the normal standard.

When we analyze the course which this affection took, it is probably as follows: The frequent attacks of naso-pharyngeal inflammation led, through the Eustachian tube, to a chronic purulent middle-ear catarrh. This affected the antrum. By the repeated inflammation of the latter the outer layers of the bone became sclerosed, ivory-like. When, as a product of the inflammation, pus formed in the antrum, it could not break through the hard, ivory-like outer layers, and therefore took the course of least resistance, *i. e.*, through the rarefied tissue in the tip of the mastoid process, broke through the inner wall, and burrowed in a sinus beneath the deep fascia colli, forming the abscess of the neck. This abscess may descend sometimes beneath the muscles of the neck and form a mediastinal abscess, or it may, as in many cases recorded in literature, of which one, described by Knapp,[1] is a remarkable example, break through the inner wall of the mastoid process, and produce thrombosis, brain abscess, and meningitis.

In the above article Dr. Knapp says: "This form (Bezold) is distinguished by a tendency to seek an outlet for its inflammatory products along the inner table of the bone at different places. (*a*) Perforating it on the medial side of the tip and extending down the neck alongside the sterno-cleido-mastoid muscle. (*b*) Perforating the posterior wall of the ear canal, and discharging its products through a fistula in the canal, or through the tympanum. (*c*) Perforating the cranial cavity, producing extradural suppuration, sinus thrombosis, and cerebral and cerebellar abscess. I have seen examples of each variety of this form of mastoiditis, to which of late so much attention had been paid."

As we see what dimensions this kind of mastoiditis may take, I believe it our duty to perform, in these cases, a typical mastoid operation, and not merely to open the abscess of the soft parts and leave the bone untouched.

---

[1] ARCHIVES OF OTOLOGY, 1892, p. 239.

A CONTRIBUTION TO THE SYMPTOMATOLOGY AND TREATMENT OF PYÆMIC SINUS THROMBOSIS, BASED UPON THREE SUCCESSFULLY OPERATED CASES.[1]

By FRED. WHITING, M.D.,

AURAL SURGEON TO THE NEW YORK EYE AND EAR INFIRMARY.

THE increasing attention which during the past few years the study of intercranial complications of ear diseases has received at the hands of surgeons generally, and of aural surgeons as well, is partly responsible for noteworthy advances which have been made in the diagnosis and treatment of such lesions; the gratifying progress already achieved is, however, mainly attributable to several other causes, chief among which must be accounted modern views and improved knowledge concerning the nature of suppurative inflammations and the institution of that surgical renaissance, antisepsis; increased precision in cerebral localization has afforded additional impetus to the work, and these combined factors have contributed to numerous brilliant surgical successes.

The dangers of purulent ear disease have been clearly enunciated by bacteriologists, while the introduction of antisepsis has emboldened surgeons to perform operations upon the cranium and its contents which would not formerly have been contemplated.

The day is past when intelligent people can be lulled into false security in the belief that a discharging ear means nothing and that the child will grow out of it. They are

[1] Read in part before the Ophthalmological and Otological Section of the N. Y. Academy of Medicine, Jan. 17, 1898.

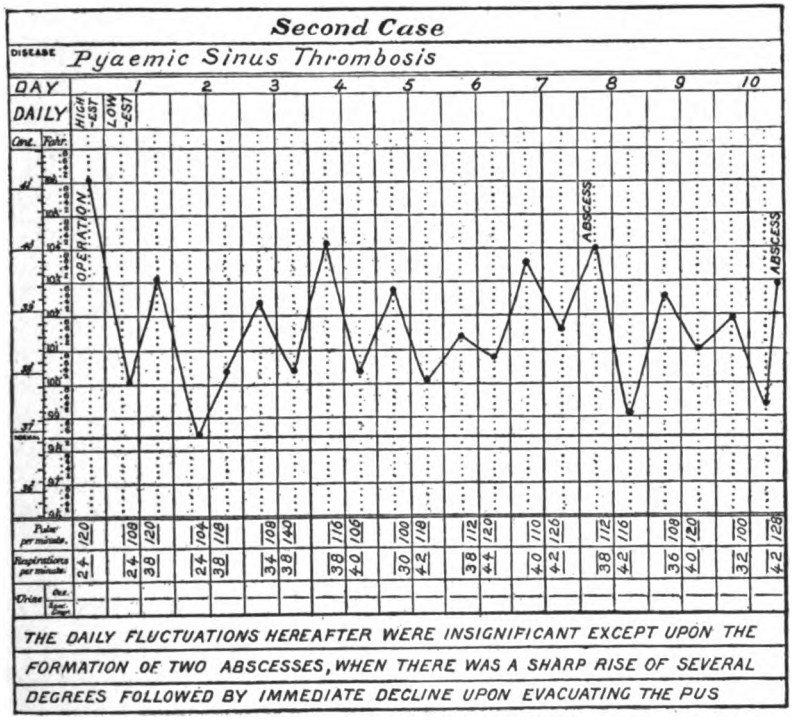

THE DAILY FLUCTUATIONS HEREAFTER WERE INSIGNIFICANT EXCEPT UPON THE FORMATION OF TWO ABSCESSES, WHEN THERE WAS A SHARP RISE OF SEVERAL DEGREES FOLLOWED BY IMMEDIATE DECLINE UPON EVACUATING THE PUS

learning to appreciate it as a dangerous condition, while the medical fraternity recognizes chronic suppuration of the middle ear as responsible for by far the greatest number of intracranial inflammations.

According to the most reliable statistics, about one quarter of all cases receiving treatment at the hands of the otologist are chronic suppurative diseases of the middle ear, and it is from this numerically large class that the ranks of victims to secondary intracranial disease are recruited; acute inflammations of the ear being almost exclusively free of such sequelæ, which, indeed, appear to result "from a recrudescence of a long-standing latent focus of infection aroused to renewed activity by some fresh irritation whether of a traumatic or zymotic character" (Gruber).

The observations of Zaufal demonstrating the constant presence of certain micro-organisms in otitic discharges and also in the intracranial diseases following upon their dissemination have been amply confirmed; as also the painstaking researches of Rohrer indicating that a notable distinction exists in the bacteria found in offensive and non-offensive discharges. In the fœtid secretions micrococci and bacilli were always associated, while in the non-fœtid only micrococci were present; he determined by culture and inoculation that the bacilli present in foul discharges were not pathogenic but possessed saprophytic properties only; while inoculation with the micrococci produced speedily fatal sepsis. "It is thus evident that the offensiveness of a discharge from the ear is no criterion of the dangers to be apprehended from it" (Gruber).

The relative infrequency with which acute purulent ear diseases are followed by secondary infective lesions indicates that the healthy muco-periosteum offers a strong defense against the inroads of bacterial products and but slight absorption takes place, the micro-organisms themselves being destroyed by the phagocytic action of the leucocytes. With the establishment, however, of a chronic suppurative process the resistance of the tissues is greatly impaired; there is partial destruction of the lining membrane of the tympanum and accessory cavities, with probable superficial caries

of the underlying bone; the nutrient blood-vessels and lymph-channels are thus exposed to invasion of the septic products reposing in these spaces, which in this manner gain access to the circulation and may be deposited locally or disseminated over the body.

The conditions favorable to the production of acute infective processes in patients suffering with chronic otorrhea are very obscure, but there are certain facts which appear relevant thereto and worthy of consideration: Monti has shown experimentally that the injection of attenuated cultures of staphylococci which were quite harmless, produced rapidly fatal sepsis when accompanied by simultaneous injection of non-pathogenic germs. It seems probable that the products of infective inflammation in an ear which is the seat of chronic suppuration may lie for a long time dormant until they are aroused to renewed pernicious activity by the introduction of some micro-organism, pathogenic or otherwise, which supplies the appropriate fuel to revive the smouldering septic fires and precipitate either a general systemic involvement or a localized intercranial affection. The precise reason why in one case the rekindled septic focus expends its violence in local invasion and in the next instance produces pyæmia does not readily appear; there seems, however, reasonable ground for the probability that the intensity of infection is the basis; which is to say that when the germs are present in great abundance there is increased liability to pyæmia with metastases, and when the germs are less numerous or virulent a local purulent inflammation results, as for example extradural abscess or sinus thrombosis.

Infective intracranial diseases possess for the surgeon an irresistible fascination in whatsoever form they may be observed, whether as meningitis, sinus thrombosis, or brain abscess, but so comprehensive are those questions in their general bearing and in detail that even a casual consideration of them would entirely transcend the intent and scope of this paper; it will therefore be my privilege to endeavor to present the salient pathological and diagnostic features of one of the most interesting as well as most fatal of intracranial lesions, namely, sinus thrombosis.

Before, however, proceeding to a consideration of its clinical features, it may perhaps not be inopportune to allude briefly to a few historic facts of interest as bearing upon our present attitude toward the subject.

In his treatise upon *Diseases of the Brain*, Abercrombie was among the earliest to call attention to thrombosis of the lateral sinus as recognized by him early in the present century (1829), but Lebert (*Virch. Archiv*, vol. ix., 1856) was the first to recognize in the living subject a purulent inflammation of the sinus and jugular with consecutive pyæmia and metastatic abscesses. The observations of Von Dusch (1859) mark the first real advance toward an intelligent comprehension of the disease as we understand it to-day, although like his predecessors and contemporaries he was etiologically and pathologically in the dark. Molthan in his dissertation in 1862 suggested that the cause of sinus thrombosis was phlebitis of the small veins of the ear, which extended into the sinus and involved it, or else that the sinus became inflamed from a collection of pus lying between the dura and the diseased bone; these were marvellously astute observations and mark the beginning of our accurate knowledge of the pathology of the affection. Contributions by Sentex, Brouardel, Moos, and many others follow in the literature until 1868, in which year Knapp, who was the first to clearly recognize it, reported three cases of cavernous sinus thrombosis (*Arch. für Ophth.*, 1868, vol. xiv., p. 220), since which time otological and ophthalmological journals abound in reports of thrombosis of all the large sinuses; the most notable publications of recent years are those of Körner, Macewen, Hessler, Forselles, and Broca and Maubrac. These works are encyclopædic in form and exhaustive in contents, and Hessler's (*Otogene Pyämie*) contains an historical epitome of the subject under discussion, at the same time most interesting and instructive.

The recommendation of Zaufal and Horsley, that pyæmic sinus thrombosis was a disease amenable to surgical treatment, established a new Mecca for surgery, and Lane, Balance, Forselles, Macewen, Schwartze, and others, following in the footsteps of these two mentors, treated the medical

fraternity to a series of startling operative triumphs. The splendid work of these surgeons brings us to the present consideration of the subject; when our knowledge of the etiology and pathology is cause for congratulation, while the field of symptomatology still leaves much to be desired. With the increasing number of zealous observers at home, emulous of rivalling the enviable records made abroad, an immense impetus is afforded to observations and researches, which is bound to be fruitful and which will infallibly result in the collection of much useful and superfluous material, which the touch of some master hand shall convert from a disorderly array of facts into a concrete skeleton upon which time and experience will construct a nearly perfect symptomatic organization.

Thromboses of the sinuses of the dura mater are of two distinct varieties, viz., primary or marasmic, and secondary or infective; it is with infective thrombosis that we concern ourselves on this occasion, and direct our consideration to its appearance in the sigmoid and cavernous sinuses, these two being in the relative order of frequency the most and least commonly affected of the large intracranial sinuses. We shall, however, devote our attention for the most part to the sigmoid, since this is not only the most frequently involved, but is also the one which, from its anatomical relation to the temporal bone and the middle ear, possesses for the otologist the chief clinical interest.

The etiology of infective sigmoid sinus thrombosis is, thanks to bacteriologists, well understood; it is always secondary to some infective inflammation, and is dependent upon the introduction into the sinus of septic micro-organisms, which originate somewhere in the immediate vicinity; it may, therefore, be termed a local disease. It has been noted as the result of wounds about the head which became infected; also as a complication of malignant growths of the temporal bone; but in the vast majority of cases is due to the presence of chronic suppurative disease of the middle ear. This is easy of comprehension when we recall that the investigations of Moos, Zaufal, and others have clearly demonstrated that any micro-organisms which will cause sup-

puration in the ear can also infect the contents of the skull, and, should their dissemination over the body take place, are almost certainly productive of pyæmia.

Of the pathogenic germs most commonly found in purulent inflammation of the middle ear, three varieties may be regarded as constant: streptococcus, staphylococcus, and pneumococcus. These are likewise encountered in varying proportions in all infective intracranial diseases, sometimes one and again another predominating; but whether any of them possess a selective affinity for any intracranial tissue as a medium for proliferation, is an interesting but at present purely speculative hypothesis. So far as we know, any one of these varieties exercises equally virulent pathogenic activity, whether it be introduced into the sinus or into the substance of the brain.

The path of infection in septic brain diseases is most commonly the direct one of immediate extension from diseased bone lying in contact with the contents of the skull. Körner found in 109 autopsies of otitic brain disease that caries, extended entirely through the inner table of the skull, was present in 86, but not through the inner table in 8, and the bone was healthy in 15 cases. The infection in those cases where the bone was healthy took place through fissures in the roof of the tympanum or antrum, or through disease of small veins of the bone, which empty into the sinuses. This last is a very frequent route for the introduction of infective matter; small veins in the tympanum become inflamed and thrombosed, and the clot extends gradually until the lumen of the sinus is reached and its contiguous wall becomes involved in the phlebitic process. By far the most frequent cause is, however, immediate contact with the diseased bone.

The *pathology* of suppurative phlebitis, which is what we encounter in a case of sinus thrombosis with disintegration of the clot, is a most interesting study, and equally attractive is a consideration of the conditions under which in sinus thrombosis the clot, instead of undergoing purulent liquefaction, becomes the seat of reparative inflammation, and a constructive process ensues.

The inflammatory changes which precede the formation of the complete or obliterating clot in infective phlebitis are identical in those cases which result in organization, with those which result in disintegration ; but after the thrombus is once fully formed, the succeeding steps diverge widely and are as gratifying in the benign result which accompanies organization as they are frequent and distressing in the fatalities which supervene upon disintegration.

When a sinus is attacked with infective phlebitis, its endothelial cells first become swollen, then softened, and then begin to desquamate, at which stage the fibrin in the blood current is deposited together with red blood cells and leucocytes about the eroded area of the vessel wall. This process may be limited to one portion of the wall of the sinus, in which case a parietal clot forms; but if, as more frequently happens in infective conditions, the whole circumference of the vessel participates in the change, a complete or obstructing thrombus is produced. The attempt of pathologists to subdivide such thrombi into red, white, and mixed varieties seems like a needless multiplication of vexatious and confusing distinctions.

At this stage of the inflammation the activity of the pathogenic germs either wanes and the clot becomes organized, or their virulence waxes and purulent disintegration begins. In the event of organization of the thrombus, the steps are analogous to reparative inflammations elsewhere in the body, and are accomplished briefly as follows:

The endothelial cells of the nutrient vessels, and the connective-tissue cells in their walls, proliferate and extend themselves in delicate fibrils or trabeculæ of simple protoplasm and anastomose with similar sprouts from other vessels. These branches are at first solid twigs of protoplasm without any lumen, but with progress of time the pressure of the current in the vessel from whose wall they spring gradually forces itself along them, and they become the simplest form of blood-channels. Along their walls fibrous tissue cells arrange themselves, and these new inflammatory vessels extend into the substance of the thrombus and gradually penetrate the clot, and replace step by

step with new connective tissue the fibrin and blood which originally constituted it; in this manner organization of the clot is accomplished.

The clot having formed, infection, however, rarely stops short of disintegration and purulent liquefaction; oftentimes the deeper structures of the vessel wall are implicated in the process, and ulceration has been known to occur, but almost never with hemorrhage, because the thrombus adhering above and below the point of solution in the wall is able to withstand the blood pressure. The liquefied clot mixes with pus which comes from the walls of the vasa-vasorum and forms a thin dark fluid sometimes with and again without odor and swarming with pyogenic germs; these multiply rapidly and are the cause of general systemic infection if they gain admission into the circulation, which they commonly do in one of the following ways:

First, and most frequently, by the entrance into the small tributary vessels of minute particles of infective matter which are in this wise introduced into the general circulation and disseminated over the body; this occurs the more readily because the intracranial veins are without valves and the thrombosis may cause a reversal of the direction of the current.

Second, the disintegration of the clot may be sufficiently extensive to cause a partial restoration of the lumen of the vessel, and the current be re-established either through the centre of the thrombus or between it and the vessel wall, in which manner portions of the septic material are swept into the circulation and deposited, it may be, in the lungs, the brain, the kidneys, or the intestines, where they result in metastatic abscesses characteristic of pyæmia.

There is great likelihood that general infection may also take place by lymphatic absorption of the pyogenic organisms which penetrate the walls of the thrombosed veins or sinuses and infiltrate the contiguous tissues; these infiltrated areas, instead of becoming organized and converted into new connective tissue, as a rule undergo the same disintegration as the thrombus itself and become additional foci for the dissemination of infection.

The precise rôle played by the lymphatics in the distribu-

tion of microbial products in infective inflammation has not been accurately determined. That bacteria of many kinds have been found in the lymph-channels, is well known. Among those most frequently encountered are streptococci, and less commonly staphylococci; the agency of the former in establishing general infection and metastases has long been recognized, although no distinct enunciation of this fact is to be found in connection with sinus thrombosis.

In certain cases of this affection, when the disintegrated clot extends so that the jugular bulb is implicated, there can be felt a firm circumscribed induration, occasionally with recognizable swelling and as often without, lying immediately under the angle of the jaw and deep in, with no infiltration and but little tenderness of the neck below. The speedy disintegration of this mass is to be anticipated with the infection of the adjoining tissues; swarms of bacteria are thus liberated and find their way into the lymph spaces, which, it is only reasonable to infer, promote their dissemination.

In like manner, when the visceral wall of the sinus is involved the infective products penetrate into the posterior fossa of the skull, and the cerebrum and cerebellum are attacked, resulting in abscess or lepto-meningitis, or both; the jugular and condylar veins as well as the superior and inferior petrosal sinuses are prone to participate in any inflammatory condition of the sigmoid sinus, their implication adding to the gravity of a prognosis already none too favorable.

Although far from exhausting the pathology of this subject, which Macewen in his matchless work has invested with such charm for all students, it is necessary to pass to a consideration of the symptomatology of the affection.

The diagnosis of sinus phlebitis is seldom easy, often exceedingly difficult, and occasionally (particularly in the case of the smaller sinuses) impossible, for the reason that there are no pathognomonic symptoms, even that most constant of all premonitory septic manifestations, the chill, being occasionally conspicuous by its absence, the infective invasion being heralded in such instances by a rapid elevation of temperature only.

Symptoms of sinus thrombosis may be best considered in,

first their local, secondly their general or systemic manifestations.

The local symptoms are few, obscure, and indeterminate. The most constant is, of course, *pain*, usually radiating from the ear over the corresponding side of the head, varying in intensity from dull aching to violent cephalalgia of unendurable severity. Associated with this pain there is often *œdema* of the mastoid region, extending backward and upward over the site of exit of the mastoid vein, and downward to that portion of the scalp drained by the occipital vein. When this manifestation of circulatory embarrassment is present, there is usually distinct tenderness, and in some instances, notably the first case to be reported to-night, exquisite sensitiveness, over the same area. Another manifestation that has been occasionally remarked as an evidence of obstructed circulation (most recently by Stirling in his paper, *Canada Med. Record*, Nov., 1896) is moderate œdema or puffiness of the eyelids of the corresponding side as a result of interference with the cavernous sinus and engorgement of the ophthalmic vein.

Gerhardt has claimed that pressure over the external jugularis would show that there was a decided increase in the amount of blood passing through the vein of the unaffected side, but his observation has until now never been verified, at least so Hessler affirms, but the second case described in the paper furnishes an excellent demonstration of the symptoms and will be dwelt upon later. The tenderness in the upper portion of the posterior cervical triangle, upon the importance of which *Griesinger* insists, is as often absent as present, but when it exists, is a valuable aid in estimating upon the probable position and extent of the obstructing thrombus. The deeper down toward the bulb that the clot extends and the more marked the disintegration, the greater the constancy of Griesinger's symptom, which depends upon phlebitis of the deep veins of the neck, the anterior and posterior condylar participating with considerable frequency in the inflammatory extension from the sinus.

Intra-ocular inflammatory changes are observed in a considerable number of cases, and usually take the form of

neuro-retinitis, although in a few instances where there has been extension of a non-infective clot into the cavernous sinus certain muscular paralyses have manifested themselves as the result of pressure; the pallid and anxious countenance, the perspiratory suffusion of the face and brow, are in no wise distinctive of this especial lesion, but are equally common attributes of allied intracranial infective diseases when the toxæmia is pronounced.

The general or systemic symptoms of sinus thrombosis are essentially those of septico-pyæmia, and the manifestations are the results of the dissemination through the blood- and lymph-channels of the pathogenic micro-organisms. The path of infection and the method of dissemination have been already discussed.

An attack of sigmoid sinus phlebitis is usually ushered in by *pain* in the affected side of the head, a feeling of malaise and nausea preceded or followed by a sharp chill and a sudden and pronounced rise in temperature, 106° F. being frequently recorded. This marked pyrexia is subject to frequent remissions, and the amplitude of the exacerbation is at times very great, although the febrile period may be exceedingly brief, two hours sufficing in numerous instances for a variation of 6° F. This *very high temperature* is significant of the degree of toxæmia present in the case, and is a valuable guide to, or one might say warning of, the septic complications to be anticipated. With such fever there could be prophesied, with almost absolute certainty of its fulfilment, multiple metastases and a succession of unfavorable developments. Of 95 cases of metastatic sinus thrombosis recorded by Hessler, but 12 exhibited temperatures of 106° F.; and of 26 cases which were *free of metastases*, not one approached this degree. Important clinical deductions may with reason be made from such a statistical array, which begets in the operator confidence and enables him to offer his prognosis with less hesitation and greater intelligence.

Equally important inferentially is the appearance of *rigors*, which constitute a prominent feature at all stages of sinus thrombosis. They occur early, are frequently repeated, and as the toxæmia increases may even become daily manifestations,

accompanied by profuse perspiration. While it is true that chills are the most constant symptom of the onset of infective phlebitis, it is also true that they may be entirely wanting, and 16 such cases are recorded, also 40 in which but a single chill was experienced, as against 200 in which the rigors were frequent. Repeated chills may therefore be anticipated in $\frac{4}{5}$ of the cases, and further investigation shows that the metastatic processes in those instances in which the rigor was not repeated were numerically small, with feeble septic powers. On the other hand, when the chills were frequent and prolonged the subsequent sweating was pronounced and debilitating and the associated septic processes proportionally virulent. Allen has reported a case in which with repeated chills there was no sweating until during the few hours immediately preceding death. These exceptions to the usual rule in the sequence of symptoms serve chiefly to emphasize their fallibility for purposes of diagnosis. *Vertigo* is present in a moderate proportion of cases which are uncomplicated, and, like vomiting, is more constant when associated with meningitis. Forselles found it present in simple sinus phlebitis uncomplicated, in 13 %; present in simple sinus phlebitis with meningitis, in 30 %. As a symptom of sinus thrombosis, it is by no means a distinguishing characteristic, and the importance attributed to it should not be over-estimated. As an accompaniment of acute infective conditions, it makes its appearance suddenly, and is apt to diminish as the disease progresses, and then to recur with later unfavorable manifestations; at some times present only on assuming the erect posture, at others asserting itself even during recumbency.

The *pulse* and *respiration* in the first week show a moderate acceleration, becoming exaggerated with the passage of time and increasing toxæmia, until in fatal cases of pyæmic thrombosis the pulse rate mounts to 180 or becomes so rapid and feeble as to defy computation, the breathing being also embarrassed, and the respirations occurring as frequently as 40 per minute.

Consciousness.—There is no symptom of sinus thrombosis more subject to variation than consciousness, which in very

many cases, particularly if uncomplicated with meningitis, remains unimpaired up to the moment of death. Again, there may be speedy loss of it associated with wild delirium, or the patient may lapse into a somnolent condition, capable of being roused and interrogated with the result of eliciting monosyllabic replies; this state usually precedes coma. Loss of consciousness has been observed in 30 per cent. of uncomplicated cases and in 50 per cent. of cases complicated with meningitis and brain abscess. In 23 cases recorded by Hessler, in which the sinus phlebitis was complicated with meningitis and brain abscess, there was not a single instance of preservation of consciousness throughout the entire course of the attack.

With the appearance of the foregoing symptoms there is *loss of appetite* and usually *constipation*, although later in the disease, as the septic influences become more pronounced, *diarrhœa* is almost uniformly present. In a case of sinus thrombosis which, either with or without operation, terminates fatally, there appears a line of symptoms after a variable interval, but generally about fifteen days, which are recognized as indicating an unfavorable turn in the disease, and which by Macewen are arranged into three groups according as the dominant symptoms are pulmonary, abdominal, or meningeal.

The *pulmonary manifestations* begin insidiously, usually with a slight dyspnœa and cough, and patients complain of localized areas of pain over the chest, which may be confined to one lung, but are apt to involve both. These stitches of pain are due to the plugging of small pulmonary vessels and the establishment of infarctions here and there over the lung. These pains are followed in the course of 24 hours or so by rusty sputum and moist râles, which are the first auscultatory signs.

The *sputum* swarms with bacteria, and has an offensive, putrid odor, which may also be noticed on the breath. Large areas of the lung become gangrenous, and the abscesses resulting from the infarctions cause extensive disintegration. Cerebration remains active until the end, and death ensues from exhaustion.

The abdominal type manifests itself in *symptoms of a typhoid character.* Septic enteritis has indeed been so diagnosed under misapprehension of the conditions and failure to recognize the otorrhœa as the etiological factor. There is loss of appetite, dry furred tongue, and diarrhœa, the odor of the discharges from the bowel resembling that of the otorrhœa. There are but few rigors, generally not pronounced; there is great prostration and soon muttering delirium.

The differential diagnosis between septic enteritis and typhoid depends upon the absence of the rose-colored eruption and the recognition of the otorrhœa, with tenderness of the mastoid of one side and perhaps of the corresponding jugular.

"The meningeal group of symptoms is less frequently encountered than either of the preceding, and is rarely found without association with one or other of the formerly mentioned groups; the meningitis may arise from the infective thrombosis, but it may also originate directly from the primary source of the disease and appear as a complication, the symptoms of which may predominate over those of the sinus thrombosis" (Macewen).

The temperature is continuously high. Chills are incidental, but not frequent, and indicate the beginning or presence of some complication. Vomiting occurs frequently. There is apt to be clonic and tonic spasms of certain muscles of the face and neck, also paresis of others. The symptoms presented depend largely upon the portions of the brain involved, which the increasing precision in cerebral localization aids largely in determining.

Strabismus is a common symptom, and in case the leptomeningitis becomes spinal there are spinal indications, girdle pains, and absolute prostration. The patient can be aroused by interrogation, but exhibits extreme irritability if the interrogatory is prolonged, and I once saw a case, in consultation with Dr. Bacon, where the patient, usually a quiet fellow, upon being aroused by questioning, grew immediately abusive and blasphemous. In the later stages delirium supervenes, and the patient soon becomes comatose, after which the fatal termination is never long delayed.

These symptoms, as arranged by Macewen, are seldom encountered as typical manifestations in any given case. Indeed there are quite likely to be present symptoms from each group, but, as a rule, those characterizing one type or other will predominate; it should also be remembered that an array of symptoms closely simulating those just enumerated may arise from lepto-meningitis resulting from perforation of the tegmen tympani and without any participation of the sinus whatsoever.

Accepting the foregoing symptoms as embracing the essential manifestations encountered in the course of pyæmic sinus thrombosis, a pertinent question will be, Which of them are sufficiently constant to warrant by their presence a diagnosis of the affection?

The **diagnosis** in a typical case where the chronic suppuration of the ear is recognized, associated with repeated and severe chills, sudden and excessive rises of temperature, with rapid remissions, the establishment of metastases, either central or peripheral, and obstruction of the jugular, sufficiently pronounced to be recognizable to the touch, does not offer great difficulties. But it is highly essential to the successful prosecution of treatment that the condition be recognized if possible before the establishment of those symptoms constituting unquestioned pyæmia—that is to say, in the earlier septic stages. Here the presence of Griesinger's symptom, œdema of the region of the occipital vein with marked tenderness on pressure in the upper portion of the post-cervical triangle, will be a guide; and if the not thoroughly accepted Gerhardt symptom of diminished flow through the external jugular of the affected side can be determined, with rigors and sudden rises and remissions of temperature, with occasional vomiting and perhaps œdema of the eyelids of the affected side, with paresis of one or more nerves located in the region of the cavernous sinus, the diagnosis, if not assured, is at least sufficiently probable to justify one in taking the step which, no matter how pronounced the symptoms may be, must ultimately be resorted to for absolute proof of the presence of sinus thrombosis, viz., operative investigation. The honor of first suggesting

the feasibility of opening and cleansing the lateral sinus from disintegrated purulent thrombi, and of ligating the internal jugular as a prophylactic measure against the dissemination of infective particles, belongs to Zaufal (*Prag. Mediz. Wochenschrift*, 1880), as does also the distinction of being the first operator to undertake the removal of such an accumulation, which he four years later did (1884) in a case in which the sinus wall had become ulcerated, and upon removing the sigmoid groove he came upon the open sinus, out of which he expelled purulent masses by irrigation with an antiseptic solution. He did not re-establish the circulation from either direction, nor did he tie the jugular, but he introduced a drainage tube into the sinus lumen. The patient died of metastatic involvement of the lungs.

In 1886, Horsley, without knowledge of Zaufal's previous contributions, made the following recommendations: First, that the jugular be tied when in sinus thrombosis metastases are already present, as a defense against further metastatic processes; second, the simultaneous ligation of the jugular and the lateral sinus near the torcular Herophili, with opening and cleansing of the sinus from all infective material. In one case he ligated the sinus at two points and incised the wall between the ligatures; death ensued sixteen hours later from shock.

Such were the initial steps from which the operation for sinus thrombosis as now performed originated, and upon the measures advocated by Zaufal improvements have simply been as to detail. The essentials remain unaltered, while the advice of Horsley, that the sinus be ligated, has proved entirely undesirable in practice, for two reasons: First, the walls are very rigid and require that the ligature be tied exceeding firmly so that there is danger of cutting through them; second, the ligatures cannot be introduced without opening the subarachnoid space upon each side of the sinus and materially increasing the likelihood of lepto-meningitis.

The question of how and when to operate in the disease under consideration, it would seem reasonable to suppose, might with increasing experience be determined beyond peradventure; it may however be said that great diversities of

opinion regarding the treatment of these conditions still exist, especially with reference to the precise steps to be instituted and the most advantageous moment for their exhibition. This is partly due to the faculty of individual observers for attributing a different significance to certain variable groups of symptoms, and to an honest inability to agree on the interpretation of the value of some constant phenomena. The former manifestations may in a given case be insignificant, and the absence or suppression of the same may in the next instance prove momentous; wherein the personal equation is entitled to distinguished consideration.

In discussing the advisability of operation upon sinus thrombosis, we will first consider that factor upon which the greatest unanimity of opinion exists, viz.:

When to operate.—The views of two celebrated writers upon the subject may be here aptly appended. Koerner says, "As soon as you have made the diagnosis of sinus thrombosis, the moment to operate has arrived," and conveys the impression that further delay is a calamity. While Hessler, on the contrary, says (*Die Otogene Pyämie*, p. 483): "When puncturing the sinus with an aspirating needle shows that a simple clot is present, operation is not indicated, but repeated daily punctures should be made and the contents of the aspirating needle carefully examined microscopically for pus and micro-organisms. The failure to find these is to be accepted as proof that the clot is benign and will undergo constructive organization, while the discovery of bacteria in the contents of the aspirator is indication for operation"; and he depreciates undue haste in opening the sinus.

The attitude of Hessler is practically unique, and, so far as I am aware, unsupported; it is open to what appears a valid objection, that in the event of the thrombus being non-infective the frequent puncture tests made with an aspirator would speedily compass the result he endeavors to guard against—that is, infection. And again there might exist several small foci of suppuration in the clot, which his punctures did not discover, but from which septic absorption could readily originate and dissemination begin.

Körner voices the sentiment of the great majority of

operators, there being practical uniformity in the advocacy of immediate operation upon the sinus as soon as we are certain of its being the site of obstructive phlebitis. This appears to be rational treatment, for with the thorough removal of the clot, the danger to the patient of any further infection is removed, while the presence of the thrombus is a continual menace to life not to be tolerated, notwithstanding in a few instances it has remained innocuous and become organized. The tendency of infective thrombosis is always toward disintegration and the establishment of metastatic embolic processes. If in a few cases a more favorable termination has supervened, the result may be cause for congratulation, but does not justify us in anticipating a repetition of it, or failing to meet the clearest indications for operative interference.

How to Operate.—For sinus thrombosis remains to-day as much a surgical shibboleth as at any time during the past five years.

Surgeons may be arranged into two groups or schools:

First.—Those who advocate jugular ligation.

Second.—Those who oppose jugular ligation.

The solution of the question under consideration is rendered perplexing by the fact that illustrious names may be found enrolled under each of these standards, but the array of the advocates of ligation musters a formidable majority when numerically compared with the opponents of this measure, and in fact recent otological literature is steadily recruiting the ranks of the majority.

Among many who practise jugular ligation in connection with operations upon the sinus, and whose published reports are accessible, may be enumerated: Zaufal, Horsley, Lane, Balance, Forselles, Macewen, Jansen, Körner, Voss, Parkin, and others too numerous for recapitulation; while Schwartze and Salzer, with their students and followers, are chiefly those who do not countenance ligation of the internal jugular in cases of pyæmic sinus thrombosis.

Schwartze's chief arguments against ligation are: that many cases have recovered without it; that tying one jugular does not guarantee that infective particles may not be carried

into the lungs through the other; that the procedure adds materially to shock of operation, as the jugular is at times wellnigh impossible to find, owing to cellular infiltration of the neck, and that under certain circumstances fatal hemorrhage might ensue on opening the neck,—in such a case, for instance, as that reported by him (*Archiv für Ohren.*, vol. xvi., p. 265), in which the autopsy showed that the jugular had suppurated and was entirely destroyed down to within 2 or 3 *cm* of the clavicle, where it was still pervious and filled with blood.

The opinion of Körner is even more forcibly expressed in favor of ligation. He says (Körner, p. 76): "When the sinus contains putrid material, pus or a disintegrated clot, it is advisable, before any further manipulation, to ligate the internal jugular below the thrombus, for one can never know whether the sinus is centrally completely occluded by a firm clot, or whether, in curetting and syringing, portions of the thrombus may not become detached and metastases result therefrom. The fact that certain cases of sinus phlebitis have recovered after curetting without ligation of the jugular is no excuse for neglecting this important and harmless precaution!"

While it is possible that, after ligation of the jugular of the affected side, infective particles may be carried through the circular sinus or by way of the torcular Herophyli into the other jugular, it is not proven, and we can be certain that in the vast majority of cases the occlusion of the jugular will preclude further dissemination of septic material.

There are numerous cases on record where pyæmic symptoms already well established (Balance's case had septic pneumonia) have disappeared and recovery ensued after removal of the septic foci; if metastases are present in the lungs, kidneys, or liver, the prognosis is bad, but in non-infective infarction of the lung good! Peripheral metastases are easily managed and generally very amenable to surgical treatment.

The wellnigh universally recognized *method of procedure* for the relief of sinus thrombosis is to uncover with chisel and rongeur the sinus at the knee and descending portion.

Before this is done, however, the antrum mastoideum should be freely opened, as it is the largest cavity in the mastoid apophysis, and may, if not thoroughly cleansed, remain a source of continued infection. The presence of a thrombus having been determined, its extent can be ascertained by inspection, palpation and aspiration. It can often be seen dilating the sinus walls as if a cord too large for the lumen had been forcibly drawn into it and upon palpation it feels firm, dense, and resisting. The needle thrust into it brings away either serum, disintegrated clot, pus, or nothing at all as the case may be. The area of sinus involved may be small, or it may extend well back toward the torcular and down toward the bulb. In any case, the sigmoid groove must be cut away sufficiently to admit of full investigation of the thrombosed portion, for otherwise any attempt at operative relief is attended with needlessly embarrassing difficulties. At this point in the operation one must determine regarding the desirability of ligating the jugular. Having decided in favor of the step, it should be made at once before opening the sinus. Having decided against it, the sinus wall should be freely incised in its long axis and the obstructing contents removed by a sharp curette, first from the direction of the torcular and the current re-established from this direction. Do not feel too great an anxiety to control the flow of blood at once; the outflow if momentarily encouraged may expel infective masses which would otherwise remain as dangerous tenants. When the flow is sufficiently rapid to convince you that the lumen is clear, a gauze tampon packed upon and not in the vessel-opening will control it easily and safely.

The same steps must now be repeated in the proximal end of the open sinus until circulation is here re-established and controlled better by packing gauze into the lumen of the vein. Its withdrawal at a later dressing is seldom followed by bleeding, owing to the crooked course of the groove at the bulb, the clotting taking place very readily and firmly, quite in contrast to the sinus in its horizontal portion, which, if you pack gauze into its lumen any distance, is almost certain to bleed more or less profusely at the first, and may be at the second dressing, and in one case of mine even at the third.

In the event of failure to re-establish the circulation from below the jugular bulb, whether you have removed a purulent disintegrated clot or not, it is your imperative duty to your patient to tie the internal jugular forthwith, as you otherwise leave wide open the main avenue to almost certain pulmonary metastases. Just at this point the writer desires to enter a vigorous protest against a procedure which he has occasionally witnessed upon the operating table, and himself participated in, when an attempt is made to force the return circulation from below upward through the obstructed bulb by forcible manual pressure upon the muscles of the neck. I believe that all attempts at re-establishing the circulation by making pressure from below upward upon the muscles of the neck, in the hope of dislodging the clot, cannot be too severely condemned; it is a procedure in my opinion eminently calculated to favor the dissemination of obstructing infective material either directly through the jugular or collaterally through the tributary veins. Upon the same reasoning, all manipulation of the carotid triangles other than that necessary for the recognition of the infiltration along the jugular should be discountenanced, and when once the diagnosis is made, positively forbidden.

The prevailing opinion at the present time among operators undoubtedly favors ligating the jugular, in all cases where the toxic symptoms are pronounced or where metastases are already present, as a preliminary step to opening the sinus; also in those cases in which the toxæmia may not be marked and metastases are absent, if the thrombus involves any very large area of the vein especially at the bulb; the jugular should be tied before the sinus is opened. The safest way, as indicated by Voss, is to uncover the sinus first and verify the diagnosis, then tie the jugular and you are on the safe side. In endeavoring to estimate the value of this operation statistically, we must bear in mind that cases without metastatic involvement offer a much more favorable prognosis than those complicated with such processes, in which the system is called upon to combat a more severe sepsis.

The writer's personal experience is limited to three cases, in each of which the symptoms were sufficiently marked to

make the diagnosis before operating, and all of which fortunately have recovered. They are here appended in their chronological order, with perhaps more attention to detail than the cases warrant, but such minutiæ may be helpful to some other practitioner who finds himself for the first time with such an affection to treat.

CASE I.—**Pyæmic Sigmoid Sinus Thrombosis.**

Moses H., German, aged 42 years, applied for treatment at the Infirmary in June, 1896.

Patient had always enjoyed good health until December, 1895, when he had acute suppuration of right ear followed by mastoiditis which was operated upon by his local physician, in Scranton, Pa. Symptoms subsided but otorrhœa has persisted until the present; he now, however, complains of a glandular swelling in front of and below the ear occupying the situation of the parotid gland. This I dissected out without difficulty, the wound healing readily, but the patient suffering with facial paralysis as the result of the operation.

The specimen removed was submitted to the pathologist, who reported that it was a round-celled sarcoma.

On January 30th, 1897, the patient reapplied at the Infirmary for treatment. There was slight induration about the edges of the scar left from the operation for the removal of the growth, but nothing of any significance. He now applied for treatment of his right ear.

Upon physical examination the canal of the right ear was found filled with granulations and a probe introduced came into direct contact with a large sequestrum. No details of tympanum could be recognized. The entire mastoid region appears red, swollen lœdematous, the œdema extending backward quite to the occipita protuberance. This entire area is exquisitely tender, most particularly so over the region of exit of mastoid vein. The right tonsil is discharging pus and has a small mass of granulation upon its upper border; this may possibly lead to a sinus in the petrous bone or may be an extension of the sarcoma.

Patient has been treated during the past month by a surgeon of this city who curetted the granulations of the canal on three occasions at intervals of one week; these procedures occasioned him great pain and after the last curetting four days ago, he suffered severe cephalalgia which has now, he says, become intolerable.

During the same period he has had a chill followed by fever each day, with vomiting of everything taken into the stomach, and vertigo so marked that on entering the clinic he staggered like a drunken man. Upon admission to the hospital his countenance wore a distressed and anxious look and was expressive of prolonged and severe suffering. His temperature was 102.50 F. A diagnosis of probable sinus thrombosis was made, and the man was prepared for immediate operation which was performed at 4.30 P.M., on January 30th, 1897.

A curvilinear incision was made parallel with the post auricular fold extending from a ½″ below the tip of the mastoid process to 1″ above the temporal ridge; periosteum adherent over the entire apophysis. The cortex was of glaring whiteness and exhibited a small dimple-like depression ⅓″ from the external auditory meatus and directly posterior to it, the site of a previous operation for the relief of mastoiditis.

The lower two thirds of the mastoid process were entirely sclerosed and were of stony hardness, as was, indeed, the cortex of the entire apophysis; but the upper third, after removal of the outer table, was found necrosed, a sequestrum extending from the posterior wall of the bony meatus directly backward to and including the wall of the sigmoid groove. The entire process was removed as rapidly as possible with chisel and rongeur and the sinus exposed from the knee down to the bulb. It was much distended and very firm and resisting to palpation with the finger. Pulsation of the sinus could be plainly seen and felt and was evidently propagated from the underlying brain tissue. A second incision was now made on a level with the external auditory meatus, directly backward toward the occipital protuberance and the lateral sinus uncovered backward from the knee 1″. The sinus walls having been thoroughly sterilized by solution of bichloride of mercury 1 to 5000 and then with hydrogen peroxide.

An aspirating needle was introduced downward toward the bulb and backward toward the torcular without obtaining any blood, but only a little serum, odorless and containing many leucocytes. The parietal sinus wall was free of any lymph or granulation, nor was any pus found in the cranial cavity; the necrotic bone in contact with the sinus was very dark and contained a fluid much the color of coffee dregs but odorless.

The sinus wall was now incised, and a firm, fibrinous clot exposed; this was very easily removed by forceps, and after the

central portion had been withdrawn, the pressure of the blood-current and the elasticity of the vessel walls forced the remainder out without any curetting and the circulation was re-established from below and above. Packing of iodoform gauze easily controlled the flow. As there had been no tenderness along the course of the internal jugular and no induration to be felt, it was considered that ligation was not indicated and it was not performed. The appended chart of temperature, pulse, and respiration shows the moderate daily variation of an uninterrupted convalescence. The sepsis was of a low degree and recovery was complete. Seven months after the operation, patient was seen and was undoubtedly suffering from a return of the sarcoma in the face. He had great difficulty in opening the mouth, both because of the induration of the muscles upon the side of the face and probably also from erosion of the articular cartilages of the jaw. He was emaciated and sallow, presenting the cachectic appearance of a cancerous subject. Whether he still lives or has succumbed to the inroads of malignant disease I do not know.

The feature of especial interest in this case lies in a consideration of the immediate cause of the thrombosis. This appears to me beyond reasonable doubt to have been the direct sequence to the curetting of the granulations in the tympanum, which, until their destruction, had acted a conservative part, and the removal of which had opened a channel for the introduction of pyogenic germs into the cranial cavity. Numerous observations corroborate this view, for cases are not uncommon where extensive sequestra have been removed in which large areas of the inner table of the skull, oftentimes with a portion of sigmoid groove, were included, showing that the sinus had been in direct contact with a carious surface (frequently in cases of extra-dural abscess bathed in pus), and still had escaped infective phlebitis; moreover, the patient has exhibited no symptoms of even the mildest sepsis, the granulation deposited upon the dura acting as a thoroughly efficient protection against absorption. But should this defence, through operative or other mechanical interference, be broken down, the exceedingly vascular richness of the structure causes it to absorb with sponge-like avidity. These conditions were, in my

opinion, responsible for the infection in the case just described.

A second interesting feature is the presence of visible and tangible pulsation in the sinus walls, notwithstanding the fact that the lumen was firmly distended with clot. This observation was verified by several gentlemen present at the operation, and distinctly indicates how little importance can be attributed to pulsation of the sinus as evidence of its patency. In the present instance it was undoubtedly propagated from the brain.

Also worthy of mention is the fact that although the clot in this case had not disintegrated and was odorless, it must have been just upon the point of breaking down, because great numbers of pus cells were in the fluid withdrawn by the aspirator from the sinus. The infection of sinus evidently took place by direct contiguity with carious bone, for there was found in the cranium neither lymph, pus, nor granulation.

Case 2.—Pyæmic Thrombosis of Sigmoid Sinus—Double Ligation of Internal Jugular, with Incision of Sinus Walls and Removal of Purulent Thrombus-Metastases.

Mrs. D., born in Germany, aged thirty years, mother of three healthy children, always been strong and well. Admitted to the Infirmary, July 28, 1897, with the following clinical history.

During the last week of February she suffered with a severe attack of the grippe, and, to relieve the congestion of her head, used a nasal douche of salt solution on two occasions, the last of which was followed by sharp pain in the right ear. This pain continued for three days, and was relieved by the appearance of profuse suppuration, which, after three days, diminished in amount, and the mastoid became tender, and later swollen and œdematous. Was treated by douching until March 20, 1897, when she was admitted to the wards of the Infirmary in the service of a colleague, to whom I am indebted for these notes of her condition. On admission, her temperature was 100° F., mastoid swollen, œdematous, and very tender; supero-posterior canal wall was bulging, and discharge was profuse. Cold coil was applied for thirty-six hours, with hot douching every three hours, tenderness and pain persisting, with temperature 100°.

She was operated upon March 22, 1897. Mastoid process was the seat of empyema, and was removed, with the exception of the tip. The wall of the sigmoid groove was carious and removed by curetting, exposing the descending portion of the sigmoid sinus for ½", which, showing no symptom of involvement, was not investigated. Patient did well subsequent to operation, and was discharged from hospital for attendance and dressing at clinic, on April 3d, at which time temperature was 98°. Wound was dressed in dispensary for the next three months, and the process of healing was noted as very slow. Necrosed bone was recognized as being present in the wound, but she presented no symptoms of any systemic disturbance until July 24, 1897, when she had a severe chill and rapid rise of temperature. During the following four days she had at least one chill daily, and sometimes two, with accompanying fever, loss of appetite, and frequent vomiting, independent of the presence of food in the stomach.

On the fifth day after her first chill she was admitted to the hospital on my service, July 29, 1897. Patient was carried into the ward and placed in bed, exhibiting all the signs of collapse, a small, feeble pulse, 108; temperature, 101°; a complexion of ashen hue; respiration, 28; the features having an anxious, pinched look, and being covered with colliquative perspiration. Temperature rose rapidly after admission to the ward, and at 6 P.M. was 106°; this declined rapidly, and a few hours later was 101°. She was stimulated with whiskey, strychnia, digitalis, etc., and was freely sponged with alcohol during the febrile rise. Her heart sounds were normal, although the action was feeble. The urine contained a large amount of albumen by volume, together with some hyaline and blood casts; reaction alkaline; specific gravity, 1015.

When called to her I found the following conditions:

Physical Examination.—External auditory meatus slightly excoriated from an acrid discharge. No bulging of the fundus, and in the infero-posterior quadrant of the membrana tympani a small perforation through which a scanty discharge is escaping.

Inspection of the mastoid shows an open wound, the result of incomplete healing after mastoid operation; the lips of the wound are sloughing, the granulations upon their margins disorganized and bathed in ichorous discharge.

A considerable area of necrosed bone, very dark in color and cribriform in appearance, present in the gaping wound, and is

irregular in outline. The flaps of the wound are œdematous for a considerable distance backward toward the occiput and upward toward the vertex, over which region palpation elicits moderate tenderness. There is marked tenderness along the course of the jugular in the neck, and the patient complains of pain even upon the slightest manipulation. A fact of much interest, in view of what subsequently occurred during the course of healing, may be appropriately mentioned here. While inspecting the cervical region of the patient upon the affected side, I laid my finger with sufficient force to make obstructive pressure across the course of the external jugular, and notwithstanding that the pressure was continued for a considerable period, no turgescence of the vein ensued, and, indeed, there was no appreciable difference to be noted in the size of the vessel when pressed upon or when unimpeded; while upon the healthy side the external jugular, although not unduly prominent, upon very light pressure became immediately engorged to a pronounced degree.

The scalp having been shaved as far backward as the median line of the occiput, and upward to within 1½″ of the vertex, and all the affected side of head and face rendered thoroughly aseptic, the patient was placed upon the table and anæsthetized at 9.30 A.M., July 29, 1897. Ether.

Operation.—The wound made in the original mastoid operation was extended directly upward to the squamous suture, and a second incision was made extending backward from the first at the level of the centre of the meatus auditorius externus three inches, or nearly, to the occipital protuberance; these flaps were easily raised except near the site of the original wound, where the periosteum was adherent and thickened. When the flaps were elevated over the foramen of exit for the mastoid vein, there was no bleeding, an important diagnostic point. With sharp curettes and rongeur an extensive area of necrosed bone was removed, extending from the remains of the mastoid tip upward well into the squama, exposing the temporo-sphenoidal lobe, and backward over the sigmoid groove, the entire bony wall of which, as far downward as the foramen lacerum posterius, was soft almost like cork, and was easily broken away in large pieces; there was necrosis of the entire mastoid apophysis.

The sigmoid sinus was uncovered at the knee and backward 1½″ along the horizontal portion, also all the descending portion as far as the jugular bulb. Every bit of the inner table comprised

in the sigmoid groove was discolored, a dark or brownish hue more marked downward toward the jugular, and was roughened and fenestrated with numberless minute perforations, in none of which were any granulations found. Upon inspecting the parietal wall of the sinus it was found quite free from any plastic lymph or granulation, was greatly distended, tense, and prominent; there was *no pulsation seen or felt*, and upon palpation the sinus was very firm and resisting; the walls were intact throughout both on parietal and visceral surfaces, there being no discoverable point where ulceration had supervened.

The exposed dura in the immediate neighborhood of the sinus appeared normal in color, and did not bulge or pulsate unduly; a thoroughly sterilized aspirating needle was now introduced into the sinus as far back toward the torcular as the opening in the bone would permit; the attempt at aspirating was negative; the needle was again rendered aseptic by boiling, and reintroduced at the jugular bulb, which second attempt at aspiration was equally unproductive. Feeling, thereupon, entirely certain that a thrombus filling the sinus completely had been encountered, I incised the parietal wall parallel to the course of the vein from behind downward to the bulb; there was no flow of blood following the incision, and the exposed clot varied in consistency from a firmly organized resisting mass near the torcular to a collection of thin, foul-smelling pus with some stringy inspissated lymph, which adhered closely to the vessel walls at the bulb.

The proximal end of the opening, in which was the greatest quantity of pus, and where the disintegration of the thrombus was complete, was packed with iodoform gauze, that its contents might not mingle with, and further infect, the contents of the distal extremity of the sinus.

With a curette the sinus toward the torcular was quickly cleared of its obstructing contents, and a copious flow of blood allowed to escape momentarily unchecked, with the anticipation that any loose infective particles might become in this manner detached and expelled; the bleeding was then controlled by packing iodoform gauze into the lumen of the vein, and the curetting applied with diligence downward to the jugular bulb, from which much thick, ropy pus and granulation of putrid odor was removed, also a considerable quantity of what appeared like cholesteatomatous material, but no flow of blood was established, notwithstanding the fact that the curette was passed through the posterior lacerated

foramen into the jugular vein; pressure below on the neck from the clavicle upward in the course of the vein was also inefficient, and all attempts to restore the circulation from this direction were abandoned.

The opening in the sinus and the wound in the skull were now thoroughly flushed out with a solution of bichloride of mercury 1—5000 and as rapidly as possible packed with iodoform gauze.

After cleansing the skin of the neck and chest, and making the region aseptic, the internal jugular was exposed throughout its entire length, and after being raised from its sheath was ligated in the inferior carotid triangle one half inch or more below the level of the clavicle, and also at its emergence from the skull; the facial vein, which was patent and which bled upon being intentionally wounded near its junction with the oblique, was likewise ligated. When first exposed upon opening the neck the jugular did not pulsate and felt as if filled with a soft cruoric clot; this proved to be precisely the case, for upon splitting the vein between the ligatures a soft fibrinous clot was encountered which was easily stripped with the fingers from its endothelial lining; this clot was evidently a very recent extension into the jugular, for it did not seem to be organized or even firmly adherent in any part and was free from odor. Low in the neck as was the ligation, it is my belief that the coagulation extended still deeper, probably quite to the innominate vein, but was enacting a conservative process forming a barrier which prevented the dissemination of the disorganized infective thrombus above. The wound was drawn together at the centre with a stitch and was packed with iodoform gauze above and below. The vein was not resected. The side of head and neck were then dressed with iodoform gauze over which a layer of bichloride gauze was placed, the whole covered with cotton and bandaged.

The duration of the entire operation was one hour and thirty minutes, during which time the patient required free and constant stimulation; upon returning her to bed, hot-water bags were applied to feet and epigastrium, and transfusion of normal salt solution at temperature of 105° F. was made into the cellular tissues of the abdomen, sixteen ounces in amount; patient rallied promptly and appeared stronger. Two hours later her heart action again became weak but reacted to hypodermic stimulation. At 12 M. temperature 100°, at 2 P.M., 103.2°, the highest point

during the day. She complained of pain in the occipital region and experienced relief upon the application of an ice-cap.

July 20, 1897. Patient passed a nearly sleepless night, although complaining of but little pain. She had retained all medicine and nourishment during the twenty-four hours ensuing after the operation, while for three days before the operation she had vomited everything taken into the stomach. During the following three days the condition of the patient was most critical; her temperature was high—on one occasion 104.2° and seldom below 100°; her pulse averaged nearly 120 and her respirations about 40 to the minute. She slept infrequently and for but brief periods. There were no attacks of heart failure, for the stimulation of strychnia, digitalis, whiskey, and ammonia was persisted in, and her stomach refused nothing that was offered. To this most fortunate circumstance and to her own fortitude the woman largely owed her recovery from the ensuing long illness.

On August 3d, 96 hours after the operation, the packing was for the first time removed entirely from the wounds of the skull and neck. Up to this time the outer dressings only had been changed. Upon removing the packing from the distal end of the opening in the sinus there was free hemorrhage, and fresh packing of iodoform gauze was quickly introduced, easily controlling the flow. When the bulb was washed out there was scarcely any detectable odor to the scanty discharge expelled; in this wise differing materially from one case reported by Forselle where the odor persisted in the discharges for ten days or more. The wounds looked healthy and were beginning to granulate and were repacked as before. On this day the urine examined was found free of albumen for the first time. A few casts were, however, still noted.

She complained of some pain in the left arm just over the outer condyle of the humerus, and the tissues, feeling somewhat indurated and looking slightly reddened, were poulticed; the following day deep fluctuation could be felt and an abscess was opened and six ounces of pus evacuated—sixth day after operation.

On the following day patient's temperature again mounted rapidly to 104°, and she complained of pain in the left thigh; on palpation deep fluctuation was felt and the contour of the thigh looked slightly bulging on the outer aspect. After incision, twenty ounces of pus were evacuated. This abscess was opened six days after the operation. Upon the eighth day all the dress-

ings of head and neck wounds were again changed. There was still some little bleeding from the distal end of sinus opening, easily controlled by gauze placed against the opening and not packed into the lumen of the sinus.

During the next five days the patient's condition improved gradually. She took more nourishment and appeared stronger, but upon August 12th, the fifteenth day after operation, she became suddenly delirious, and when free from restraint attempted to leave the bed; her delirium was active for about one week, and then slowly began to mend, and in two weeks had entirely disappeared. On August 22d there was detected a small *abscess in the sterno-cleido mastoid muscle* about in the middle third, in opening which the incision was carried directly across the course of the external jugular vein, which vessel was divided. The cut ends of the vein thus exposed were greatly thickened, appearing to have the firm tense walls of a large artery—and gaping widely instead of collapsing, as is usual with a vein; there was no clot to be seen in the lumen, but notwithstanding this fact no blood escaped from either end of the divided vessel.

On August 25th, the examination of urine showed no albumen, no casts, but few epithelial cells. On this same day a swelling was noticed on the right arm, just below the external condyle; it was tender and fluctuated, and upon being opened pus to the amount of two ounces was evacuated; this was the last metastatic manifestation in the case, and occurred twenty-eight days after the operation.

The wound in neck closed six weeks after the operation, the healing being, I believe, much retarded by the presence of the jugular, which should have been resected and which, having been in part infected, suppurated instead of becoming organized.

On Sept. 20th, the patient's temperature became normal, and she was permitted to sit in a chair beside the bed; and on October 4th she was discharged from the hospital for further attendance in the outdoor clinic, having been sixty-eight days under treatment, a very protracted convalescence, but when the intensity of the sepsis is considered, even this tardy recovery is cause for hearty congratulation.

The *features of especial interest in this case* appear to be:

First. The fact that the portion of the tip of the mastoid, which was not removed at the first operation, must have been

carious at that time, although appearing healthy to the operator, for when the sinus operation was performed, this portion of the process was as soft as punk, and the disintegration of the clot at this point was much further advanced than elsewhere: an indication that the infection was most virulent in this neighborhood.

Second. The presence of a clot extending the entire length of the internal jugular vein quite to its union with the innominate, also the complete obstruction of the current in the external jugular with the marked thickening of the vessel walls.

Third. The entire absence of all acutely inflamed lymph nodes in the neck along the course of the occluded vein, notwithstanding the fact that there was marked tenderness, and upon incision its walls were materially thickened and softened,—satisfactory proof of the existence of phlebitis.

Fourth. That the omission to resect the vein after its double ligation was an error; for the infected vessel did not become completely organized, but a portion of it sloughed and retarded the healing of the neck wound considerably.

Fifth. That no pulsation of the occluded sinus could be seen or felt, and that its parietal walls were free of any lymph granulation or pus. That packing of the distal end of the opened sinus is unwise; for its removal displaces the organizing clot, delays healing, and invites infection; very moderate pressure of a gauze pad when reinforced by the tight bandage is an entirely efficient hæmostat. Parker advised packing the lumen of the sinus with cat-gut, but it has not been tried.

Sixth. The sudden attack of delirium very active for several days, and then diminishing in intensity until her cerebration became normal, about fourteen days later. This attack suggests the likelihood of a small, non-infective cerebral embolus.

Seventh. The length of time intervening between the operation and the last metastatic manifestation, twenty-eight days, must make a surgeon very guarded in his prognosis, even after a considerable period has elapsed and when his patient shows every sign of speedy convalescence. In

the present case there seems a reasonable probability that had not the main avenue of approach to the lungs, *i.e.*, the jugular, been obliterated some of the septic material which was later so widely disseminated, must have found its way thither.

Eighth. Another indication of the virulent sepsis in this case is afforded by the *fact that every hypodermic injection the patient received during the operation produced a superficial abscess* varying in extent from $\frac{3}{4}''$ to $1''$ in diameter. The house surgeon vouched for the cleanliness of his needles, and promptly administered a hypodermic to himself with the same needles and remedy, without unfavorable consequences!

Ninth. The entire subsidence of the acute inflammation of the kidney, with complete restoration to the normal function of that organ in thirty days after operation.

These observations, it seems to me, constitute the essential clinical manifestations in the case.

CASE 3.—Pyæmic Thrombosis of Sigmoid Sinus, with Extension into the Inferior Petrosal and Cavernous Sinuses of Probable, Non-Infective Clot—Metastases—Double Ligation of Internal Jugular, with Resection of the Vein and Incision of Sigmoid Sinus Wall, with Removal of Disintegrated Thrombus.

Sarah G., German, aged twenty-three years, married, applied for treatment at the infirmary on Nov. 26, 1897. Patient suffered with tonsilitis two weeks ago, and upon recovering from this illness first experienced pain in the right ear five days since. When a small child she had otorrhœa following measles, but the discharge ceased, and she had been free from it until the present attack.

Physical examination shows a tympanic membrane very red, and slightly bulging in the supero-posterior quadrant. In this same quadrant there is a small perforation, from which a scanty purulent discharge oozes. The mastoid region is negative to inspection, and tender only over the tip upon deep pressure.

Patient was admitted to the hospital at once, and leeches were applied to the mastoid. Leiter's cold coil ordered, with hot bichloride of mercury irrigation every three hours. Upon admission her temperature was 100.2°, pulse 104.

This treatment was continued forty-eight hours, when, the ten-

derness of the tip having subsided, it was discontinued. At this time her temperature was 99°, pulse 88. Patient continued in the infirmary, complaining of moderate deep pain radiating from the ear over the whole side of the head. On Dec. 5, 1897, this pain increasing somewhat and having a throbbing character, it was decided to open the mastoid, which was done under ether at 11.30 A.M., at which time her temperature was 98°, pulse 90.

The usual mastoid incision exposed a small and narrow process, the cortex of which was at no point eroded. Upon opening the bone with a chisel and rongeur, a diploic mastoid was encountered, in the antrum of which were a few drops of offensive pus. The cells of the tip contained no pus and but few granulations, yet from the antrum downward and backward to the sigmoid groove the bone was carious. In removing the carious wall over the sinus with a rongeur, a small spicula of bone broke off and punctured the sinus. The fragment of bone was removed with forceps and the sinus allowed to bleed for an instant, to favor the expulsion of any septic matter from the vein, if such had been introduced. The hemorrhage was easily controlled by a gauze pack laid over the opening and not thrust into it; more carious bone along the groove was removed toward the bulb until the structure seemed healthy, when the wound was packed with gauze and patient returned to bed. Twenty-four hours later her temperature was 102.4°, pulse 112, respiration 24. Seventy-two hours after operation, temperature 102.6°. Wound dressed, packing taken away from sinus wall. No hemorrhage. Four days after operation there appeared slight œdema of the eyelids of the right side. Fifth day wound dressed. Appeared healthy. No bleeding from sinus.

Seventh day œdema of lids of right eye almost disappeared, and œdema of lids of left eye first noticed. At 3.30 patient had a sharp chill with a rapid rise of temperature to 104.2°.

Eighth day great pain over whole side of head; tenderness along the course of jugular in the neck, but no induration to be felt. Patient was seen at this time in consultation by Drs. Gruening, Bacon, and McKernon. All advised operation, but patient steadfastly declined.

On the following day her husband insisted upon removing her from the hospital, and the house surgeon was ordered to dress the wound; he removed all the packing and irrigated the opening. Noticing a clot he removed it with forceps, when a rapid

hemorrhage from the sinus took place—about five ounces—easily controlled by gauze dressing ; in fact it had nearly ceased spontaneously before dressing was applied.

The next day, December 16, 1897, she was removed to her home against my urgent protest, and at this time not only was there tenderness in the superior carotid triangle, but a distinct cord-like infiltration was plainly to be felt.

After 36 hours at home, she applied for re-admission to the hospital, and upon December 18th was again accepted for treatment.

The patient now appeared to fail rapidly. The color in her cheeks, which she had retained until now, faded. The pain in the head became more severe, œdema of the left eyelids and brow again appeared, and double neuro-retinitis could be easily diagnosed with the ophthalmoscope. The friends of the patient, recognizing the unfavorable change, urged her to consent to an operation, which was performed December 22, 1897. Patient's head, face, and neck were thoroughly cleansed and rendered aseptic. Ether was administered. The ligation of the jugular as the first step in the operation having been determined upon, an incision was made along the anterior border of the sterno-cleido-mastoid muscle, extending from a point just below the lobule of the ear as far downward as the superior border of the clavicle. The fascia was opened and the sterno-mastoid muscle raised from its bed. This step was accomplished with the utmost difficulty, the muscle for the upper two-thirds of its extent being firmly glued to the underlying layer of fascia as a result of inflammatory infiltration. Upon completing this dissection, a number of large, acutely inflamed lymph nodes were encountered, which were removed, and one very large node lower in the neck, which was apparently not acutely involved.

The search for the internal jugular was prolonged, for no trace of it was to be seen beneath the thickened fascia, and it was necessary to uncover the common carotid before the sheath of the jugular could be recognized and separated from an agglutinated mass of muscle and fibrous tissue.

Upon opening the jugular sheath, *the vein beneath the omo-hyoid lay like a broad red ribbon, quite collapsed, and apparently containing no blood.* A ligature of cat-gut was passed around it as far down in the neck as possible, just about at the level of the clavicle and firmly tied, immediately after which ligation the vein filled with

blood for about two inches above the ligature, probably from a thyroid vein, as the pressure from it was very slight.

The sheath of jugular was now opened its entire length, as near as possible to its point of emergence from the skull, and ligated a second time. The portion of the vein lying above the omo-hyoid muscle was firm and round, about the size of a large lead-pencil, increasing gradually in bulk as it approached the bulb. It was in this part of the neck that the acutely inflamed glands were found. The jugular was resected between the two points of ligation and close to them. From its proximal end a small, recently formed, jelly-like clot escaped, which was without odor. From the distal end there oozed out foul-smelling, thick pus. The wound in the neck was now packed with gauze temporarily, and the former incision in the scalp, made at the mastoid operation, extended upward to within an inch of the vertex. A second incision was then made directly backward, toward the occipital protuberance, 2½ inches, at a level with the centre of the bony meatus. The flaps were retracted and the periosteum raised without difficulty. With a rongeur and chisel, the covering of the sinus was removed, the bone being softened toward the bulb and elsewhere hard.

All the descending portion of the sinus was exposed, and about one inch of the horizontal or lateral sinus. There was a small amount of lymph on the parietal sinus wall at the point where it had been injured in the mastoid operation. Elsewhere there was neither lymph, granulation, nor pus. The horizontal portion of sinus appeared normal, dimpling easily under the finger, while the descending portion was firm and resisting, but not apparently dilated. It did not pulsate. The bone removed from this part of the process was very dark. Placing a small firm compress upon the horizontal portion of the sinus, incised the descending portion for 1½ inches. There escaped at once a small, soft, odorless clot. A curette was then introduced toward the bulb, and about two drachms of very foul-smelling thick pus and caseous matter removed. The bulb was then syringed out with bichloride 1 to 5000, which brought away more offensive-smelling material. This portion of sinus was packed with gauze, and the incision extended upward the sinus wall well into the lateral portion. Copious bleeding followed, which was easily controlled by gauze packing not carried into the lumen of the sinus.

The granulations which had begun to grow in the antrum and

mastoid following the preceding operation were curetted rapidly, and the bone beneath appeared quite firm and healthy.

The wounds were now stitched in part—that in the skull toward the occiput and toward the vertex sufficiently to bring the flaps down nearly to the old wound ; that in the neck was stitched for its lower half, the borders of the deep fascia being approximated where possible. The open wounds were then packed with gauze, that in the neck lightly, that in the skull with firm pressure, then all bandaged with continuous bandage, a pad of cotton being placed over the left jugular to minimize pressure of the bandage around the neck.

So well had the anæsthetic been timed that the patient was quite conscious during the stitching of the last few sutures. Her pulse being very rapid and feeble, she was immediately transfused with normal saline solution, 16 ounces in amount, introduced through the median basilic vein at the temperature in the reservoir of about 108°. The effect of this was instantaneous ; pulse became markedly fuller and slower. Hot-water bags had meantime been placed over her cardiac region and at her feet. She had received frequent and vigorous stimulation during the operation by hypodermic injection. Two hours after the transfusion the pulse failed very rapidly again, and $\frac{1}{50}$ gr. of nitro-glycerine was administered hypodermically. The heart responded to this and did fairly well until two hours later, 9 P.M., when, it again failing, transfusion was once more resorted to, and 26 ounces of normal saline solution, temperature 105° in reservoir, was thrown into the circulation through the median basilic vein of the other arm (left). Prompt reaction followed. The transfusion was supplemented by external application of heat with water bags placed over epigastrium and at the extremities. Patient was very restless, and tossed the arms about a great deal, complaining of intense thirst. This was in a measure alleviated by cracked ice and seltzer, with milk and whiskey. At 2 A.M. there was another period of cardiac weakness, although not of such an alarming nature as the two already recorded, and the house surgeon injected six ounces of hot normal saline solution into the rectum with a Davidson syringe. Again the heart responded vigorously, and there was no further occasion for intra-venous stimulation. The symptoms of shock grew gradually less pronounced, and at 9 A.M. she was resting quite comfortably, with occasional fitful moments of sleep, and temperature 99.2°, pulse 120, respiration 30.

During the night the house surgeon had administered morph. sulph. gr. ¼ hypodermically, to relieve the pain in the neck, of which she constantly complained.

The condition of patient for the twenty-four hours ensuing after operation was satisfactory. The highest temperature, pulse, and respiration were 100⅝°, pulse 120, respiration 32. The lowest temperature, pulse, and respiration were 99.2° F., pulse 116, respiration 30, and the chief difficulty was to induce her to take a sufficient amount of nourishment with stimulant, and milk had to be chiefly relied upon, for she refused broths of chicken, beef, mutton, etc., and took the whiskey and brandy with reluctance.

The end of the second twenty-four hours found her in excellent condition, and her

highest	101⅝° F.	124	32
and	temperature, pulse, and respiration were		
lowest	100.2° F.	120	30

At this time, forty-eight hours after operation, the wounds in head and neck were first dressed. The packing in the opening in the skull was removed until the two strips which had been introduced into the sinus were encountered. These were readily recognized by knots which had been tied in the end. The strip of gauze which had been crowded into the jugular bulb, where the odor was so offensive, upon removal was absolutely free of all odor except that of its medicament—iodoform—and a stream of water forced into this cavity returned entirely clear and odorless. The gauze packing in the distal end of the sinus from which bleeding might be expected was not removed, but was thoroughly irrigated with bichloride of mercury 1:5000. The wound was then repacked with iodoform gauze and the neck dressed.

During the succeeding forty-eight hours, patient showed continued improvement, and her strength appeared on the increase. Although she had no appetite, she had not vomited food or medicine; bowels were constipated, and urine scanty. Infusion of digitalis was given, with but slight increase of the function of the kidneys. During this period the

highest	101.4° F.	124	32
and	temperature, pulse, and respiration were		
lowest	99° F.	80	28

At the end of four days, ninety-six hours after the operation, all the dressing of the wounds was removed, and the packing pulled out of the distal extremity of the sinus opening. This was

performed with great care and the least possible force, the gauze being thoroughly soaked with bichloride of mercury solution 1:5000. Upon its removal there was no bleeding, and the gaping lumen of the vessel showed that the walls of the sinus had been tightly approximated about ½" above the opening, by the combined pressure of the cerebellum behind and the cerebrum in front, which the added force of the gauze packing and bandaging had supplemented. The opening in the sinus was in contour like a four-sided pyramid, each of whose faces was convex. At its apex the walls were firmly agglutinated, and resisted the pressure from the torcular.

The scalp and that portion of the wound in the neck which had been stitched united by first intention, and as there were no signs of suppuration about any of the sutures, they were left in position.

The patient had been passing but a small amount of urine, and infusion of digitalis was ordered in half-ounce doses every three hours, which administration was continued for eight doses without any appreciable effect in increasing the flow of urine, which was still scanty, but with apparent cumulative effect upon the heart, whose action became slower and irregular with intermissions, the rate being about seventy-six. There was, however, no violent thrashing about of the heart to be felt on laying the hand over the precordium. So restless did the patient appear at this time, the end of the fifth day after operation, that I decided, in view of the excellent effect of the previous transfusions, to once more resort to this measure, and three hundred cubic centimetres of normal saline solution, temperature 105° in the reservoir, was introduced into the circulation through the median cephalic vein of the right arm. The effect was immediately noticed in the increased volume and steadiness of the pulse; the intermission, which, before transfusion, occurred with every fourth or fifth beat, could now be felt but once or twice in the minute, and although the pulse became more rapid, 120 to the minute, it was of a decidedly more satisfactory character. The digitalis was discontinued, and liquor potassi citratis ordered in half-ounce doses every three hours, with as much water as the patient could be induced to swallow.

One hour after the transfusion patient had a violent chill lasting twenty minutes, and her temperature immediately rose to 103° F., pulse 135, shortly subsiding again to 100° F., pulse 116. Fear

was entertained lest this chill might be a premonitory symptom of the formation of an abscess or a beginning septic pneumonia or enteritis, but during the following three days patient continued to improve, her temperature range being from 98.6° to 101.2° F., and pulse about 80. The force and rhythm of the pulse improved, but there was still frequent intermission, and she was put upon strych. sulph. gr. $\frac{1}{30}$ three times daily, and quinia sulph. gr. 2 three times daily. Under this treatment her improvement was decided. The amount of urine increased, she appeared stronger, and expressed a desire to eat something other than fluid diet.

On the tenth day patient complained of pain in the head just at the vertex. Nothing was seen, and an ice-cap was applied. On the next day there was œdema and deep fluctuation and swelling, and on the twelfth day an extra-periosteal abscess of the scalp was opened just over the superior occipital region, eight ounces of pus evacuated, and temperature, which had been 102° F., dropped to 99.4° F. Patient experienced relief of pain and seemed strong and cheerful during the ensuing three days, including the fifteenth. Patient's condition was exceedingly favorable, temperature averaging about 99.6° F. She took plenty of nourishment and enjoyed it. All the wounds of neck and scalp look well.

On January 9th, the eighteenth day after the operation, the temperature, pulse, and respiration were normal. Patient was allowed to sit up in bed, and on the twentieth day to sit in a chair beside the bed; since then her progress toward convalescence has been uneventful.

The report of the pathologists, Drs. Weeks and Dixon, upon the tissues presented to them, which consisted of the resected jugular vein, the clot expelled from the proximal end of the jugular, and the muscular tissue clipped from the sterno-mastoid along the course of the vein, shows that all these structures were swarming with strepto-, staphylo-, and diplo-cocci; especially well do the coats of the vessel wall show the invasion. It is difficult to say which of these micro-organisms predominated, as all were abundant. It is the opinion of Dr. Weeks that the streptococci are in excess of the others.

The features of especial interest in this case are several, the foremost of which, to the writer, is *whether the wounding of the sinus at the mastoid operation was the source of infec-*

tion which resulted in the subsequent thrombosis. This I beg to question, not with any desire of avoiding my responsibilities in the matter, for the mastoid operation was performed with the greatest possible care, and my conscience does not accuse me of having neglected any precaution which could insure a successful result, but because the outcome was so unexpected and so contrary to ordinary experience that I am loath to accept it as a criterion of the dangers to be apprehended from pricking the sinus; the injury was a minute puncture from a spicula of bone. The same accident has transpired at my hands several times before, but hitherto without subsequent complications. Another reason why I doubt the agency of the puncture in producing the thrombus is that the girl had her most severe pain in the anterior aspect of the mastoid tip, where upon opening the process the structure was normal and free from pus. Again, when the sinus was opened at the second operation, there was no clot in it until at ½" below the point of injury, while the disintegrated clot was deep down in the bulb and in the jugular.

The next most interesting feature was *the infiltration of the neck and the agglutination of the cellular structures about the collapsed jugular*, making it exceedingly difficult to find the latter, a fact which Schwartze notes as an argument against the operation, and which Mackin substantiates in a reported case where no trace of the vein could be found.

The extent of the purulent disintegration as far down as the omo-hyoid muscle, and the very small fibrinous clot which separated it from the blood circulating in the vein below, show that had the operation been long delayed, or the ligation omitted, the patient must have speedily died.

The rapid and satisfactory action of the venous infusion immediately upon finishing the operation, and again four hours later, as a stimulant to the heart action, depressed by the shock of operation, is worthy of note, and the apparently unfavorable action of the infusion four days later, which was followed by a chill, caused, it seems to me, probably by using the normal saline solution at too low a temperature—105° in the reservoir. Except for this unpleasant effect the

infusion, in my brief experience, has proved most beneficial. Hare mentions in his work that intra-venous infusion is frequently followed by a chill, but does not offer any explanation.

The re-established circulation from the torcular is preferably controlled by a wad of gauze packed firmly upon the open vessel and not thrust into it; when supplemented with a tight bandage it is thoroughly efficient, and relieves one of the embarrassment of subsequent bleeding which follows the removal of a plug from the lumen of the vessel. In the bulbous portion the return circulation is better controlled by packing gauze into the vessel, for the crooked bulb clots firmly and rapidly, and removal of the gauze seldom excites hemorrhage.

The fact that the patient has suffered from but one metastatic abscess is accounted for by the low degree of toxæmia which she experienced up to the time of operation, and by the ligation and resection of the infective jugular. The facial vein at its junction with the jugular was occluded and insignificantly small. It was simply divided without tying. The neuro-retinitis is subsiding, and this case can go upon record as one of recovery after intra-ocular involvement. Kipp found that of such cases the percentage of recovery was about 50.

In this case also, as in the preceding one, every hyperdermic injection resulted in a larger or smaller abscess.

A RETROSPECT OF THESE THREE CASES furnishes several phenomena which are worthy of consideration; one of these is the fact that excessive vomiting, which has generally been accepted as strongly indicative of meningitis and very unfavorable as to prognosis, was present in Cases 1 and 2 for several days preceding operation, and yet neither of them vomited a single time after operation, and neither suffered from meningitis other than the localized irritation about the sinus.

Another interesting fact is the repeated appearance of peripheral metastases after a ligation of the jugular has closed the avenue of approach to the lungs; this is the ex-

perience of many other operators, and is frequently reported.

Another matter which appears to me of the greatest moment, is the decision of the question whether tenderness along the anterior border of the sterno-cleido-mastoid muscle, which we are accustomed to consider as almost positive proof of jugular phlebitis, may be simulated by inflammation of the deep lymphatics? It is my belief that sufficient involvement of the deep lymphatics and lymphnodes takes place in the neck to cause tenderness along the course of the jugular only when that vessel is already the seat of infective phlebitis, and probably not then, until purulent disintegration has supervened in the clot occupying that portion of the vein which lies in close proximity to these lymphatics. It is, hence, a most hazardous expedient to delay the ligation of the jugular in cases having such tenderness upon the supposition that it may possibly be due to glands inflamed by extension from a remote septic focus somewhere above, rather than from an infective centre immediately at hand at the sensitive point in the neck. In the second case reported, although the clot extended in the jugular below the clavicle, and the walls of the vein were much thickened, showing the presence of phlebitis, and the patient complained of marked tenderness upon manipulation in this locality, there was not one inflamed gland found! The case reported by Dench, where a sudden chill and high temperature, with tenderness in the neck, occurred subsequent to operation upon the sinus as the result of a suppurative tonsilitis, is a most unusual complication, and should put one on his guard against being misled.

When the jugular has been tied in two places, resect it; healing of the wound in the neck is much more rapid and satisfactory, while if you simply divide the vein between the ligatures in case it is inflamed, some portion of it is nearly certain to suppurate and retard the healing, as in the second case.

Sinus phlebitis is a disease of adult life and occurs with greatest frequency between the ages of twenty and forty. Men, rather than women, are its victims in the proportion of

70% and 30%. The right side is more commonly involved, as might be expected from the structural peculiarities of the right temporal bone. Up to the present time and including my cases, the literature contains, so far as I can learn, 132 cases of sinus thrombosis which have been operated upon; in addition to this number there have been reported at the New York Otological Society and elsewhere, but not as yet published by the operators, 7 additional cases from Drs. Bacon, McKernon, Adams, Clements, and Gruening, a total of 139. Of these, 95 terminated in recovery and 44 in death.

Hessler found that of 54 cases of sinus opened and cleansed, 31 recovered, 57.4%; 23 died, 42.6%. And of 23 cases where the jugular was simultaneously tied, 16 recovered, 69.6%, and 7 died, 30.4%.

Körner found by sinus operation only, 50% death and recovery, and by simultaneous jugular ligation, 75% recovery and 25% death.

Forselles found by operation upon the sinus only 53.8% recovery and 46.2% death, and by simultaneous ligation of jugular, 62.5% recovery and 37.5% death; which signifies that in all cases with and without metastases the percentage of recovery with jugular ligation is 9% better than without.

Hessler's table of operations after the appearance of metastases shows that of 29 such cases, 12 recovered and 17 died. Of the 12 recoveries, 10 were made after jugular ligation; of the 17 deaths, 10 were without ligation, and 7 with.

In his table of cases without metastases the results are much more favorable. Of 30 cases operated, 24 recovered and 6 died. Of the 24 recoveries, 11 were with jugular ligation, and 13 without. Of the 6 deaths, 3 died with, and 3 without ligation.

The *indications for jugular ligation* in thrombosis of the sigmoid sinus may be summarized as follows:

First.—The indications which justify an operator in ligating the jugular before exposing the sinus should be very decided and as follows:

A. The existence of chronic otorrhœa.

B. Pronounced manifestations of pyo-septicæmia, high fever, sudden remissions, and repeated rigors.

C. Metastases.

D. Griesinger's symptom, occipital œdema.

E. Œdema of eyelids of corresponding side.

F. Tenderness along the course of the jugular in the neck, and perhaps the cord-like feeling of the infected vein.

G. Beginning neuro-retinitis.

A majority of these symptoms should be present.

Second.—The *indications for ligation after exposing the sinus* and *recognizing the thrombus*, but *before opening* it:

A. The presence of a clot extending well down into the bulb and disintegrated in its lower portion (as indicated by aspirator), associated with distinct pyæmic symptoms, although metastases are absent.

B. The display by the sinus of respiratory movements would render probable the admission of aërial embolism to the heart unless the vein were first tied; such movement in the sinus wall indicates the presence of a clot somewhat back toward the torcular from the point where the aspiration takes place, and has been noted by Jansen, Schwartze, and Körner, while sudden and fatal asphyxia from aërial embolism of sinus has been reported by Kuhn—ARCHIV. OTOL., vol. xxvi., No. 1.

Third.—Indications for ligation after exposing and opening the sinus:

A. The presence of a large thrombus, extending down into the bulb, and having undergone purulent liquefaction in the deep bulbous portion, which may not have been diagnosed until the sinus was extensively opened; the curetting deeply in the neck under such conditions is fraught with imminent risk to the patient unless the vein is tied.

B. Inability to re-establish the circulation from below, whether the clot has or has not disintegrated, and whether or not there has been tenderness in the neck.

C. Inability to re-establish the circulation from either direction has aroused some discussion as to the advisability of ligating both jugulars, but I cannot find that any serious consideration has been devoted to this proposition.

The practice of placing the nozzle of the syringe in the divided end of the jugular near the bulb and washing the con-

tents forcibly upward and out of the opening in the sinus wall may be a cause of serious complications, for if the visceral layer of the wall is softened the injected fluid may rupture it and pass into the subdural or subarachnoid spaces, distributing infective matter as it goes.

A perusal of the literature of sinus thrombosis must, it seems to the writer, convince everyone of the value of jugular ligation as a safeguard against metastatic involvement of the lungs and other organs, and it appears that the additional shock to the patient incident upon such operation, when rapidly and skilfully performed, is not of sufficient moment, when weighed against the proportionately increased immunity thus afforded from general infection, to constitute a valid objection to the procedure.

The study of intracranial infective diseases possesses an irresistible fascination for the physician; its unfaltering strides of progress constitute a surgical triumph; it has with one stroke changed the invariable prognosis of pyæmic thrombosis of the sigmoid sinus and jugular from hopeless fatality to expectant success. Could the energies of the profession possibly be directed toward a more beneficent attainment?

SYSTEMATIC REPORT ON THE PROGRESS OF OTOLOGY IN THE SECOND QUARTER OF THE YEAR 1897.

COMPILED BY DR. A. HARTMANN.

Translated by Dr. ARNOLD H. KNAPP.

PHYSIOLOGY OF THE EAR.

119. CYON, E. VON, Bogengänge u. Raumsinn. Semicircular canals and sense of space. An experimental and critical investigation. *Arch. f. Anat. and Physiol.* Physiol. Abtheilung., Heft 1 u. 2, 1897, S. 29–111.

119. This important paper of CYON deserves to be read by every aurist. The author has repeated, verified, or refuted, for more than twenty years, all the manifold experiments on the semicircular canals as the terminal apparatus of the organ of the "sense of space." The present paper is a comprehensive critical review of the experiments and opinions of the principal investigators of this subject. Mach was the first to declare the semicircular canals to be the sense-organ for the position of the head, the equilibrium, the rotatory vertigo, the sensations of stability and accelerated motion, etc. Cyon proved the futility of this hypothesis by experiments made twenty years ago, namely, by demonstrating the continuance of these sensations after division of both acoustic nerves. Mach withdrew his hypothesis, but Breuer, Ewald, Kreidl, and others still adhere to it. For details we have to refer the reader to the original.

GENERAL.

a.—REPORTS AND GENERAL COMMUNICATIONS.

120. GARBINI, G. Statistical and clinical report of the ear, nose, and throat clinic in Rome for 1894–96. *Archivio ital. d'otologia*, etc., vol. v., p. 34.

121. GRUNERT and LEUTERT. Annual report of the university ear-clinic in Halle a. S. from April 1, 1894, to April 1 1895. *Arch. f. Ohrenheilk.*, vol. xlii., p. 233.

122. KRETSCHMANN. Report of clinic for 1896. *Arch. f. Ohrenheilk.*, 1897, vol. xlii., p. 277.

123. MORPURGO, E. Statistical study on the diseases of the ear in scrofulous subjects and the effects of sea-baths thereon. *Archivio ital. di otologia*, vol. v., p. 113.

124. SEMON, F., London. De republica laryngologica. *Arch. f. Laryngol.*, vol. v.

120. The number of ear cases was 1643, of nose and throat cases 1143. The traumatic injuries of the membrana tympani, and the malignant tumors of the naso-pharynx and the nose, deserve especial mention. A larger number of the purulent middle-ear inflammations were examined bacteriologically.

GRADENIGO.

121. The careful report of the fatal cases should be read in the original. BLOCH.

122. In addition to the histories of a number of operative cases, KRETSCHMANN relates his satisfactory experiences with glutol-Schleich as a surgical dressing. BLOCH.

123. Against the opinions of various authors that cold sea-baths have a dangerous influence on the ear, MORPURGO thinks that sea-baths have a beneficent action on the aural affections of the scrofulous, especially on catarrhal conditions. Eighty-one of 195 individuals in the Marine Hospital at Trieste have changes in the ears, and the hearing of 105 of 390 persons was not normal. After a course of sea-baths, 77 of 188 patients showed improved hearing power, and a number of purulent otitides were improved. GRADENIGO.

124. FELIX SEMON, in an erudite essay on laryngological literature, comments on the literary peculiarities of various nations, on the fight for priority, on reviews, and on the relation of the special branches to general medicine. His remarks should be of interest not only to the laryngologist, but in great part to all those engaged in literary medicine. ZARNIKO.

b.—GENERAL SYMPTOMATOLOGY AND PATHOLOGY OF THE EAR.

125. BARR, J. Giddiness and staggering in ear disease. *British Med. Journal*, May 1, 1897.

126. CAPEDER, C. J. On diplacusis binauralis. *Inaug. Diss.*, Bale, 1895.

127. MINGAZZINI, G. Hysterical deaf-mutism. *Archivio ital. di otologia*, etc., vol. v., p. 145.

128. ALT, HELLER, MAYER, and VON SCHRÖTTER. Pathology of ear disease due to compressed air. *Monatschr. f. Ohrenheilk.* No. 6, xix.

129. SIMMONDS, M. On changes in the kidneys of atrophic babies. *Deutsches Archif f. klin. Medizin*, vol. 56, xix.

125. This paper is a continuation of one published by BARR in the *British Medical Journal*, December 28, 1895. He considers in this paper middle-ear giddiness, and contrasts it with labyrinthine giddiness, due to excessive air pressure, syringing, pressure of inflammatory products, and extension of purulent disease to the cranial contents. After dealing with giddiness due to syringing, he alludes to the danger of patients with a perforation in bathing; and thinks that giddiness produced by the rush of water through the perforation into the middle ear is probably responsible for the death of even expert swimmers. The paper is an exceedingly interesting one. ARTHUR CHEATLE.

126. CAPEDER has analyzed a number of the 19 cases of diplacusis which he has collected from literature, and adds the careful examination of 5 further cases occurring in Siebenmann's practice. Capeder believes that the cause of the diplacusis is to be found in affections of the middle ear. Of 20 cases with definite statements as to the causative disease, only 5 were free from middle-ear trouble; in 4 cases only was the diplacusis present on the bone-conduction of the tone. In a number of cases, including 3 of Siebenmann's, the diplacusis promptly subsided on the cure of the middle-ear trouble. In one case (Case 2) of bilateral nervous deafness, the phenomenon occurred occasionally in the side where the middle ear was affected. The appearance of diplacusis in anomalies of tension is also proven. Capeder does not contest the possibility of a labyrinthine origin, but does not believe it to be essential. KÜMMEL.

127. MINGAZZINI reports the case of a soldier, twenty years old, with previous nervous symptoms. The patient suddenly became deaf-mute; he could not speak nor read a letter. The mobility of the tongue was very restricted. Gradual recovery with the use of the faradic current. GRADENIGO.

128. These investigations were made in the caisson-works in Nussdorf, near Vienna. The relations in the case of divers and aëronauts were also studied. In increased air-tension, symptoms readily appear in normal ears unless by swallowing and Valsalva's experiment the atmospheric pressure without and within the tympanum is rapidly adjusted, or the increase in pressure is too sudden. The symptoms consist in the sensation of a retraction of the drum membrane and various noises in the ear. The vessels of the malleus are injected, or the drum membrane is slightly red; both appearances disappear on the pressure becoming constant. Hearing is somewhat diminished; the voice has a peculiar nasal metallic timbre. After diminution of the pressure, the ear feels easier, there are more noises, and the ear is hyposensitive. Patients with perforation of the membrana tympani are insensitive to changes of pressure.

Pathological changes occur after altered air-pressure from two causes: the inadjustable pressure-difference without and within the ear, and gas-emboli, due to too rapid diminution of pressure. If the pressure in the middle ear is negative, the drum membrane retracts, the blood-vessels become congested, and congestive hyperæmia ensues, with involvement of the Eustachian tube and the labyrinth. Transudates and hemorrhages result. Tubal closure and too rapid increase of pressure cause these changes. The membrana tympani may rupture and become inflamed in specially unfavorable circumstances. A stationary increase of pressure need not cause further symptoms. Too rapid diminution of pressure may likewise produce congestion, hemorrhages, and ruptures of the drum membranes. Gas-emboli occur after too rapid reduction of pressure, and produces the severest changes. In increased pressure, the gas is taken up by the blood in the lungs in large quantities, and then, on pressure-decrease, given off within the vessels, causing the gas bubbles to occlude the smaller vessels and capillaries. The severe disturbances in the functions of the nervous system, heart, lungs, and other organs can thus be explained. With regard to hearing, the central acoustic tract, the auditory nerve and its terminations, may suffer. An increase in arterial pressure gradually takes place owing to the numerous interferences with the circulation after reduction of pressure, and may also cause transudations and hemorrhages in the ear. The appearances from the gas-emboli occur after a space of from several minutes to hours, from the release, and take the form of

vertigo, tinnitus, vomiting, collapse, unconsciousness, Ménière's symptom-complex, and ataxia. If these symptoms disappear after hours or days, we may consider them to have been due to ischæmia. A persistent deafness is probably due to hemorrhages or necrosis of nervous auditory apparatus. The authors have pursued numerous experiments on animals, and have found, on histological examination, extensive changes of the above character in the labyrinth. KILLIAN.

129. SIMMONDS found more or less extensive degeneration of the kidney-parenchyma in all cases of nursing babes that had died of pædatrophia. He is inclined to consider this change in the kidneys in the majority of the cases to be secondary to an otitis media. All other causes seemed to him to be insufficient to produce the renal degeneration. The frequent presence of an otitis at autopsy of nursing children is emphasized (of 133 autopsies, the middle ear was found free from exudate in only 5 cases). Simmonds thinks that an inflammatory middle-ear infection is almost invariably present in atrophic babies. Of the 29 cases of this series of 60 where the ear was examined, in only one child with slight renal changes was the ear found unaffected. Eight cases were examined bacteriologically, and five times the same organism was found in the kidney and in the ear. The diplococcus pneumoniæ with the bac. pyocyaneus were found twice, the pneumococcus alone once, the bac. pyocyaneus with the staphylococcus albus once, and the pyocyaneus alone once. The author hence agrees with Kossel that the bacillus pyocyaneus, though usually benign for the adult, may be very dangerous for the child, especially during the nursing period.

WALTER HAENEL.

EXTERNAL EAR.

130. MCCARTHY, J. JUSTIN. Hematoma of the ear. Report of a case in which the staphylococcus pyogenes aureus was found. *Maryland Med. Jour.*, May 1, 1897.

131. RANDALL, B. ALEX. Fracture of the auditory meatus and the inferior maxilla from a fall on the chin. *Philadelphia Polyclinic*, May 29, 1897.

132. FRIEDENWALD, HARRY. An osteoma of the auditory canal, with report of the successful removal of a large exostosis by means of Swartze's operation of detaching the auricle. *Annals of Otol., Rhinol., and Laryngol.*, Feb., 1897.

133. RONCALI, D. V. Sarcoma of the auricle. *Arch. di otologia*, etc., vol. v., p. 513.

134. LANGE, VICTOR. On the diagnosis of perforations of the membrana tympani. *Therap. Monatshefte*, vol. iv., 1897, p. 211.

135. KÖBEL. Injuries of the membrana tympani, and their medico-legal aspect. *Festschrift des Stuttgarter ärtzl. Vereins*, Stuttgart, 1897, p. 410.

136. HUMMEL. On foreign bodies in the ear-canal, and their extraction by the general practitioner. *Münch. med. Wochenschr.*, No. 17, 1897.

137. BARNICK, O. The permanent closure of perforations with healed edges of the drum-membrane. *Arch. f. Ohrenheilk.*, 1897, vol. ii., p. 265.

130. The case reported was that of a patient who had organic dementia, and who developed ear symptoms two weeks previously, viz., a hematoma of the left ear. Before incising the tumor, two culture tubes, one of agar and the other of gelatine, were secured, and stab cultures were made from the deep recess of the opened wound immediately after the tumor was cut. It was proved by microscopical examination that the staphylococcus pyogenes aureus was present. GORHAM BACON.

131. RANDALL'S case was that of a man, thirty-two years old, who fell a distance of fifteen feet, striking upon the chin. Bleeding followed from the right ear, the nose, and the mouth. There was fracture of the ramus of the jaw on the right side, and, later, a serous discharge from the ear. There was extreme deafness. An examination of the ear showed a ruptured drumhead, with polypus. There was a marked bony protrusion of the anterior wall of the meatus, which was probably due to the crushing inward of the thin front wall of the meatus through the impact of the jaw condyle. The case was cured as to the discharge, and the hearing was almost completely restored. There remained, however, a perforation, as well as some narrowing of the bony meatus. GORHAM BACON.

132. The osteoma occurred in a woman, sixty-six years of age. The hearing was almost entirely lost. A hard, whitish tumor was found to entirely occlude the canal. There was considerable pain. The growth was removed with a chisel after detaching the auricle. The patient made a good recovery.

GORHAM BACON.

133. RONCALI describes a melanotic sarcoma in a man sixty-four years old, which started at the root of the zygomatic arch; the histological changes are carefully explained and the literature on the subject is reviewed. GRADENIGO.

134. The tube of a vapor-inhaling apparatus is connected with the ear; the patient performs Valsalva's experiment, if a perforation is present the vapor is seen to rise from the glass vessel. MANASSE.

135. KÖBEL reviews the various ways in which the drum membrane is injured. A worm raised in vomiting in a girl fifteen months old was observed to pass through the Eustachian tube and through a previously existing perforation of the drum membrane. Two cases of rupture of membrana tympani without involvement of the labyrinth during work in a caisson. The rapid withdrawal of the moistened finger introduced in the ear canal has produced rupture of *Mt.* Köbel gives no new aids in diagnosis, and mentions the diagnostic value of a blowing sound after air-douche. Of 50 recent ruptures after a box on the ears, 13 occurred on the right side, 37 on the left; in 32 the rupture was in the lower half. HUMMEL.

136. HUMMEL relates a number of cases where the foreign body remained in the canal for years without causing any reaction, and warns against extraction with instruments at the hands of untrained physicians. SCHEIBE.

137. The closure was brought about according to Okuneff's method with trichlor-acetic acid; a considerable improvement in hearing resulted. The cauterizations were made weekly, and were repeated two to fourteen times. BLOCH.

MIDDLE EAR.

a.—ACUTE OTITIS MEDIA.

138. DALBY, SIR WILLIAM. A note as to which incision of the tympanic membrane should be performed in acute inflammation of the middle ear. *British Med. Jour.*, July 24, 1897.

139. PRITCHARD, URBAN. Two cases of Bezold's perforation. *King's College Hospital Reports*, vol. iii., 1895–6.

140. MARSH, J. H. Acute suppurative middle-ear disease in infancy. *British Med. Jour.*, July 24, 1897.

141. CHINCINI, G. On Wilde's incision. *Arch. ital. di otol.*, etc., vol. v., p. 225.

138. SIR WILLIAM DALBY deals chiefly with acute middle-ear inflammation in infancy, and points out that the real difficulty lies in deciding as to when the incision should be made, for "the physical appearances in the membrane are usually of no help in these cases, for they are often absent, and as frequently as not the most that can be seen to be abnormal are the appearances showing a closed Eustachian tube and perhaps some congestion of the vessels," the chief evidence being the constitutional symptoms and the demeanor of the little patient, such as screaming, the turning about of the head, the sleeplessness, and the general illness. If leeches and hot fomentations do not cut short the inflammation at once, the vertical incision in the posterior section of the membrane should be made. In adults the diagnosis is of course easy. He states, in passing, that an opening made in a membrane which has a sodden appearance, and through which the knife cuts as if passing through soaked blotting-paper, frequently remains permanently open, or at any rate remains for a long period. CHEATLE.

139. Two cases of Bezold's perforation occurred in PRITCHARD's hospital clinic during the year. Recovery after operation occurred in both cases. CHEATLE.

140. MARSH relates four cases of acute suppurative middle-ear disease in young infants all under six months of age.

In two, Shrapnell's membrane was involved, facial paralysis being present in one of them, necessitating the opening of the antrum.

In the other two the perforation, pin-hole in type, was situated below and behind the handle of the malleus; in one of these the disease was bilateral.

In two of the cases the abdomen had been carefully poulticed and teething powders administered under medical directions. One case simulated acute meningitis, and in the other no treatment had been applied to the ear until the child was brought suffering from complete unilateral facial paralysis.

The early symptoms which should suggest the ear as the cause of the illness are:

1. The child constantly endeavors to rub the affected ear.

2. It utters a sharp cry of pain on pressure being made below the meatus.

3. It refuses to rest its head on the affected side.

141. CHINCINI is opposed to the abandonment of Wilde's in-

cision. He thinks it of value, especially in those cases where it is uncertain that the mastoid contains pus. GRADENIGO.

b.—CHRONIC OTITIS MEDIA.

142. PRITCHARD, URBAN. Chronic middle-ear suppuration; severe rigor due to pus in the antrum; recovery. *King's College Hospital Reports*, vol. iii., 1895–6.

143. BRAQUEHAYE. Cholesteatoma of the left mastoid antrum; operation; recovery. *Arch. internat. de lar., d'ot.*, etc., No. 2, 1897.

144. ZERONI. On cholesteatoma in an aural polyp. *Arch. f. Ohrenheilk.*, vol. xlii., p. 188.

145. DONALIES. Histology and pathology of the malleus and incus. *Arch. f. Ohrenheilk.*, vol. xlii., p. 226.

146. MOURE. The free exposure of the middle ear and its adnexa. *Revue hebdom. de laryng., d'otol.*, etc., 18, 19, 20, 1897.

147. GELLÉ. Meningeal symptoms in the course of a chronic otitis; recovery after opening the mastoid. *Arch. internation. de laryng., d'ot.*, etc., No. 2, 1897.

142. A man, aged twenty-one years, came to PRITCHARD with a polypus in the left ear. As he complained of giddiness soon after removal, he was admitted on March 18, 1896, for observation. He then looked ill, but was not complaining of pain or giddiness; temperature normal; no sign of any trouble behind the ear; a perforation existed in the posterior-superior segment. On March 21st he had a severe rigor lasting fifteen minutes, the temperature running up to 105°. March 22d, the antrum was opened and found full of pus; nothing else abnormal. Recovery rapidly occurred. CHEATLE.

143. The only unusual feature of this case of cholesteatoma, healed with permanent retro-auricular opening, is the statement in the previous history of the patient that an incision had been made twenty times behind the ear, as the abscess continually re-formed. G. ZIMMERMANN.

144. ZERONI describes a polyp from the middle ear of a girl sixteen years old suffering from chronic otorrhœa. The polyp is covered with pavement epithelium, which sends deep and branching processes into the connective tissue, which often contains horny epithelial products. These the author regards as cholesteatomatous masses, incorrectly according to the reviewer.

Some of the cells in these processes show numerous mitotic figures. Giant-cells are found near the epidermal scales, presumably foreign-body giant-cells. MANASSE.

145. This is a description of the normal arrangement of compact bony substances, medullary spaces, and vascular distribution. The latter is regarded as very free, in agreement with other authors. In the carious resorption, the surrounding pus is not as important as the inflammation in the bones themselves. Spontaneous recovery of diseased ossicles is rather uncommon.

BLOCH.

146. MOURE presents the anatomy, indications, and technic for operations on the middle-ear spaces, in an attractive if not original manner. In one third of all his cases Moure found the antrum either dislodged or of abnormal size following the suppuration. The author considers the permanent posterior opening as unnecessary, and after removal of the membranous canal usually attaches the auricle directly to the posterior border of the wound. ZIMMERMANN.

147. A patient, forty years of age, with an old otorrhœa, suffered from intense headache, somnolence, and temperature 101°. GELLÉ, suspecting intracranial complications, opened the mastoid process down to the antrum ; the cerebral cavity was not exposed. The patient recovered.

c.—CEREBRAL COMPLICATIONS OF PURULENT OTITIS MEDIA.

148. POLI, C. Purulent otitis media ; cerebral symptoms ; exploratory craniotomy ; tubercle in left crus. *Archivio ital. di otologia*, etc., vol. v., p. 377.

149. BALLANCE, HAMILTON A. A case of abscess in the right temporal lobe with left-sided hemiplegia and hemianæsthesia, caused by pressure on the internal capsule and paralysis of the third nerve. *British Med. Jour.*, May 22, 1897.

150. AVOLEDO, P. On craniotomy in purulent ear affections. *Archivio ital. di otol.*, etc., vol. v., p. 127.

151. GRADENIGO. The operative technic in brain-abscess. *Archivio ital. di otologia*, etc., vol. v., p. 559.

152. GRADENIGO. Two cases of otogenous brain-abscess. *Ann. des mal. de l'or., du larynx*, etc., No. 4, 1897.

153. BRONNER, A. A case of abscess of the temporo-sphenoidal lobe, opened and drained through the osseous auditory meatus. *British Med. Jour.*, Aug. 21, 1897.

154. ROHRBACH, R. On softening of the brain after isolated ligation of the internal jugular vein. *Beiträge zur klin. Chirurgie*, vol. xvii., p. 32.

148. A child, eighteen months of age, was taken ill with bilateral purulent otitis media when ten months old; a sinus in the right mastoid resulted. Later, the left eye deviated out and up, with mydriasis and complete ptosis; right hemiplegia and anæsthesia; double papillitis; facial paralysis. The left mastoid process, on opening, contained pus. The examination of the temporal lobe and cerebellum from the mastoid opening proved negative. At autopsy, twelve days later, a solitary tubercle was found in the left crus, and a localized meningitis over the left frontal and parietal lobes. GRADENIGO.

149. BALLANCE believes that his case is the first one to be published where the paralysis was caused by pressure on the internal capsule. CHEATLE.

150. CASE 1. A girl, seventeen years old, right chronic otorrhœa with fever and headache. On the eighth day left-sided general and facial paresis; pain in right ear and mastoid region. At the operation an extradural abscess was found on the temporal lobe. Two days later, owing to persistence of fever, the skull was opened over auditory canal, and a cerebral abscess was found. Recovery.

CASE 2. A man, twenty-one years old, left-sided acute otitis, with mastoid involvement, after influenza. A sub-periosteal abscess was opened. Later, headache, fever, vomiting, delirium, and occasional diplopia. Rigidity of neck, œdema of left upper lid, third- and eighth-nerve paralysis right, no papillitis, then paralysis of bladder, and opisthotonus. Death four days later, after exploration of left temporal lobe had been attempted. At autopsy, purulent meningitis with exudate in the middle and posterior fossæ.

CASE 3. A boy, eleven years old, left chronic otitis, fever, general pain, then left facial paralysis and paresis of left lower extremity, rigidity of neck. At operation, mastoid contained pus; small perisinuous abscess, and abscess in left temporal lobe were found. Recovery.

CASE 4. Fourteen-year-old girl, left chronic otorrhœa, onset of fever, vertigo, tinnitus, headache, rigidity of neck, contracture of right arm. At operation on left temporal bone an extradural perisinuous abscess was opened. Recovery.

GRADENIGO.

151. GRADENIGO describes the combined opening through the tegmen tympani and the squama as the method for exposure of a temporal abscess, and relates a case where the opening was made above and in front of the bony ear-canal. The question of choice between the trocar and the knife in searching for the abscess, and whether the dura is first to be incised or not, depends on the certainty of finding pus. The after-treatment should consist in thorough cleansing and iodoform gauze drainage. GRADENIGO.

152. Optic neuritis and severe cerebral symptoms were present in both cases. The suppurative process had traversed the tegmen tympani. The cerebral cavity was exposed both from the middle ear and from the squama. Pus was found in one case in the third temporal convolution; in the other case a cavity 1 *cm* deep was found directly above this fistulous tract in the dura. Both cases recovered; in the second, after sequestration of most of the cochlea. ZIMMERMANN.

153. In BRONNER'S patient, a man twenty-eight years old, the cerebral cavity was opened by removing the upper wall of the osseous canal, and then chiselling through the root of the zygoma. The dura was incised and with Macewen's pus searcher, directed up and in, for one inch in the temporo-sphenoidal lobe, a large abscess was evacuated. The attic and neighboring mastoid cells were then curetted. A sufficiently large opening was made in the membranous canal to permit the insertion of a drainage tube as far as the abscess cavity. After three days, the tube ceased discharging, and the cerebral symptoms returned. The searcher was re-introduced and a fresh quantity of pus was evacuated. Uninterrupted recovery. Bronner believes that Browne of Belfast was the first to suggest this method. CHEATLE.

154. During the removal of metastatic glandular carcinoma in a woman, fifty-seven years old, the left internal jugular was ligated. The patient never recovered consciousness and died six days later. At the autopsy the cause for the circulatory disturbance in the brain was found to be an incomplete development of the right lateral sinus and the right int. jugular vein. This is the only case in ninety-one which the author has collected where the ligature was followed by fatal brain softening. HAENEL.

d.—MIDDLE-EAR EXTENSION.

155. WEISSBERGER. A successful case of sinus-thrombosis after middle-ear suppuration. *Deutsche med. Wochenschrift.*, No. 23, 1897.

156. CARLESS, ALBERT. Acute otitis-thrombosis of lateral sinus; operation; recovery. *King's College Hospital Reports*, vol. iii., 1896.

157. PRITCHARD, URBAN. Sub-acute ot. med. supp.; periostitis; papillitis. *King's College Hospital Reports*, vol. iii., 1895–6.

155. The patient, twenty years of age, was taken ill with an acute otitis media after angina. The inflammation abated somewhat until, on the tenth day, exacerbation of pain and fever set in, and four weeks later patient had a chill. On opening the mastoid, a little pus and granulations were found. Repeated chills. The internal jugular vein was ligated, the lateral sinus opened, and the purulent contents evacuated. Recovery then took place. NOLTENIUS.

156. CARLESS records a case of septic thrombosis of the lateral sinus secondary to acute ot. med. supp., recovery taking place after clearing out the antrum, mastoid cells, etc., and ligature of the internal jugular. CHEATLE.

157. The interest of this case lies in the presence of papillitis occurring during the course of a simple periostitis which cleared up after PRITCHARD had made a Wilde's incision. CHEATLE.

e.—OTHER AFFECTIONS OF THE MIDDLE EAR.

158. CHEATLE, ARTHUR. Operative interference in chronic middle-ear disease (not suppurative). *Practitioner*, May, 1897.

159. MOUNIER. Surgical treatment in non-suppurative middle-ear disease. *Arch. internat. de laryng., d'otol.*, etc., No. 3, 1897.

160. DE ROSSI. Contributions to the surgery of the middle ear. *Arch. ital. di otol.*, vol. v., p. 441.

158 CHEATLE has obtained the opinion of many of the leading aurists as to the value of intra-tympanic operations in chronic non-suppurative middle-ear disease; the conclusions he draws from them are certainly not very encouraging. CHEATLE.

159. In all cases where negative Rinné becomes positive after paracentesis, an improvement in the hearing may be promised after operation; in all other obstinate cases an operation may at least be tried. The operation consists in removal of the membrana tympani, and the hammer, the outer wall of the attic, and a portion of the posterior osseous wall are chiselled away from the auditory canal with aid of the author's protecting gouge. After the operation hearing for voice has been increased up to four-

fold. The number of operations and the patients' histories will be published later. ZIMMERMANN.

160. Observation of four cases of stapedectomy. The author claims that stapedectomy, as well as any operation on the ossicles, can be successfully performed by way of the auditory canal. The results are indecisive. GRADENIGO.

NERVOUS APPARATUS.

161. PRITCHARD, URBAN. Congenital syphilitic deafness; giddiness occurring at onset. *King's College Hospital Reports*, vol. iii., 1895–6.

161. A man aged twenty-eight years came to PRITCHARD with internal-ear deafness and signs of congenital syphilis, the history being that at the age of eighteen he became rapidly deaf during attacks of giddiness, becoming totally deaf in two months.

CHEATLE.

NOSE.

a.—GENERAL SYMPTOMATOLOGY AND PATHOLOGY.

162. FRÄNKEL, E. The relation of anomalies of the hard palate to deviations of the nasal septum and hypertrophy of the pharyngeal tonsil. *Inaug. Dissert.*, Bâle, 1896.

163. LENHARDT. Complete occlusion of the nares from cicatrices of tertiary syphilis. *Ann. des mal. de l'oreille, du larynx*, etc., No. 4, 1897.

162. FRÄNKEL reviews the opinions on the relation of the deformities of the jaws to the hypertrophy of the pharyngeal tonsils, and adds the results of his examination of a large number of patients on the position of the teeth, the breadth and height of the palatine vault, the position of the septum, and the presence of rachitic symptoms. Of these patients there was a deviation of the septum in 29, a hypertrophy of the pharyngeal tonsil in 60, and in 44 neither anomaly was present. The measurements were made with aid of Siebenmann's palatometer. The author concludes that deviations of the septum are a result of the unusual height of the palatine vault, and that the latter appears to stand in no relation to adenoids. Fränkel agrees with Siebenmann that abnormalities of the maxillæ are congenital, and, together with a narrow nose, predispose to enlargement of the pharyngeal tonsil. There seems to be no reason for the frequent association of both

abnormalities. The reviewer is disposed to coincide with Körner's views that the pharyngeal tonsillar hypertrophy causes the above-mentioned deformities. KÜMMEL.

163. The scars resulted from extensive ulceration of the alæ nasi, and had led to a complete occlusion ; in addition, a perforation of the septum had caused the point of the nose to curve and retract. Every effort at correction proved unsuccessful.

ZIMMERMANN.

b.—THERAPEUTICS OF DISEASES OF THE NOSE.

164. KATZENSTEIN. Direct inspection of the naso-pharynx. *Arch. f. Laryngol.*, vol. v.

165. JANKAU, L. A new method for vibratory massage of the nose. *Monatschr. f. Ohrenheilk.*, No. 5, 1897.

166. TAUSCH. The treatment of hay fever. *Münch. med. Wochenschr.*, No. 25, 1897.

167. FRÄNKEL, B. An application for the naso-pharynx. *Arch. f. Laryngol.*, vol. iv.

168. RETHI, L. Accidents after nasal operations. *Arch. f. Laryngol.*, vol. iv.

169. SÄNGER, M. A simple device to correct disturbance of speech caused by abnormal communications between the nasal passages and the buccal cavity. *Deutsche Zeitschr. f. Chirurgie*, vol. 44, xvi.

164. The patient is on his back, with head hanging over backwards, the tongue is drawn forward, the uvula and soft palate are slowly but steadily drawn forward and down, with a broad hook-like retractor, similar to Desmarres's lid-elevator. The posterior and lateral walls of the pharynx are thus successively brought into view. Tumors of the posterior wall can be operated on and catheterization be practised from the mouth under direct inspection. ZARNIKO.

165. In vibratory massage JANKAU uses a small rubber balloon which is introduced into the nose, and is connected with a "double balloon," or an electro-motor. The massage is applied for two minutes every other day. KILLIAN.

167. FRÄNKEL has modified Baginsky's applicator by giving it the curve of Gottstein's curette, and shows how application can be made to the naso-pharynx without annoyance to the patient.

KILLIAN.

168. RETHI removed a considerable number of œdematous fibromata from the nose of a man sixty-two years old, in five sittings. There was considerable hemorrhage, requiring plugging. On the sixth day headache set in, then somnolence; left pupil immovable, the right reacted slowly; paresis of right arm, and pain in elbow-joint; several red and infiltrated areas in the skin of the right leg and the right arm. The urine contained blood-casts, albumen, and methæmoglobin; moderate rise of temperature; normal pulse-rate. Death on eleventh day. The autopsy showed purulent meningitis of the convexity, thrombo-phlebitis of a pial vein, pyæmia with metastases. The nose and sphenoidal sinuses contained pus. ZARNIKO.

169. SÄNGER recommends his "nasal valves" where the usual obturators are insufficient. They consist of two oval tubes with a door at one end which opens only inwards, thus allowing, when in position, free inspiration and somewhat obstructed expiration. In a child with cleft palate articulation became distinct.

HAENEL.

c.—NASAL SEPTUM.

169 A. GOUGUENHEIM. Abscess of the septum. *Arch. f. Laryngol.*, vol. v.

170. SCHMIDT, M. Further experience in the treatment of irregularities of the septum with the electric saw. *Arch. f. Laryng.*, vol. v.

171. WALLCISEK, K. The bleeding polyp of the nasal septum. *Monatschr. f. Ohrenheilk.*, No. 4, 1897.

172. EGGER. On vascular tumors of the nasal septum. *Ann. des mal. de l'or., du lar.*, etc., No. 6, 1897.

169 A. GOUGUENHEIM has recently observed six further cases of abscess of the septum. Nothing new is mentioned but what is contained in the complete exposition of the subject by Fischenich and Küttner in *Arch. f. Laryng.*, vol. ii.

170. SCHMIDT again recommends the employment of electric trephines and saws. The operation is quickly done, and with plenty of cocaine is painless. Perforations of the septum cannot always be avoided. Occasional severe hemorrhage can always be checked with tamponade. The details should be read in the original. ZARNIKO.

171. WALLCISEK considers the bleeding polyp of the septum

to be a benign vascular connective-tissue growth which occurs usually in women, and is probably due to repeated mechanical irritation. KILLIAN.

172. EGGER's case is that of a woman, seventy-one years old, with a tumor completely filling the right nostril; repeated epistaxis during the six preceding weeks. The tumor was as large as a cherry, and attached far up and in front to the septum; microscopically, it was made up of newly formed blood-vessels. Egger calls it a hemorrhagic polyp. An exhaustive review of the literature is given. ZIMMERMANN.

d.—OTHER AFFECTIONS OF THE NOSE.

173. VEDOVA, D. DELLA. The differential diagnosis of chronic rhinitis and ozæna, and the treatment of the latter affection. *Archivio ital. di otologia*, vol. v., p. 169.

174. MOLINIÉ. There cases of ozæna cured by hypodermatic injections of Roux's serum. *Ann. des mal. de l'oreille, du larynx*, etc., No. 4, 1897.

175. GRADENIGO. The treatment of ozæna. *Ann. des mal. de l'oreille, du larynx*, No. 6, 1897.

173. The differential diagnosis rests upon the bacteriological examination of the secretion. The term rhinitis fœtida chronica atrophicans should only be applied to the disease caused by the pseudo-diphtheria bacillus; this organism is absent in other nasal affections. VEDOVA confirms the usefulness of the anti-diphtheritic serum. GRADENIGO.

174. Three cases of ozæna which had rebelled against treatment for a long time were cured after the injections of anti-diphtheritic serum; the atrophy even disappeared [!]. ZIMMERMANN.

175. GRADENIGO considers the anti-diphtheritic serum valueless in ozæna; he therefore has tried with success the intramuscular injections of iodine. ZIMMERMANN.

e.—NEW FORMATIONS IN THE NOSE.

176. MANASSE. Syphilitic granulomata of the septum and the origin of giant-cells therein. *Virchow's Archiv*, vol. cxlvii.

177. ROTHENAICHER. Clinical contributions. *Monatschr. f. Ohrenheilk.*, No. 4, 1897.

178. DOYEN. Extirpation of large naso-pharyngeal polypi through the natural passages. *Arch. internationales de laryng., d'otol.*, etc., No. 3, 1897.

176. MANASSE describes five peculiar growths of the nasal mucous membrane. They were reddish-gray, soft, with broad or narrow base, multiple or single, usually situated on the septum—at the border of a perforation,—also on the turbinates and the floor The tumors were connective-tissue growths, originating in the submucous tissue, and composed of old granulation tissue and giant-cells, showing tendency to undergo fibrous change and but little retrogressive metamorphosis. The histological diagnosis was confirmed by the clinical course. These growths are more sharply defined than gummata. The author regards the giant cells to be caused by proliferation of the endothelium of the small veins. HAENEL.

177. ROTHENAICHER reports the removal of an unusually large naso-pharyngeal polyp, and of a large rhinolith which had formed about a cherry-stone. KILLIAN.

178. DOYEN removed a large naso-pharyngeal polyp with extensions in the nasal and maxillary cavities through the mouth, by means of a suitable curved periosteal elevator, and operated so rapidly that the excessive hemorrhage was avoided. Doyen reports three cases operated on in this manner.

ZIMMERMANN.

f.—AFFECTIONS OF THE ACCESSORY CAVITIES.

179. SCHMIEGELOW. Acute osteomyelitis of the superior maxilla. *Arch. f. Laryng.*, vol. v.

180. KRONENBERG, E. Mucous polypi of the nose and empyema. *Therap. Monatshefte*, 1897, No. 5, p. 259, and No. 6, p. 316.

181. KREBS. Diagnostic puncture of the maxillary antrum. *Arch. f. Laryng.*, vol. iv.

182. SPIESS. A new method of treating empyemas of the accessory sinuses. *Arch. f. Laryng.*, vol. v.

183. LUC. A new radical cure for empyema of the maxillary antrum. *Arch. internat. de laryng., d'ot.*, etc., No. 3, 1897.

184. ARSLAN, Y. The so-called rhinitis caseosa. *Archivio ital. di otologia*, vol. v., p. 159.

185. MILLER, V. Ozæna, necrosis of the septum, ethmoiditis, cerebral complication, and death. *Brit. Med. Journ.*, April 18, 1897.

179. A child, ten weeks old, was suddenly taken ill with fever, convulsions, and a swelling over the right superior maxilla. Perforation above canine tooth with escape of pus; the tooth was then extracted. Fœtid discharge from the nose. Repeated irrigation was accompanied by great improvement, and every prospect for a cure. ZARNIKO.

180. KRONENBERG has examined forty-five cases to study the relation of mucous polypi and empyema of the accessory cavities. No abnormal discharge was present in 13 per cent. of the cases. Empyema was present in 6 per cent. Kronenberg thinks that very frequently the polypi are caused by the sinus affection, and that chronic catarrh may cause changes in the mucous membrane, polyp formation, and extension of the disease to the neighboring cavities. MANASSE.

181. Diagnostic punctures, with irrigation of the antrum of Highmore, is not always without danger, as an empyema may thus be set up. The puncture is preferably done in the middle meatus rather than the lower. Serous inflammation of the antrum is an actual disease, but does not warrant operative interference. ZARNIKO.

182. SPIESS has had considerable success in the treatment of obstinate forms of antrum empyema with the electro-chemical method. The flat electrode is placed on the outer side of the cavity, and a copper wire in a rubber tube is introduced into the cavity filled with a Nacl solution. The constant current is turned on to 15 m. a. for five minutes in one direction, and another five minutes in the opposite direction. ZARNIKO.

183. LUC makes an opening in the canine fossa, curettes the cavity, and then sutures the mucous membrane. Another opening is made into the lower meatus for drainage. Recovery in six weeks. ZIMMERMANN.

184. ARSLAN regards rhinitis caseosa as being caused by stagnation of pus from some cause or other. The streptothrix alba is not always present, hence loses its etiological significance. GRADENIGO.

185. A patient, eighteen years old, with ozæna, suddenly lost consciousness and had convulsions for one hour. After a second attack, the sight was lost. The sphenoidal sinus was opened. After a third attack, with coma, facial paralysis, and divergent strabismus, patient died. CHEATLE.

NASO-PHARYNX.

186. D'AGUANNO, A. Congenital closure of right choana. *Archivio ital. di otol.*, vol. v., p. 231.

187. GRANT, DUNDAS. Two cases of nasal obstruction from prominent cervical vertebræ. *The Medical Press*, June 2, 1897.

188. GOURC. Meyer's tonsil. *Ann. des mal. de l'or., du lar.*, etc., No. 5, 1897.

189. KAHN. Accident during the operative removal of adenoids. *Rev. hebdom.*, No. 14, 1897.

190. PRITCHARD, URBAN. Deafness and dumbness due to adenoids; removal; recovery. *King's College Hospital Reports*, vol. iii., 1895–6.

186. The closure was membranous, and was treated successfully with the galvano-cautery. GRADENIGO.

187. GRANT presented two cases of nasal obstruction due to lordosis of the cervical vertebræ at the meeting of the British Lar., Rhinol., and Otol. Society, on April 30, 1897. CHEATLE.

188. GOURC was not able to find the tubercle bacillus in 201 hypertrophied pharyngeal tonsils, neither did the tissue appear tuberculous under the microscope. Acute adenitis is accompanied by increased secretion, not with increase in volume. ZIMMERMANN.

189. In using Gottstein's curette, KAHN has encountered a bony process in four cases, which he regards as an exostosis of the tuberc. ant. atlantis. ZIMMERMANN.

190. After removal of a large mass of adenoids and repeated inflations in a deaf-mute child two and one half years old, hearing rapidly developed and speech commenced. CHEATLE.

VELUM, PHARYNX, AND ORAL CAVITY.

191. LEXER, E. The pharyngeal mucous membrane as site of entrance for pyogenic infection. *Arch. f. klinische Chirurgie*, vol. 54, xxxii.

192. FREUDENTHAL, W. Contribution on the etiology of pulmonary tuberculosis. *Arch. f. Laryng.*, vol. v.

193. SENDZIAK. An unusual case of aphthæ in the mouth, naso-pharynx, and larynx. *Arch. f. Laryng.*, vol. iv., 3.

194. PAKES, W. C. C. The bacillus of Friedländer in pharyngitis and tonsillitis. *British Med. Jour.*, March 20, 1897.

195. WEISSENSTEIN. Pharyngeal tuberculosis. *Festschr. d. Stuttgarter ärztl. Vereins*, 1897, p. 388.

196. HÖFER, W. Injection of carbolic acid in the treatment of acute tonsillitis. *Deutsches Archiv f. klin. Medicin*, vol. 57, xxiv.

197. LAW. Cleft palate, with enlarged tonsils and inferior turbinates, and an excessive quantity of adenoid growths. *Proceedings Laryngological Society*, June 9, 1897.

198. CLUTTON, H. H. A case of pharyngeal abscess followed by hemorrhage, and treated by ligature of the carotid arteries. *Lancet*, May 29, 1897.

199. CHAVASSE, T. F. Multiple lipomata of the tongue. *The Birmingham Medical Review*, January, 1897.

200. BATTLE, W. H. Excision of malignant tumor of tonsil. *The Med. Press*, Jan. 27, 1897.

201. HEATON, GEORGE. Excision of tonsil for malignant disease. *Brit. Med. Jour.*, Jan. 9, 1897.

202. SMITH, GREY, and HARSANT, W. H. Two cases of actinomycosis. *Lancet*, Jan. 30, 1897.

191. LEXER studied the relation of pharyngeal infection to general infection in the rabbit. The pharynx was swabbed with the bacterial growth. The most valuable results were obtained from streptococcus cultures. A general infection took place; the bacteria were found in a very short time in the internal organs and in the blood. The lymphatic system of the pharynx, and especially the tonsils, were unquestionably the places of entrance.

HAENEL.

192. FREUDENTHAL comes to the conclusion that the naso-pharyngeal catarrh is the foundation of pulmonary tuberculosis, inasmuch as the bacilli are deposited there, and there gain an easy access to the lymphatic tissue and glands. ZARNIKO.

193. In a patient fifteen years old, after an attack of diphtheria, the soft palate, pharynx, naso-pharynx, root of tongue, and larynx were covered with white spots and patches, which on examination proved to be aphthæ. Recovery in two months. ZARNIKO.

194. Since November, 1894, PAKES has made upwards of five hundred serum tube inoculations from the throats of patients. He found Friedländer's bacillus in five cases, in two of which a pure culture was obtained :

(1) A man aged thirty, who had had a sore throat for a few days; the fauces being red, with slight colorless exudation, and the tonsils red and swollen. No constitutional disturbance.

(2) A patient whose tonsils were red and swollen; with a few whitish plugs. Temp. 100.°

In two, the bacillus was found in association with the Klebs-Loeffler bacillus, both cases being children who had yellow plugs in both tonsils.

In one, in association with staphylococcus aureus, the patient being a man aged twenty, who had had a sore throat one week, the fauces being red and congested, with two or three whitish plugs in crypts of tonsils, but no membrane.

The morphological character and pathogenicity of the bacillus is then described. CHEATLE.

195. WEISSENSTEIN found tubercular changes in the pharynx of phthisical patients in the proportion of 1:300; the order of frequency was the tonsils, then the palatine arches, and the velum. In the differential diagnosis, the possible existence of syphilis, besides tuberculosis, must be kept in mind. In one, the pharyngeal affection was possibly primary. The treatment was local and general. KÜMMEL.

196. HÖFER recommends injections of 2–3 per cent. solution of carbolic acid in all anginas due to pyogenic bacteria. In abscesses, however, the method is useless. HAENEL.

197. Two children, a girl fifteen and a boy thirteen, brother and sister, were shown by LAW; each had been operated on during infancy for hare-lip. A broad cleft existed in the middle line through the hard and soft palates. The tonsils were enlarged and long, the inferior turbinates greatly hypertrophied, and the defective nasal septa were seen passing backwards to the posterior pharyngeal wall above, apparently through the adenoid masses. There was no complaint of regurgitation, difficulty in swallowing, or deafness, but articulate speech was most seriously impaired. CHEATLE.

198. CLUTTON's patient was a man aged twenty-eight years, who was admitted to St. Thomas's Hospital on June 20, 1896, for a "sore throat" and general pain. The day after admission he bled rather profusely from an abscess in the pharynx above the right tonsil. On June 24th, the soft palate was divided for the purpose of a complete examination of the abscess. A hole was found passing through the wall of the pharynx into the neck;

this opening was enlarged and the cavity plugged with cyanide gauze. During the night following the operation he bled so profusely that there could be no doubt that the hemorrhage came from a large artery, probably the internal carotid. On June 25th the bifurcation of the common carotid on the right side was exposed and a goldbeater's skin ligature applied to the common carotid and its two branches. Recovery. CHEATLE.

199. At a meeting of the Midland Medical Society, held November 25, 1896, CHAVASSE showed a man aged eighty-six years with multiple lipomata of the tongue, the largest being the size of a tangerine orange, which had been growing for twenty years.

CHEATLE.

200. A large tumor of the tonsil was removed by BATTLE from a man aged forty-eight years. The external carotid artery was ligated, and tracheotomy performed as preliminaries. The growth then removed by incising the cheek. A small gland in neck removed. CHEATLE.

201. At a meeting of the Birmingham and Midland Counties Branch of the British Medical Association, held on November 27, 1896, HEATON showed a man, aged sixty, on whom he had operated seven months previously. A horizontal incision carried backwards from the angle of the mouth enabled him to remove the left tonsil and anterior pillar of the fauces, the left half of the soft and hard palates, and the alveolar portions of both upper and lower jaws corresponding to the three molar teeth. The ramus of the lower jaw was removed on the left side to obtain free exposure. No recurrence. The patient wearing an obturator plate with a set of upper and lower false teeth, enabling him to swallow, and preventing regurgitation of food through the nose.

CHEATLE.

202. Two cases of buccal actinomycosis reported by SMITH and HARSANT: (1) a man who, two weeks after a piece of chaff had stuck in the floor of the mouth, developed a swelling below the jaw. An abscess formed, which, on being opened, was found to contain granules consisting of masses of ray fungus; (2) a man whose throat was pricked by a fine "spear" of wheat. A swelling formed below the jaw fourteen days later, and an ulcer was observed on the left anterior faucial pillar. The swelling incised and scraped; ray fungus found. Recovery in both cases.

CHEATLE.

REPORT ON THE SECTION FOR OTOLOGY AT THE XII. INTERNATIONAL MEDICAL CONGRESS, MOSCOW, AUGUST 19–26, 1897.

By Dr. Zwingmann (Kursk).

Translated by Dr. Arnold H. Knapp, New York.

After a few introductory remarks by Professor Stanislaus Von Stein the first session was called to order.

Dr. E. Ménière, in the chair.

Dr. Moure, Bordeaux, read the first paper on **Acute adenoiditis in adults.** The author has observed 156 cases of adenoids in adults varying in age from 15 to 55 years. They are frequently accompanied by inflammatory symptoms, and one of the most frequent predisposing factors is general exhaustion and weakness. Frequently this affection is secondary to an inflammation in the neighboring parts. Febrile disturbances are rarely observed. The main symptoms are interference with respiration and catarrh of the Eustachian tube and its sequelæ. The naso-pharynx is red, swollen, and contains muco-purulent secretion. The adenoid tissue may be situated on the posterior, the lateral, or the superior wall. A picture, similar to the angina lacunaris of the tonsils may be present. The walls of the ostium tubæ are swollen, and on otoscopic examination in the acute cases a catarrhal exudative otitis is observed; in the chronic cases a dry or adhesive catarrhal otitis.

The diagnosis is easily made with posterior rhinoscopy.

Treatment consists in fumigation of the naso-pharynx, and introduction of cocaine and boric ointment in the nose. Air douches and nasal irrigations are to be avoided. The operative

removal of the adenoid tissue causes cessation of all the symptoms. The bacteriological examination of one case showed the presence of Friedländer's bacillus and the staphylococcus albus.

Dr. A. HARTMANN, Berlin, followed with a paper on **The operative removal of adenoids with straight forceps under direct inspection.** In children during muscular contraction of the soft palate, the lower portion of the adenoid cushion is often directly visible. If the soft palate is drawn forward and up, a good survey is possible, and adenoid masses may thus be removed, during direct inspection.

HARTMANN prefers a straight forceps, because the lateral portions, especially those about Rosenmüller's fossa, can be better reached. The straight forceps cuts only in its upper, and upper and back part; in the lower part the edges gape. During the operation the naso-pharynx is first painted with a 5% cocaine solution, and a cocaine spray applied through the nose. With the use of a hook, the soft palate is pulled forward and up. The forceps are introduced twice. The hemorrhage is less than in the other procedures, and there is no danger of any of the adenoid masses finding their way into the larynx.

The title of Dr. HARTMANN's second paper was **The inflammation of the middle ear of nursing infants.** The author has shown that otitis occurs in the nursing babes in the hospital as frequently as it is found on the autopsy-table, hence deserves greater study in the living. The findings at autopsy, both microscopic and bacteriological, were carefully described. Aschoff has been able to find, in cases where plenty of pus was present in the middle ear, the traces of substances contained in the amniotic fluid. The otitis media of the new-born is to be regarded as a suppuration, set up by foreign bodies. The otitis media of the new-born and of sucklings is not the same disease; the first is non-infectious, while the latter is an infectious otitis.

The entrance of pyogenic substances into the tympanum is the factor in the otitis of nursing infants. This occurs either in acute coryza, broncho-pneumonia, or through the vomit in digestive disturbances.

The diagnosis of otitis media in infants was then discussed. The author draws attention to his previous publication on this subject, and states that Göppert, at the University Hospital for Children, has recently confirmed his results. The acute cases with alarming onset of symptoms are more frequently seen in the

hospital than in private practice. The symptoms are usually more moderate; restlessness, some fever, and digestive disturbances. The presence of an exudative otitis is frequently only found on the casual examination without any signs pointing directly to it.

The course of the disease is usually benign, though destruction of the drum-membrane, chronic otorrhœa, and carious processes may follow. A number of specimens in glycerine jelly were exhibited. Death occurs through consecutive nephritis, pyemia, and cerebral complications. Whether general atrophy is caused by the otitis or whether the atrophy is a predisposing factor in the otitis is still undecided.

The treatment is about the same as it would be for adults. In acute violent otitidis with persistent exudate, paracentesis must be performed. Carbol-glycerine may first be tried. Later air-insufflations may be practised. The general health of the patient of course must be sustained and the coryza and pharyngitis treated.

Discussion. POLITZER. No bacteria are to be found in the tympanum during uterine life. During the passage of the child through the vagina, the naso-pharynx may become infected, and a rapid extension of the infection into the tympanum takes place post mortem, as Chvostek has shown. The examination after death of new-born children is therefore not conclusive; the tympanum of still-born children should be examined immediately after birth.

JANSEN draws attention to the difficulty of examining the auditory canal because of the swelling of the posterior and superior wall of the canal, which occurs so quickly in infants.

HARTMANN recommended a rubber bag to cleanse the nose and a weak solution of cocaine in an atomizer in preference to irrigation.

VON STEIN prefers bougies of cocaine or menthol to be passed into the nose.

II. Session: August 20th, Afternoon.

Prof. BERTHOLD, presiding.

MÉNIÈRE.—**On the use of rubber bougies in chronic catarrhal affections of the Eustachian tube and the tympanum.**—Chronic inflammations of the Eustachian tube are the most frequent cause of gradually progressive loss of hearing. In these cases repeated insufflations of air often have no

effect, though sometimes a marked improvement is produced by passing the bougies. The elastic bougies are the only serviceable ones; the end must be conical, and pass through a catheter of 1½–2 *mm* breadth. The following solution is used: Iodine pure; iodide of potash, āā 1 gr.; dist. water, 13 gr. The bougie may remain in position from one to sixty minutes. The irritation is slight; occasionally burning in the naso-pharynx will be complained of.

Discussion.—RADZIG uses fish-bone bougies which have become supple after lying two to three hours in hot water.

COZZOLINO has had good results with the passing of bougies, but thinks that the nose and naso-pharynx should first be treated.

MOURE is of the same opinion.

HEIMANN has also had good results, but in a few cases after the use of bougies hearing became permanently worse.

POLITZER does not believe that his procedure and catheterization are ineffective; the tube usually becomes patent after several sittings. He has often observed increased deafness after treatment with bougies.

MÉNIÈRE has never observed deafness to have grown worse after employment of bougies The method is easy and without danger when no air is insufflated. He performs catheterization but rarely.

VON STEIN uses conical sounds, which are introduced but for a short distance in the tube, as the obstruction is usually at the pharyngeal ostium.

JANSEN is also of the opinion that the nose should first be treated, but only when symptoms referable to the nose, as obstruction or deviation, exist.

BERTHOLD remarks that too wide nasal passages are as unfavorable for breathing and ventilation of the tympanum as narrow ones, as is proven by the frequent complaint of patients with chronic ozæna of want of air.

Dr. A. HARTMANN, presiding.

Dr. JANSEN, Berlin, read a paper on **Meningitis serosa,** which will appear in these ARCHIVES.

Dr. RICARDO BOTEY, Barcelona.—**The treatment of attic and mastoid suppurations and their intracranial complications.**—In the acute forms of attic and mastoid suppura-

tion the treatment consists in antiphlogistic measures; if operative interference becomes necessary, the opening of the mastoid cells will suffice. In the chronic cases, before doing the radical operation, the tympanum should be curetted through the auditory canal and the ossicles removed. The retro-auricular wound is sutured in its upper two-thirds.

Botey has operated on ten cases of cerebral complications of ear disease, of which seven were abscesses of the temporo-sphenoidal lobe, two perisinuous abscesses, one thrombo-phlebitis of the transverse sinus where the internal jugular vein was not ligated. The last case, as well as three cases of brain-abscess, one of which was complicated with general meningitis, the other two with gangrenous cerebral hernia, terminated fatally.

As general routine Botey exposes the mastoid cells, the antrum, and the middle ear, searches for a tract in the bone with a probe; if found present, the tract is enlarged by a special gouge. For brain abscess the usual method is followed. The author does not think it necessary to remove the upper and the posterior wall of the antrum up to the labyrinth, as advocated by Jansen. He has observed two fatal cases of brain prolapse which had been operated on in this manner.

In the after-treatment the wound should not be irrigated; the dressings should be changed every day or every other day. Botey inserts a number of very small drainage tubes in the cavity of the brain-abscess, thus insuring free drainage, without the slightest injury to the brain tissue.

Dr. Heimann, Warsaw.—**On the treatment of certain forms of otitis media purulenta and on otitic pyemia.**—In all cases of purulent otitis with fever, and occipital pain or fever of the pyemic type, where the usual therapeutic methods are of no avail, and the symptoms are not due to retention of pus, the speaker, after exposing the mastoid cells, punctures or opens the cranial cavity, and aspirates or incises the lateral sinus. The opening of the cranial cavity is serviceable to relieve intracranial pressure even if no focus is found. The sinus is punctured only as a diagnostic procedure. Heimann exposes the mastoid cells, the cranial cavity, and the lateral sinus in one sitting. Of ten cases where the sinus was punctured, and three cases where it was accidentally injured, twelve recovered. In one case where the sinus was accidentally opened during the operation, the patient died four weeks later from pyemia. The writer

thinks that otitic pyemia should be divided into a thrombotic and a non-thrombotic form. An additional proof for the existence of a non-thrombotic pyemia Heimann considers the negative result of a puncture of the sinus. Non-thrombotic pyemia has a relatively good prognosis, while the thrombotic type always ends fatally unless operated upon.

Dr. K. SCHMIDT, Odessa.—**Otitic pyemia.**—Schmidt reported eight cases of otitic pyemia. In two of the cases no operation was performed; one died, the other recovered. Two operated cases died; four cases recovered after operation. He reaches the following conclusions: Pyemic diseases of otitic origin are only partly accessible to operative improvement, as we have no control of the bacteria when they have entered the blood current, nor when the infection has invaded the meninges. Spontaneous recovery from otitic pyemia is extremely rare; no time should be lost in operating. Definite rules for operating cannot be given. The best method is to operate according to Stacke by first exposing the middle-ear spaces, the attic and the antrum, then the mastoid cells, and finally going into the brain. A conservative method of operating is especially important for the preservation of hearing.

III. Session: August 21st, Morning.

Dr. E. MOURE, presiding.

The proceedings began with the discussion of the papers of Drs. JANSEN, BOTEY, HEIMANN, and SCHMIDT, of the preceding day.

Dr. HEIMANN described the origin of pyemia without thrombosis as follows: Micrococci enter directly into the blood current, develop and cause metastases as soon as the bactericidal power of the blood is lost. A possible explanation for the fact that in this form of pyemia chiefly excentric metastases in the muscles and joints appear, is that the internal organs contain more blood-vessels, and therefore are able longer to fight off infection from their increased bactericidal property.

JANSEN states that contrary to Schmidt's views there are definite rules for the operation in pyemia. Excepting the cases where the sinus thrombosis has the symptoms of a meningitis, the isolated sinus thrombosis is a clinically well-characterized picture, and next to the abscess of the temporo-sphenoidal lobe with abolition .symptoms belongs to the most readily diagnostica-

ble of all cerebral complications. The cases, however, are very difficult where only the signs of increased intracranial pressure are present.

JANSEN has often observed the picture of pyemia without thrombosis, as described by Koerner, but in only one case was he unable to determine the presence of a thrombus, though he suspected a thrombosis of the jugular vein. Every case of pyemia does not require operation. If the picture of the disease is mild, the appetite good, no characteristically pyemic tongue, we may stop at the sinus when no pus is found, as in the case of a thrombus, firm and localized to the sinus, the prospects are good. Recovery is not so very rare even after removal of an adjacent collection of pus. Jansen has two or three such cases. When a pyemic tongue, vomiting, and poor general condition are present the sinus should be incised. Isolated thrombus in the bulb of the jugular can be diagnosticated and operated on. When all the symptoms, as in Schmidt's successful cases, point to a solid closure of the jugular, Jansen also is of the opinion that one can wait. He published fourteen cases in his first treatise; since then he has had sixteen additional cases, with twelve recoveries. In general the numbers have been in favor of ligature of the internal jugular, though success is not to be ascribed to this alone.

POLITZER.—In certain cases of sinus and jugular thrombosis it is possible to make the diagnosis, especially when a cord-formation is found on the side of the neck. If this is absent it is difficult to decide whether the symptoms are not due to the admission of pyemic products in the blood. Politzer has noticed that cases with external metastases are milder than those with internal localization. Operations on the sinus should be undertaken with great care, owing to the danger of air-embolism.

KAYSER, Breslau, has operated successfully on a case with all the signs of pyemia without finding any trace of a thrombus.

VOSS, Riga, has observed that in two cases, ligature of the internal jugular did not prevent metastases ; the cases recovered. The chances are better in general when the jugular is ligated. Among nine cases four were children, and recovered ; of the five adults, three died ; hence age seems to play an important part.

HEIMANN has almost never found a thrombosis in early operations on cases with pyemic symptoms ; puncture only showed fluid blood (in ten healed cases) even where the internal jugular

appeared as a hard cord. Thrombosis develops later from the action of morbid products on the sinus, and particularly in those cases where the purulent focus and diseased tissue are not removed early enough. The prognosis is very poor if metastases exist in the internal organs. The diagnosis of sinus-thrombosis in the beginning of pyemia is only a probable one; the appearances may be the same in the pyemia with and without thrombosis.

UCHERMANN holds that pyemia may develop without thrombosis. Ligature of the jugular vein need only be undertaken in commencing pulmonary infarction.

Prof. UCHERMANN, Presiding.

Dr. MOURE.—**The surgical treatment of otitis media sicca.**—Surgical treatment of catarrhal otitis (sclerosis) is indicated whenever all other treatment (air-insufflation, direct and indirect massage) has proved unavailing. It should be preceded by exploratory myringotomy, because of its great prognostic value; patients who hear better after this can be successfully operated upon. The operation consists in the removal of the drum-membrane and the ossicles, except the stapes; it can be readily performed through the auditory canal. The retro-auricular operation is not more favorable and is liable to produce congestion, vestibular hemorrhage, and the infection of the middle-ear spaces from external sources.

The results of the surgical treatment do not show in every case an improvement in hearing or disappearance of the tinnitus; frequently the former is improved while the latter remains the same, or *vice versa*. Our experience thus far does not permit us to judge the length of improvement. When the operation has proved a failure, an artificial drum in the form of a cotton pledget, soaked in ten-per-cent. solution of carbol-glycerine, can be tried with benefit. The ear must be frequently examined, as the artificial drum-membrane may cause a serous exudate.

Though Moure has accepted Kessel's results very sceptically, this method seems to him to be the most efficient, which in certain cases has unquestionably caused an improvement in hearing.

Discussion.—POLITZER.—A surgical cure cannot be expected in cases of ossification about the oval window and extending into the labyrinth; even in commencing ossification of the oval window the removal of the ossicles is without avail. When adhesions

exist which impede the mobility and without an ossifying process at the oval window, the extraction of the stapes may be of benefit, as a new membrane can be formed.

COZZOLINO favors the conservative treatment of these affections.

BOTEY operates only in adhesive processes after inflammations or chronic catarrhs.

IV. Session : August 21st, Afternoon.

Prof. COZZOLINO, presiding.

Dr. UCHERMANN, Christiania.—**The tests for hearing in deaf-mutes and the importance of tone-exercises.**—The speaker, contrary to Bezold's opinion, thinks that Rinné's test is an excellent means of determining the condition of the auditory nerve in deaf-mutes. The examination, however, demands great practice on the part of the examiner, as well as a certain degree of intelligence of the patient developed by several years of school-teaching, and the assistance of the deaf-mute instructor. In certain cases it is only by aid of this combined method that we can reach any conclusion.

In regard to the use of the tone-exercises to increase the hearing power, they can only be employed with success where there is hearing power for vowels and consonants, and they should not be used in these cases to increase the hearing power in the sense of Itard and Urbantschitsch, but to practise the central power of differentiating tones. This is, moreover, cultivated in school by the development of the intelligence ; it is of importance that during instruction the teachers should talk as loud as possible. Before the child has learnt something of speech and articulation, it is impossible, of course, to say anything definite about the hearing power.

Discussion.—POLITZER does not share the enthusiasm for this method of tone-exercises which has long been practised by Itard and others. It must not be forgotten that seventy per cent. of deaf-mutes have severe changes in the labyrinth, after scarlet fever, etc., where, of course, no improvement can be expected. If hearing remnants are present, as has been shown and called by Bezold "islands of hearing," spontaneous improvement may occur, especially in institutions for deaf-mutes, and in these cases a further improvement may be expected.

ANTOINE DE LUIS reports three cases of deaf-mutism, in which long-continued hearing-exercises were followed by very satisfac-

tory results. A deaf-mute after a few months of exercises could hear a loud noise at one foot with face turned away, and could enter a public school.

HEIMANN has examined 308 deaf-mutes and found remnants of hearing left in eighty per cent. The results obtained by exercises are very meagre and not permanent.

Dr. VACHER, Orleans.—**Auto-infection in otology.**—Four main divisions of general conditions can be distinguished, which may react as well on the eyes (Panas) as on the ears: 1. Pyemias (variola, scarlet fever, measles, the eruptive fevers?). 2. Discrasias (albuminuria, uremia, diabetes, gout, rheumatism). 3. Infections in a true sense (tuberculosis, syphilis, pyemic fever, typhoid, cerebrospinal meningitis, erysipelas, influenza, etc.). 4. Chemical poisons (alcohol, nicotine, quinine, etc.). The presence of one or more of these conditions may cause changes in the auditory organ, hence the general condition should be carefully looked after in every ear trouble. Any infectious focus must be carefully searched for throughout the body, which could act directly or indirectly on the ear or the nervous centres of hearing. The various forms of tinnitus must demand our closest attention, as they appear frequently in the beginning of a general infection. It is usually assumed that all infectious diseases of the middle ear occur by extension of the inflammation of the nose or pharynx, still a certain number may result from auto-infection through the blood or lymph circulation.

Dr. BOTEY.—**On puncture of the round window in vertigo, tinnitus, and in some labyrinthine affections.**—After trials on the dead and on animals, Botey has punctured the round window six times on the living. The puncture is carried out under all antiseptic precautions; the position of the round window is usually readily found. The necessary needle, from its small size and particular construction, can only be introduced for a short distance. The puncture-wound heals rapidly. Botey has observed in cases where deafness was associated with unbearable tinnitus and severe vertigo, that puncture and aspiration have relieved the vertigo and tinnitus, but the deafness remained unaffected. Puncture also acts well in acute infiltration of the labyrinth, especially when Corti's organ and other sensory terminal organs have suffered a transitory pressure.

Discussion.—COZZOLINO punctured the round window with the thermo-cautery years ago, against his will, with evacuation of con-

siderable perilymph ; against expectation, vertigo and tinnitus were considerably relieved.

V. Session : August 23d, Morning.

Dr. HOCKE, presiding.

COZZOLINO described his method for the mastoid operation, which he designates **Antero-lateral mastoidotomy.** He claims the following advantages for his method : 1. The linea temporalis is never crossed. 2. The bony layer is less resisting. 3. The middle-ear spaces are directly reached. 4. The Fallopian canal and the lateral sinus are easily exposed. The method is only applicable for the first stage of the operation ; any of the other methods can then be pursued.

Discussion.—HARTMANN and JANSEN could not see any particular difference between this method and the ones usually practised.

Dr. COZZOLINO.—**Surgery of the Fallopian canal in paralyses of the facial nerve of otitic origin.**—Cozzolino draws attention to the frequency of facial paralysis in acute purulent otitis media and in the chronic forms where the bony wall of the facial canal is involved ; even congestive conditions may produce paresis. A rational surgical interference is indicated to free the canal from pressure produced by exudate, necrosis, etc. The site of compression is usually in the epitympanic portion of the canal. Cozzolino recommends a small, bent, raspatory-like instrument to open the facial canal with. The galvanic current may be employed to confirm a pressure-paralysis or paresis.

Discussion.—POLITZER has observed cases of otitic facial paralysis where the paralysis disappeared after the radical operation. The prognosis of facial paralysis occurring through traumatism during the operation is less favorable than the paralyses coming after the operation ; the latter usually disappear even after a long period.

JANSEN : There is a disease of the nerve which may cause death by meningitis and brain-abscess, but this disease, characterized by paralysis of the facial nerve, is not amenable to treatment. Granulations may invade the posterior wall of the facial canal ; these require very careful treatment. Otherwise the facial nerve comes only into consideration in its course from the semicircular canal downwards, where it is likely to be encountered in

removing the posterior and lower tympanic wall. We must always remember that slight contact with a diseased facial nerve may be followed by permanent paralysis. Jansen prefers the chisel to Cozzolino's instrument.

VI. Session, in the clinic Bazanova: August 24th, Morning.

Dr. KALCIC and Dr. KNAPP, presiding.

Prof. v. STEIN showed the appointments of the clinic Bazanova, which is under his direction. He explained a number of apparatuses, and spoke on the centrifuge in aural diseases and the instruments which he has used in his experiments.

Prof. POLITZER read a paper on **Contributions to the normal and pathological anatomy of the auditory organ, with demonstration of specimens.**

Dr. KNAPP (New York): **Obturating exostosis** treated by retraction of the auricle and of the posterior membranous wall of the canal. The tumor was chiselled out of healthy bone. Healing by primary intention. Knapp made the statement, twelve years ago, that the exostoses of the auditory canal were easily removed by chiselling in the healthy surrounding tissue. A recent case was that of a man, thirty-five years old, who previously had suffered from otorrhœa, which had ceased during the last year, though severe pain persisted. The canal was completely occluded by the hard tumor, which did not even permit the passage of a probe. After retraction of auricle and posterior membranous canal the mass was chiselled away close to its base out of normal bony tissue. The slight hemorrhage ceased spontaneously. The auricle was replaced and the canal filled with a firm plug of gauze. Fetid pus was found collected behind the exostosis. Deafness was greatly relieved, and the patient was discharged, healed, on the eleventh day.

Dr. KNAPP demonstrated a number of specimens.

Dr. KALCIC (Budapest) showed a transportable hand telephone for the detection of one-sided deafness.

Final Session: August 24th, Afternoon.

Prof. POLITZER, presiding.

Dr. SCHMIDT (Odessa): **Primary external otitis, considered from a clinical standpoint.** Otitis externa primaria is

generally a cutaneous affection, and hence may be subdivided into: diseases of the epidermis alone (ichthyosis) and of the corium in a mild (dermatitis) or severe degree (eczema).

Prof. POLITZER spoke on our present knowledge of the **Air-rarefaction in the external canal** and **Massage of the ossicles.**

Dr. OKUNEFF (St. Petersburg) read papers on the results of **Removing the saccule in dogs** and on **Sclerosis of the mastoid as a complication of otitis media purulenta.**

REPORT OF THE TRANSACTIONS OF THE SECTION OF OPHTHALMOLOGY AND OTOLOGY IN THE NEW YORK ACADEMY OF MEDICINE.

OTOLOGICAL PART OF THE MEETING OF JANUARY 18, 1898.

The President, Dr. E. GRUENING, in the chair.

The paper of the evening, **Symptomatology and Treatment of Otitic Sinus Thrombosis,** by Dr. FRED. WHITING, is published in this number.

Discussion.

Dr. H. KNAPP, in opening the discussion, said that he had listened to Dr. Whiting's important communication with the greatest interest, and found it difficult to discuss it. His personal experience was limited, yet he had seen almost all phases of the disease under consideration. In former years he, as others, had noticed well-marked cases of otogenous sinus thrombosis recover without an operation. Then he had seen and published others that got well when he, by extensive operation on the mastoid and the adjacent cranial bones (sulcus of the sigmoid sinus and lateral part of the petrous bone), had thoroughly cleaned out the *source* of the phlebitis and thrombosis. Of late years he had not been satisfied with this treatment, and would not be now, though the few cases where he had opened and cleaned out the sinus had terminated fatally. Dr. Whiting's cases were extreme, and his success shows that life even then can be saved by thorough, judicious, and skilful operating. The present speaker had come to the same opinion six years ago by the autopsy of one of his own cases, the most advanced he had ever seen[1] or heard of. It originated in an acute purulent otitis media, which soon im-

[1] Published ARCH. OF OTOL., vol. xxi., 1892, p. 239.

proved. He did not see the patient for four months. When she returned, after having given birth to a child, she had mastoiditis. He opened the mastoid, liberated pus, and cleared the cavity. The patient improved, but had a pleuritic effusion which soon disappeared. Not long after she developed symptoms of intense intracranial complication. He advised another operation on the mastoid, with opening of the cranium. Consent was refused longer than two months, when the chances of recovery were almost hopeless. He opened the mastoid extensively, found pus in the digastric groove, opened the posterior and middle cranial fossæ. punctured the sphenoidal lobe, found no pus. Patient died the same night. The autopsy showed meningitis as the cause of death, but thrombosis in both lateral sinuses, in both jugular bulbs, and in the upper parts of both internal jugular veins, in many of the smaller veins of the brain, an abscess in the temporo-sphenoidal lobe, another in the cerebellum. These enormous pathological changes, to judge from the symptoms, must have existed for months. Had the permission been given sooner, a thorough operation, such as we have listened to this evening, might have averted the fatal termination. He thanked Dr. Whiting, and congratulated him most heartily upon his unparalleled success. Though there was now quite a number of successful sinus-operations on record, no operator, to his knowledge, had had three successive cases in so short a time, all terminating in recovery.

Dr. McKernon said that he was glad that Dr. Whiting had emphasized one point, viz., that where tenderness is so marked along the jugular vein it is better not simply to ligate the thrombosed vein, but also to dissect it out entire.

Dr Gruening, in the name of the section, desired to thank Dr. Whiting for his most valuable contribution. He himself had had a number of cases of sinus thrombosis. Dr. Whiting had stated that the condition was more frequent in adults. He had recently seen a case in a boy æt. eight. Where tenderness and induration in the neck is discovered, he wanted to express a warning against pressing upon or manipulating the parts more than is absolutely necessary to establish the diagnosis. The clot may be dislodged and extend downwards, extending in twenty-four hours from the angle of the jaw down to the clavicle in cases where unnecessary manipulation of the parts (for the purpose of demonstrating the condition) had been made. [Dr. Whiting said he had emphasized this point in that part of his paper which he

had not read.] He is not sure whether tenderness is diagnostic of involvement of the vein, as indurated glands often give rise to a similar symptom. He does not know whether he would ligate in all cases. Recently in a case of his where ligation was promptly done by a skilful surgeon the patient lost ground from that time, and died two days afterwards. A clot had formed and there had been great destruction within six days from the onset. Wherever a hypodermic syringe had been introduced, an abscess had formed. In a second case in the same family, the membrana tympani was incised early, which was followed by a serous discharge. Five days afterwards there was post-mastoid tenderness down to the tip. On the sixth day he opened the mastoid, which was of the same kind as was that of the brother. The cells were large, with thin septa, and filled with pus and granulation tissue. This was all cleared out. Removal of bone over the sinus was advised and performed; found to be normal. The case did well. Two days afterwards the muscles down the neck were swollen and pus could be pressed from the neck into the wound. He passed in a director and slit the muscle down two inches in the neck, after which the case did well. He then remembered that when using the rongeur, he had torn the fibres of the sterno-cleido-mastoid muscle in pulling away a morsel of bone. One must be careful to avoid this, and where a piece of bone is held by muscle fibres in the jaws of the rongeur, the fibres must be divided by scissors, not torn loose with forceps, otherwise suppuration from cellulitis of the neck will follow. [Dr. WHITING said he had emphasized this point also in a part of his paper not read.] Streptococcus otitis is a very severe infection.

Dr. KNAPP asked whether there was any diabetes in these cases, to which Dr. GRUENING replied in the negative.

The discussion was closed by Dr. WHITING.

Adjourned.

DR. W. B. MARPLE,
Secretary.

BOOK REVIEWS.

L. JACOBSON (PROF., BERLIN): **Lehrbuch der Ohrenheilkunde.** Second edition. Leipzig, 1898.

The text-book of Jacobson in its second edition is a thoroughly remodelled, increased, and improved work. The number of pages has been raised from 447 to 521. The numerous plates are rearranged, and a new one is added to illustrate the different methods of covering the defects and securing a permanent opening after radical operations. In the first edition, which was destined to be a text-book containing, in the most compendious presentation, all that is necessary to know, no authors were mentioned. The second edition, in spite of the rigorous conciseness in style and economy in space, has an excellent and very extensive method of literary references. After the name of the author in the text there are one or two numbers in brackets, which give the place and page of the publication. The references are found at the end of the volume in a closely printed and judiciously abridged, yet perfectly comprehensive, *bibliography* of 25 pages. The names of the authors are printed in alphabetical order in heavy type. Each name is followed by successive numbers, according to the citations in the text, and by an abridged title of the work from which the quotation is taken. In this way the reader can at a glance learn how much the publications of an author have been used in the text-book. We should not omit to mention that the author, to avoid incorrect quotations, has verified all of his quotations himself, and where, not being able to get access to the original, he has been obliged to quote from reviews, he has marked the fact with an asterisk. If we add that this extensive, well-arranged, and most useful bibliography is followed by a detailed index of subjects, the reader will agree with the reviewer that the text-book of Jacobson is one of the most conscientiously composed and best-arranged works of its kind.

As to the *contents* of the book, we must limit ourselves to a few remarks. In the anatomy of the ear the topography of the middle ear is presented in all the detail its practical importance demands, whereas the descriptions of the external and inner ears, especially the latter, are meagre.

The chapter on *general diagnosis* of ear disease, 80 pages, is excellent; that on *general therapeutics*, including a number of operations, for instance, the paracentesis of the drumhead, and the removal of the drumhead and the ossicles, etc., is good.

The diseases of the *external ear* receive a space of 29 pages, those of the *middle ear* 129, those of the *inner ear* (the sound-perceiving apparatus) only 18.

Then follow a number of chapters on affections not limited to one particular part of the auditory organ, a better plan than if they were scattered over different parts of the book. These chapters are on: *Neoplasms, caries and necrosis, cholesteatoma, foreign bodies, injuries, simulation of deafness, examination of recruits and transportation officials, neurosis of the sound-conducting apparatus, malformations, intracranial complications of ear disease* (50 pages), *life insurance of ear patients, relations of aural to general affections* (23 pages), *diseases of the nose and the naso-pharyngeal cavity* (rather meagre, 13 pages).

The getting-up of the book is good, the paper heavy, the typography excellent, the diction, like the print, condensed, presenting an astonishing amount of detail on the 486 large-octavo pages of text, supplemented by 19 lithographic plates, each faced by a page or two of explanation of the numerous drawings.

The book cannot vie with the fundamental works of Politzer, Schwartze, Gruber, and Macewen, of the present time, or those of Wilde, Toynbee, and Tröltsch, of the recent past, but it takes rank with the best modern comprehensive text-books, such as Urbantschitsch, Barr, Dench, and others. The careful and painstaking composition, the judicious arrangement of the subject-matter, and the impartial and exhaustive use of the incident literature with admirable indexes of authors and subjects, are distinguishing features of this second edition of Prof. Jacobson's text-book which recommend it both to the beginning and advanced student of otology, as well as to the experienced aural surgeon for reference, revision of the old stock of acquired knowledge, and information of the progress in the science and art of his specialty. H. K.

MISCELLANEOUS NOTES.

Dr. JOSEPH GRUBER, Professor of Aural Surgery at the University of Vienna, celebrated his seventieth birthday, October 16, 1897, receiving the congratulations of his friends, pupils, and colleagues. The Emperor of Austria bestowed on him the high order of the Iron Cross. Prof. A. Politzer, the orator of the occasion, dwelt in warm appreciation on the researches of his fellow-otologist, and handed him an excellent bas-relief portrait, presented to him as a mark of honor by his pupils and friends. Profs. Urbantschitsch, Dittel, Schrötter, and others spoke in friendly and appreciative terms of their distinguished colleague.

Drs. E. HOFFMAN (Greifswald), B. BAGINSKY (Berlin), and L. JACOBSON (Berlin) have received the title of Professor, B. FRÄNKEL, of Berlin, has been appointed Ordinary Honorary Professor, and A. MARTIN, of Paris, has been decorated with the cross of the Legion of Honor.

The WESTERN OPHTHALMOLOGICAL, OTOLOGICAL, LARYNGOLOGICAL, AND RHINOLOGICAL SOCIETY will meet in Chicago, April 7th and 8th. The opening and closing sessions will be joint, the other sessions by sections, the ophthalmological in one and the otological, laryngological, and rhinological in another. President, Dr. B. E. FRYER, Kansas City, Mo.; Secretary, Dr. F. M. RUMBOLD, St. Louis, Mo.

The meeting of the AMERICAN MEDICAL ASSOCIATION this year will be at Denver, Colo., June 7th–10th. Section of Laryngology and Otology, B. A. RANDALL, Philadelphia, President; S. E. SOLLY, Colorado Springs, Colo., Secretary.

Contents of the latest numbers of the Zeitschrift für Ohrenheilkunde.

Vol. XXXI., Nos. 3 and 4.

6. W. KÜMMEL. Further contributions to the pathology of the intracranial complications of ear disease.

7. PAUL MANASSE. Double cerebral abscess with ventricular fistula. Optic aphasia. Recovery.

8. V. URBANTSCHITSCH. On disturbances of equilibrium and illusive movements.

9. L. ASCHOFF. The otitis media of the new-born.

10. L. SWAIN. Otitis media with extension to the cranial cavity and the nape of the neck. (Translated from the ARCH. OF OTOL.)

11. L. STERN. The otology of Ambroise Paré.

Report of the progress of otology in the second quarter of the year 1897 (published in this number).

Vol. XXXII., No. 1. Issued November, 1897.

1. TH. HEIMANN. The most remarkable cases of lethal complication of ear suppuration observed in the Military Hospital in Warsaw.

2. G. BRÜHL. Rinné's and Gellé's experiments.

3. TH. FREYSING and W. SCHWARTZ. Minor contributions from the ear and throat clinic of Rostock (Körner's).

4. NOLTENIUS. Modification of Dr. Barth's hook-retractor.

5. ALF. BRUCK. On the thyroidin treatment of chronic deafness.

6. A. KÖRNER. Literary supplement on chloroma of the ear and the temporal bone.

7–9. Reports of societies (Braunschwieg, Amsterdam, Moscow; the latter translated in the present number). Book notices.

10. ZWINGMANN. The Bazanova ear-clinic in Moscow.

Vol. XXXII., No. 2. Issued in January, 1898.

11. A. BARTH. Otitis media in early childhood.

12. O. LUBARSCH. Chloroma of the temporal.

13. H. SELIGMANN. Double acute cerebral abscess after chiselling of the mastoid. Recovery.

14. E. WERTHEIM. Complications of intranasal interferences.

15. RÖPKE. Cases of acute osteo-myelitis of the upper jaw of infants.

16. ALF. BRUCK. Supplement to the thyroidin treatment of chronic deafness.

17. C. A. THIGPEN. Some cases of complication of suppurative otitis media (translated from the ARCH. OF OTOL.).

Report on the progress of otology in the third quarter of 1897. (To appear in the next issue of these ARCHIVES.)

Professional news.

edies, and instruments, and to discuss in a progressive, yet conservative spirit all questions of present importance.

The ARCHIVES contain exclusively original papers on all branches of Ophthalmic and Aural Surgery, and original reports on the progress of Ophthalmology and Otology throughout the world. The original papers occupy about three-fourths of the space, and their scope embraces all subjects of scientific and practical interest in the departments of Ophthalmology and Otology.

Special attention is paid to the preparation of the Reports on the Progress of Ophthalmology and Otology. These Reports are intended to furnish *complete, systematic, and early reviews* of the current Ophthalmological and Otological literature of the world, and the work of preparing them is divided among a specially selected number of collaborators.

Under the heading of "Miscellaneous Notes" there will be published all kinds of professional news that concerns the Oculist and Aurist, *e.g.*, appointments, honors, resignations and vacancies, new ophthalmic and aural hospitals, prize questions and essays, announcements of Society meetings, etc.

Each volume contains besides a specified table of contents, an index of subjects and authors, both of the original papers and the reports, and a general index of the preceding seven years is added to every seventh volume.

Original papers of value from any source are solicited.

Communications for the English edition of the ARCHIVES OF OPHTHALMOLOGY should be addressed to DR. H. KNAPP, 26 West 40th Street, New York, those for the ARCHIVES OF OTOLOGY either to DR. H. KNAPP, or to DR. U. PRITCHARD, 26 Wimpole Street, W., London, England.

G. P. PUTNAM'S SONS, Publishers

NEW YORK — 27 & 29 WEST 23D STREET.

LONDON — 24 BEDFORD ST., STRAND.

PUBLISHER OF THE GERMAN EDITION

I. F. BERGMANN

20 Schwalbacher Strasse, Wiesbaden.

EDITORIAL NOTE.

In asking for continued support of the ARCHIVES from subscribers and contributors, the Editors offer no new program, but point to the record of the work that has been accomplished during the past twenty-eight years. At the first appearance of the ARCHIVES in 1869, they constituted the only periodical of their class in America, and had only a few predecessors in Europe. The international character of the ARCHIVES was a novel and distinctive feature.

The original program of the ARCHIVES to publish only original papers in semi-annual independent numbers has, in the course of years, been extended by the addition of reviews of the current ophthalmological and otological literature.

With the eighth volume, in 1879, the combined ARCHIVES, issued semi-annually, were divided into two separate journals, issued quarterly, and each of about the same size as the combined journal, and the reviews were converted into quarterly reports, systematic and comprehensive, though concise, on the progress of ophthalmology and otology.

Since that date, the ARCHIVES have developed into an extensive and conveniently arranged storehouse of knowledge for the instruction of the student and for reference by the practitioner and the investigator.

For more than ten years, the valuable material offered to the ARCHIVES has been so abundant that it has not been practicable to utilize for the English edition the full series of papers from the German, or the converse. Many articles had to be abridged, while of others abstracts only could be printed. Any one of our readers could, however, have secured, and can secure in future, from the American editor, or the German publisher, the loan of the original papers presenting the complete text.

It is the purpose of the editors to arrange, in the department of Reports, for the review of every publication which in their opinion contains material that can be called distinctive and important. It is, of course, impossible, within the limits of the ARCHIVES or of any similar journal, to give attention to every publication in their department of science. We may state further that it is not a part of our program to furnish a complete report on the *bibliography*, but only on the **progress** of ophthalmology and otology.

Though the systematic arrangement of the reviews is of importance for reference and comprehensive information, we shall publish, as early after the meetings as practicable, reports of the proceedings of societies, always bearing in mind that the ARCHIVES are not intended to be only a repertory of knowledge, but also a journal of news.

It is natural that the English edition of the ARCHIVES should give the advantage of time and space to Anglo-American contributors over the German, and *vice versa*. It is evident, however, that the association of the two editions lends strength to each, furnishing to the authors a wider circulation for their papers, and to the readers a larger and more diversified field of information.

NOTICE TO CONTRIBUTORS.

The editors and publishers of the ARCHIVES beg to offer some suggestions to authors who propose to favor them with their contributions.

1. As original communications the ARCHIVES can accept only such papers as have never been printed nor are intended to be printed in other journals. If a preliminary communication on the subject of a paper has been published, the author is requested to state this in the letter accompanying his manuscript. It is understood that contributors to these ARCHIVES and editors of other periodicals will make no abstracts of the original papers published in this journal without giving it due credit for the same.

2. Authors will receive gratuitously twenty-five reprints of their articles. If a greater number is desired,—notice of which should be given at the head of the manuscript,—only the additional cost of presswork and paper will be charged to the author.

3. In preparing manuscript for the compositor it is requested that the following rules be adhered to:

a. Write on one side of the paper only.

b. Write without breaks, *i. e.* do not begin a new sentence on a new line. When you want to begin a new line or paragraph at a given word, place before it in your MS. the sign ¶.

c. Draw a line along the margin of such paragraphs as should be printed in smaller type—for instance, all that is clinical history in reports of cases, etc.

d. Words to be printed in *italics*, should be underscored once, in SMALL CAPITALS twice, in LARGE CAPITALS three times.

4. Authors may receive proofs for revision if they will kindly return them without delay. We beg however to remind our contributors that changes in the copy are equivalent to resetting, causing so much additional expense. We therefore request them, to make, if possible, no alterations at all in their MSS., or, at least, to limit these to what is of essential importance.

CONTENTS OF VOLUME XXVII., NUMBER 2.

PAGE

1. A Case of Double Cerebral Abscess with Fistula into the Ventricles; Optic Aphasia; Recovery. By Dr. **Paul Manasse.** Translated by Dr. SELINA BLOOM, New York 115

2. Contributions to the Knowledge of Pyæmia. By Dr. **H. Eulenstein,** Frankfurt-a-M. Translated by Dr. ARNOLD H. KNAPP, New York 125

3. On Mild Cases of Middle-Ear Tuberculosis and the Accompanying Formation of Fibrinoid. By Dr. **A. Scheibe,** Munich. Translated by Dr. ARNOLD H. KNAPP, New York 129

4. Further Contribution to the Pathology of Intracranial Complications of Ear Affections. By Dr. **W. Kümmel,** Breslau. Translated by ADOLPH O. FFINGST, M.D., Louisville, Ky. 135

5. On Radical Tympano-Mastoid Operations. By **Herman Knapp,** New York. (An address delivered at the meeting of the Western Ophthalmological and Oto-Laryngological Association at Chicago, April 7, 1898) 148

6. The Determination of One-Sided Deafness. Six Additional Cases of Necrosis of the Labyrinth. Supplement to Article on Labyrinth-Necrosis and Paralysis of the Facial Nerve. By Professor **F. Bezold,** Munich. Translated by Dr. ARNOLD H. KNAPP, New York. (With Plate III. of Vol. XXXI., German Edition). 158

7. Report on the Progress of Otology in the Third Quarter of the Year 1897. By Dr. **A. Hartmann.** Translated by Dr. ARNOLD H. KNAPP, New York 179

8. Miscellaneous 206

   British Notes.
   Bequests, etc.
   Honors and Appointments.
   The Ulster Eye, Ear, and Throat Hospital.
   British Laryngological, Rhinological, and Otological Association.

9. Contents of the Latest Numbers of the *Zeitschrift für Ohrenheilkunde* 208

ARCHIVES OF OTOLOGY.

A CASE OF DOUBLE CEREBRAL ABSCESS WITH FISTULA INTO THE VENTRICLES; OPTIC APHASIA; RECOVERY.[1]

By Dr. PAUL MANASSE,

PRIVATDOCENT AND FIRST ASSISTANT.

Translated by Dr. Selina Bloom, New York.

IT has not become necessary, as yet, to find excuses for the publication of cases of recovery from cerebral abscess, especially when they show such a complicated course as the one here reported. It is not my intention to enter upon any general questions, but to restrict myself to the report of this one case, for the reason that in the near future a larger paper treating of this subject will be published from this clinic.

To begin with an extract from the history:

Dec. 30, 1896.—Mrs. M., forty-two years of age, had had typhus as a child, and, in consequence, discharge from the ear. Since then there has been an almost constant offensive discharge and deafness left; never headache, only at times slight dizziness. Since yesterday severe headache, vomiting, and fever; to-day loss of consciousness, never any paralysis.

Status præsens.—A tolerably strong woman, somnolent, faintly groaning. Right ear normal. Left: in the auditory canal, bad smelling pus, tolerably thickened; upon removal of the same, the drum is found missing, and two granulomata about the size of peas are seen suspended from the tegmen tympani; here, there is decidedly rough bone to be felt. Tests for hearing impossible.

Fundus oculi: right, about normal; left, papillary boundary somewhat indistinct; no hyperæmia, no dilatation of vessels.

[1] From the University Ear Clinic at Strassburg.

Pulse 54, tolerably hard and regular. Temperature 38.7°. In the urine no albumen, no sugar.

Diagnosis.—Extra-dural or cerebral abscess, probably in the middle cerebral fossa, respectively the temporal lobe. I suggested an immediate operation, which was performed by me the following day, with the assistance of Drs. Lobstein and Scheele.

Dec. 31st.—Operation under chloroform; ⅂ cut above and behind the ear, dissecting off the periosteum to a considerable extent; the bone found everywhere intact and of white color. Upon chiselling it is found hard as glass. Before the antrum is opened the dura is reached in the region of the middle cerebral fossa, or rather a purulent, gelatinous, infiltrated, thickened membrane, which pulsates strongly and shows itself to be the dura. Between it and the bone there is a little thin pus rhythmically forced out of the cerebral cavity synchronously with the cerebral pulsations. The typical radical operation (without plastic) was now made; antrum, aditus, and tympanic cavity are found filled with pus, granulation tissue, and bone fragments. Nothing is left of the ossicles except a small piece of the incus in the epitympanic recess. Tegmen tympani and antri are removed with a few blows of the chisel. The dura shows here, too, the purulent, gelatinous condition spoken of above. More and more bone is removed until healthy portions of the dura are found. After this a trial puncture is made into the pulsating temporal lobe; the withdrawn syringe is almost entirely filled with thick pus. The bone wound is now further enlarged toward the squamous portions, so that the defect here is about the size of half a dollar, and one can survey a large portion of the lateral parts of the temporal lobe and its base (above the tegmen antri et tympani). Then a large incision was made into the temporal lobe from within (tegmen tympani) outward in a frontal direction, which opened the abscess. It was found that all the membranes of the brain had grown together with the cortex around the abscess to form the abscess wall. The wall is about 7–8 *mm* thick at the thinnest portion, which was about the squama. About 100 *cu cm* of thick, offensive pus flowed out of the abscess. The remaining contents, which were in part hemorrhagic, were then removed with a sharp spoon, the lips of the abscess wound being held apart with hooks. Two fingers were then carried into the abscess cavity, which was found closed in everywhere by a tolerably thick wall, which showed, upon illumination, a yellow color. The greater portion

of the abscess lay in the region of the temporal lobe, but extended tolerably far backwards, undoubtedly into the occipital lobe. After being wiped out with sterilized gauze, the cavity was filled with iodoform gauze, and the wound back of the ear left open. During the emptying out of the abscess, pulse and respiration had remained unchanged. No prolapse of the brain in spite of the strong pulsation. After the operation, slight facial paresis in the lower branch.

Jan. 1st, 1897.—Patient slept well, is fully conscious, converses, takes some nourishment, is, however, tolerably apathetic. Pulse 88, regular. Temperature 37.0°–37.1°.

Jan. 3d.—Headache; pulse somewhat slow, 62. Temperature 36.7°–37.1°.

Jan. 4th.—Change of dressing. Considerable secretion of odorless pus from the abcess cavity; still a good deal of apathy. Temperature 36.9°–37.0°.

Jan. 5th.—Pulse 70, temperature 37.0°–37.1°. Patient slept well. Though asking for nothing to eat, she eats with appetite when something is given her. Shows to-day distinct signs of aphasia; can not recall the word teeth, saying, upon being asked to whistle, that she never could whistle, as she had no—what do you call them?—in the mouth. She calls keys knives, yet recognizes a knife very well; upon being shown a cigar, she says "that is to smoke"; a brush, "that is to dress the hair." She cannot recall the words themselves, however, although she takes the articles in her hands and feels them. Only upon telling her the first syllable is she able to conclude the word, as in cigar (ci). She can, however, repeat every word spoken to her. In the urine no albumen, no sugar. Fundus: In both eyes the cloudiness of the papillary border has increased, the vessels also seem veiled, but show no dilatation.

Jan. 6th.—Change of dressing. Bone- and skin-wounds without reaction. Upon removal of the tampon from the abscess cavity, however, a large quantity of thick, offensive pus shoots out of the cavity. Upon carrying in the finger, one comes upon a second cavity toward the front having rough walls. This is curetted, the entrance to the old abscess is enlarged by cutting off a piece of the wall (cortex and membranes), and both abscess cavities tamponed with iodoform gauze. From the old wound opening one can now carry the finger in, as well 6 *cm* backward as forward. During all these manipulations, the patient remained

sitting up in bed, without pain, without vomiting, with only considerable increase in the frequency of the pulse. In the evening, temperature 38.1°, pulse 86.

Jan. 7th.—Change of dressing. There are still large quantities of pus and necrosed cerebral substance emptied out of the anterior abscess cavity. Temperature 37.2°–37.4°.

Jan. 9th.—Temperature 36.7°, pulse 84. General condition good, no headache. Wound shows only a little serous secretion. Aphasia continues. Patient unable to recognize a large number of objects shown her—for instance, matchbox, borer, penholder, etc.; knows their use, however, and can repeat words spoken to her; she cannot recall the names of most objects, even though she takes them in her hand; she tries to smell a matchbox. In conversation, only a few of the principal words seem to fail her, these she tries to replace by using describing sentences for them.

Jan. 13th.—Fundus: still a slight cloudiness of the vessels and papillary border, left more than right.

Change of dressing. Both abscess cavities are now clean and show only a serous secretion. One can see, upon illuminating the cavities anteriorly, the separating white layer of brain matter between the two abscesses quite clearly; in this curtain-like dividing wall, which has about the thickness of a quarter, there is a hole of communication between the two. This layer is removed with forceps and scissors, so that one can look fully into both cavities; the one latest opened extends forward and inward, the other backward and inward. Both show well granulating surfaces.

To-day a more exact examination of the aphasia was made. Patient recognizes all objects as to their uses, but fails often to give their names, although she can repeat the names if spoken to her. She fails to recognize a bell held up before her; only upon hearing it ring, she says very joyously, "bell." She can not always remember the names of many objects, even though she handle them. There is also a slight paraphasia. A mirror is called spectacles. If one places before the patient eight or nine objects, and tells her to pick them up singly, while one calls out the name without pointing to them, she does this promptly. Reading and writing normal, visual field also normal.

Jan. 20th.—Abscess cavity somewhat smaller. Temperature, 36.6°–37.1°; pulse, 70.

Jan. 24th.—Patient slept well, has good appetite, aphasia still

remains. Change of dressing. For some time it has been noticed that there is no actual pus on the gauze taken out of the cavity, this being saturated with a more serous secretion. To-day, upon removing the gauze, a large quantity of light, clear fluid flows out of the cavity over the neck and shoulder of the patient. Upon illuminating, a necrotic spot is found toward the posterior horn, next to which there is a small, three-cornered slit, about 2 *mm* in size, out of which liquor cerebro-spinalis flows with each pulsation of the brain. Careful loose tamponage.

Jan. 26th.—To-day, upon changing the dressing, there is no great flow of cerebro-spinal fluid. Temperature 37.1°–36.9°.

Jan. 31st.—Every third day the dressing is changed. Moderate secretion. No more discharge of light fluid from the posterior angle of the abscess. Where the fistula had been, there was now a yellow coating; pulsation especially strong here. Entire cavity greatly diminished in size. Temperature 36.9°–37.1°.

Feb. 6th.—Change of dressing. The secretion emanates principally from the posterior angle of the abscess; pulsation strong at this point. Slight feeling of dizziness. Temperature 36.1°–37.1°.

Feb. 15th.—Abscess cavity still the size of a walnut, coated everywhere, in the posterior cornu also, with red granulations.

Feb. 21st.—Patient up for three days, is feeling perfectly well; wound growing smaller, tympanic cavity epidermisized for the most part. Aphasia can no longer be demonstrated.

March 11th.—Patient dismissed from the hospital, further treatment being out-door treatment. The wound back of the ear is still the size of a quarter; within it, a red, pulsating cerebral wound can be seen, which is flat, forming, however, no cavity. From its lower extremity a granulating wound-funnel projects into the tympanic cavity.

May 31st.—Dismissal. The surface of the wound has been covered over with skin for the past three weeks; from the tympanic cavity, there still flows some purulent secretion, for the treatment of which sublimate-alcohol is prescribed. Patient goes to the country for after-treatment, feeling quite well, being without pain, and having increased in weight. Whispered speech: 1 meter. Facial paresis cured. The flow from the ear has also ceased entirely.

The history shows this to be a very complicated case of cerebral abscess.

To begin with, it had been difficult, or rather impossible,

to make an exact diagnosis, because the patient was entirely somnolent and had never shown any symptoms of localized lesions.

In consequence of the symptoms of compression of the brain (the slight neuritis optica, the slowing of the pulse, the unconsciousness), on the one hand, and the existence of old purulent middle-ear trouble, with caries of the tegmen tympani on the other, it was possible to conclude that there was an accumulation of pus in the middle cerebral fossa; one had to leave undecided, however, the question as to whether this abscess lay extra-dural or within the brain. The opening of the cranial cavity alone could decide it. It is not necessary to waste words over the method of operation; it goes without saying that the radical operation (after Zaufal) should be performed in such doubtful cases, opening both cranial fossæ, being guided in further action by the local condition found. The operation showed one case to be, first, an extra-dural abscess, or rather a purulent pachymeningitis externa, and, secondly, a cerebral abscess.

The pachymeningitis externa, which is not a rare complication of otitic cerebral abscesses, was identified by a pathological change, which consisted less in a large accumulation of pus between the dura and the bone than in a purulent, gelatinous condition of the dura itself. The latter showed inflammatory adhesions with both soft membranes and with the cerebral cortex. Such a firm, fibrous adhesion between the cerebral membranes and the cortex is to be looked upon as a decidedly favorable complication of cerebral abscess, affording, as it does, a relatively good protection against threatened purulent leptomeningitis upon opening the abscess.

A further complication noticed in our case, was the existence of a second cerebral abscess. The discovery of the latter was due to a fortunate accident. For, in consideration of the immediate marked improvement of the patient after the operation, the presence of any further complication was not suspected; neither could the slight increase in the pathological changes in the fundus lead us to this

thought, for this condition is not unusual during the first days after the opening and emptying of a cerebral abscess (Zaufal[1] and others). It must therefore be considered as an exceptional piece of good fortune to find upon changing the dressing on the sixth day after the operation, a second abscess emptying itself spontaneously into the first.

The contents of this abscess, which was of the same offensive purulent nature as the first, pointed also to a long duration thereof. Both occupied a very great portion of the space of the left cerebral hemisphere. For from the point of entrance just above the tegmen, I could pass the whole length of my little finger (6 *cm*) forwards into the cavity as well as backwards, making the length of the cavity 12 *cm*. The white medullary substance was principally affected by the two abscesses, the cortical substance being entirely free.

As the two oblong abscesses did not extend in a directly sagittal direction, but inclined somewhat in front as well as in the back toward the median line, and also in consideration of the great width of the cavities, it was remarkable, that no communication with the lateral ventricles, especially with the posterior cornu, was noticeable. After emptying the pus during the operation, I had illuminated the entire cavity carefully with the electric lamp, and also examined all parts with my fingers, without discovering anything but the yellow membrane lining the cavity. Only later, when this abscess-membrane had been cast off, could a communication between the abscess-cavity and the ventricle be found. This had evidently existed for some time before I had noticed it. For though I had noticed for several days, upon changing the dressing, that the gauze taken out of the cavity was not really soaked with pus, but with a thin, light, clear fluid, still I regarded this serous secretion as produced principally by the granulating surface, now that all diseased parts had been cast off.

Only on the day when a light, clear fluid flowed from the cavity over the neck and shoulder of the patient in a stream did the idea occur to me that a ventricular fistula might have formed subsequently, and I illuminated and searched the

[1] Zaufal. *Prager med. Wochenschr.*, xxi., 1896.

cavity again. Then I could indeed discover in the posterior median angle of the oblong cavity a fine three-cornered slit out of which cerebro-spinal fluid was emptied with every pulsation. We have thus the rare complication of a ventricular fistula, and that a fistula of the posterior cornu. The history of the case shows us that such a ventricular fistula can very well be closed by granulations and be fully healed, provided that the process of repair be going on otherwise.

Again, remarkable to me, even though I had met with a similar state in other cases, was the utter painlessness, to this otherwise sensitive patient, of all manipulations upon the cerebral substance, such as curetting, cutting, etc.

One symptom which deserves special interest I should like to discuss briefly, namely, **the aphasia.** This was characterized in our patient by the following phenomena:

1. The patient absolutely could not designate objects in spite of the fact that she knew their import: saying, for example, of a cigar shown her, "that is to smoke," of a brush, "that is to dress the hair," etc.; at the same time she was able to repeat without failure words spoken to her.

2. Sometimes (though not always) she succeeded in recollecting the name of an object by making use of another sense besides that of sight—for instance, the sense of touch. but more especially the sense of hearing. She could not, for instance, upon looking at a bell tell the name of it; but upon hearing the bell ring, could immediately name it. This she did, too, with a small drum and with an empty water-glass,

3. She sometimes mixed the names of objects, calling a mirror spectacles, a key a knife.

The last of these three symptoms, the paraphasia, was not very clearly defined and only showed itself in naming a few objects; this can have been caused by the severe lesion of the temporal lobe on the one hand, whereas, on the other, it is not to be denied that the anterior abscess lay in the region of the isle, alterations of which are also made answerable for paraphasia.

The two other varieties of disturbance of speech are somewhat more interesting, as they indicate a form of aphasia which has only in later years attracted the attention of neurologists to any great extent.

The incapability of the patient to name objects about whose import he is fully conscious, there being at the same time no incapability of repeating words, was formerly called amnesic aphasia; when, however, the patient names objects properly through the mediation of an additional sense, as, for instance, touch, hearing, etc., which he cannot name by means of sight alone, we have that form of disturbance of speech before us which is usually called **optic aphasia.**

And just this variety was present in our case, as can be seen by the above report, whereas word-deafness, as well as, on the other hand, real motor aphasia was entirely missing.

This form was first exactly described by Freund,[1] after Naunyn[2] had differentiated two principal forms of sensory aphasia, the acoustic form, or aphasia with word-deafness, and the optic form, or aphasia with word-blindness. Freund places the lesion in these affections in the connecting tracts between the occipital and the temporal lobes, in that region which Naunyn considered a third cortical field, the two others being the already known ones of Broca (3d left frontal convolution: motor aphasia) and Wernicke (upper temporal convolution, sensory aphasia). Oppenheim[3] observes in reference to this point: the abscess is not uncommonly so placed that it breaks through the tracts which connect the sound image centre with the optic centres. It is probable that the localization in the lower and posterior portions of the lobus temporalis fulfils these requirements. He observes also that it is just in these cases that optic aphasia becomes more prominent—"that is, the patient is not able to transfer the visual impressions to the centre of speech in order to name the objects seen, whereas he can find the names of those objects in another way, for instance, by touching, smelling, tasting, or by means of association of ideas." Oppenheim refers also to a case of optic aphasia, published by Jansen,[4] in which it was principally the sense

[1] Freund, *Arch. f. Psych. u. Nervenkrankheiten*, Bd. xx., S. 276.
[2] Naunyn, *Verhandlungun d.* vi. *Congr. f. innere. Med.*, Wiesbaden, 1887.
[3] Oppenheim, *Fortschr. d. Med.*, 1895, S. 738; *Lehrbuch d. Nervenkrankheiten*, 1894.
[4] Jansen, *Berlin. klin. Wochenschr.*, 1895, No. 35.

of touch which assisted the sense of sight in the naming of objects. Zaufal and Pick (*l. c.*) have published a highly characteristic observation, which in the principal points is a true copy of my case: there too the abscess lay in the medullary substance of the left temporal lobe; there too there was optic aphasia with slight paraphasia, in which the optic aphasia was characterized by the fact that in the naming of objects both touch and hearing aided the incompetent sight, though not always with success, a phenomenon to which Oppenheim also has previously called attention. Our case is certainly of less value than Zaufal's for local diagnosis, because there existed not only an abscess in the posterior parts of the temporal lobe, lesions of which are made answerable for optic aphasia, but also an abscess taking in other more anterior regions of the brain.

The entire disturbance of speech disappeared in our patient after a time, as is generally the case when these abscesses run a favorable course.

CONTRIBUTIONS TO THE KNOWLEDGE OF PYÆMIA.

By Dr. H. EULENSTEIN, Frankfurt-a-M.

Translated by Dr. Arnold H. Knapp, New York.

NOTWITHSTANDING recent publication of a number of excellent papers on pyæmia, opinions on the origin of certain forms of this affection still diverge. Pyæmia following complete sinus thrombosis is a well established picture; but those forms of pyæmia, with a different course of symptoms and which have been especially described by Körner, require our further study and attention. Hessler and Brieger wish to consider this latter variety as a simple otogenous pyæmia without involvement of the sinus, and Körner calls it pyæmia through osteo-phlebitis. This group is chiefly characterized by the difference in the seat of the metastases, or their entire absence, its occurrence in conjunction rather with the acute than the chronic suppuration in the temporal bone, and the much better prognosis.

Leutert[1] has drawn attention to the parietal sinus thrombosis as the beginning of otitic pyæmia; a condition which has not received sufficient recognition. To decide the question whether the cases of pyæmia presumably without sinus involvement are cases of partial sinus disease or of parietal thrombosis, it is clear that as large a material as possible should be collected. I have observed the two following cases which seem to me to be relevant.

Case 1.—A. M., fourteen years old, was taken ill in the begin-

[1] *Arch. f. Ohrenheilk.*, vol. xvi., Nos. 3 and 4.

ning of March, 1897, with fever and right-sided earache; the symptoms were somewhat relieved on the appearance of a purulent otorrhœa. After several days of comparative good health the boy had a chill, vomited, temperature 40.4° in the night of March 12th. During the following days the patient appeared very sick, temperature remained up, slight otorrhœa. The mastoid was not swollen, and tender only along anterior border. Percussion of the skull was nowhere painful; pupils re-acted normally.

March 15th.—Operation. The mastoid process was very hyperæmic, the bone softened, but very little pus was found. The antrum contained granulations and a little pus. Everything that appeared diseased was carefully removed, and it was decided to postpone the exposure of the sinus as there had been no further chill, the fever was not of the pyæmic type, and no metastases had appeared. One hour later patient had a chill lasting fifteen minutes. Fundus oculi normal. Temperature 40.1°. On the following day, temperature 36.6°; the patient was quite comfortable. At 10 o'clock he went into collapse, then coma, and death on the following day.

AUTOPSY.—The dura is tense. The sup. longitud. sinus contains freshly coagulated and fluid blood. The pia is intensely congested. The lateral ventricles are dilated and contain clouded serum. The brain substance seems normal. The right lateral sinus as well as the other sinuses on the base of the skull contain fluid and freshly coagulated blood. After removal of the dural covering, the outer wall of the right sigmoid sinus was found to be unevenly thickened and covered with tough granulations; corresponding to this position on the inner wall of the sinus there was an elongated thrombus with a broad base 1½ *cm* long, which projected into the lumen of the sinus, and in its central portion was necrotic and purulent. The bone corresponding to the diseased area was very thin and necrotic. The tympanum contained pus and granulations. No hemorrhages in the endocardium. Lungs hyperæmic, the spleen and kidneys large and soft. The stomach contained some altered blood.

CASE 2.—E. G., twelve years old. Several weeks ago, after a tonsillitis, suffered with pain in the left ear, fever, and later otorrhœa. I saw the patient on March 21, 1897, and found a doughy swelling over the left mastoid process, which extended back over the occiput and was very tender. The otorrhœa was scanty and

the perforation in the drum membrane could not be seen. Temperature 38.4°.

March 22d.—Operation. The mastoid process was filled with pus, and the entire external bony wall was removed. In exposing the most posterior mastoid cells the mastoid vein was injured and bled freely. The antrum contained granulations and pus. An area of diseased bone was removed, which proved to lead to the lateral sinus. The sinus was freely exposed and its wall was found to be thickened and covered with granulations for 1½ *cm* in length. The diseased bone was carefully removed and the wound plugged with gauze. The fundus oculi was examined on the next day and was normal. The fever dropped during the two following days, and then during the next eight days followed the typical pyæmic course, fluctuating between 36.0° and 39.4°. Enlargement of the spleen could not be discovered, no metastases appeared. The wound healed and the patient was cured after six weeks.

REMARKS.

The rapid course of the disease in the first case is interesting. It evidently was a true intoxication by the extreme virulence of the toxine, which caused death before typical pyæmia was developed. The rapid course, the prolonged high fever, the patient's euphoria, the gradual unconciousness, and the gastric hemorrhages speak for this view. Therefore, according to the grade of virulence of the toxic substances, we have a rapidly fatal form, otitic sepsis of Körner, or a less virulent form with the clinical symptoms of pyæmia.

The sinuses must be carefully examined for thrombi at the autopsy, for it was only after we had removed the sinus from its bony wall and had spread it out that the thrombosis was found in the first case. This case also teaches us always to expose the sinus in cases with very high temperature even without the signs of pyæmia.

In regard to the second case, I feel it necessary to state my reasons for supposing the presence of a parietal sinus-thrombus. At the operation the outer sinus wall was found diseased and exactly similar to the sinus-lesion in Case 1. Notwithstanding the removal of all diseased bone, the fever of a pyæmic type persisted for several days. As a total sinus-

thrombosis and its consequences did not occur, three conditions were probable: an osteo-phlebitic pyæmia, a parietal thrombus of the sigmoid sinus or a thrombosis of another sinus. As the wall of the sigmoid sinus was found actually diseased, the second condition, that of a parietal thrombus, is the most probable.

Both of these are cases of acute affection of the temporal bone; it is as yet impossible to say whether parietal sinus-thrombosis follows acute cases more frequently than chronic.

ON MILD CASES OF MIDDLE-EAR TUBERCULOSIS AND THE ACCOMPANYING FORMATION OF FIBRINOID.

By Dr. A. SCHEIBE (Munich).

Translated by Dr. Arnold H. Knapp (New York).

THE presence of the characteristic tissue-changes due to Koch's bacillus proves the diagnosis of tuberculosis, still they furnish no clue as to the course of the disease. The course of tubercular disease depends upon entirely different factors. First, the localization is of importance. Tuberculosis of the skin is less dangerous than that of the mucous membranes. Furthermore, the age of the patient has great influence. We cannot, therefore, blame the practitioner for still maintaining a distinction between scrofula and tubercle, though both clinical pictures have the same etiological factor. A tubercular catarrh of the apex may in one patient remain stationary for years, while in another lead to a fulminant consumption in a short time; the difference in clinical course is due to hereditary influences, to the general condition—the clouded idea of the phthisical habitus plays a not unimportant nor unjust part,—and to the more or less favorably surrounding circumstances.

The same conditions hold good for the ear. Clinical experience teaches us that there is a severe and a mild form of aural tuberculosis. In the case of the middle-ear, which is the part of the auditory organ most frequently affected in tuberculosis, we know that the affection may be cured, though the anatomical conditions have been most unfavorable. The destruction of a small tubercle in the thin mucous membrane not only destroys this membrane but lays the bone

bare to serious nutritive disturbances. In addition, the middle-ear is especially exposed to the feared mixed infections.

It would lead me too far to add to the list of cured cases a number of others, but I shall have to speak of two cured cases later on in another connection.

Cases of cure are rare, more so than in other organs. This is due not only to the unfavorable anatomical relations, but to the fact that most cases of middle-ear tuberculosis occur in subjects with far-advanced phthisis, where the body can no longer offer any resistance against the tubercle bacillus. This phthisical variety of middle-ear tuberculosis is the most frequent and shows a pronounced tendency to destruction of tissue. It has but recently been fully described by Hegetschweiler in cases of Bezold's clinic.

Between these advanced cases and those which get well, there are a number of intermediate forms where the tubercular process does not disappear or advance, but comes to a standstill. It will be my endeavor to describe the latter form of cases. They do not occur as often as the advanced forms, though more frequently than has been thought, and even more frequently than we have found. The reason for this non-recognition has been due to absence of the characteristic symptom, the progressive destruction of tissue, which is typical for the advanced cases, and because the other symptoms were absent or were not sufficiently regarded.

Such has also been our experience in the six cases which I wish to report. We had them under observation without making the right diagnosis. The appearance of our symptom, which deserves more general importance, aided us in making the right diagnosis in all cases. One of these cases belongs in the list of the cured, while the remaining five are not the only ones of stationary middle-ear tuberculosis which we have observed. I shall restrict myself to these six cases because they are the only ones where this symptom was present.

Three of the patients were children and three were adults, though in two of the latter the disease dates from childhood. The otorrhœa had existed for 1, 2, 2¾, 9, and 35 years.

The otoscopic examination shows the entire absence of the drum-membrane in five cases; in the sixth the perforation is central and situated in the anterior half. In most of the cases with total perforation, parts of the hammer and of the long arm of the incus are wanting. Bare bone can be felt at these defects and in other places. The mucous membrane of the middle ear in five of the patients with total perforation is partly changed to epidermis, and in two of the cases the commencement of the aditus as well. No accumulation of cholesteatomatous masses in the upper middle-ear spaces were to be found.

The parts of the tympanic mucous membrane which were not changed to epidermis were partly granulating, partly only swollen. Polypoid hypertrophies were noted in three of the cases. The Eustachian tube in one case was impassable, in the others it was unusually patent. The mastoid processes were normal. The discharge usually was mucous and odorless. The mucous or muco-purulent discharge often came away in small ball-like masses, and persisted after months of treatment.

Hearing was in most cases greatly diminished. In one patient whispering voice (numbers) could be heard at 50 *cm*; this is the only case where after cessation of the otorrhœa the hearing power increased to 2½ *m*. The lower tone-limit was correspondingly reduced in all of the cases. In two of the three children a chronic otitis media purulenta existed on the other side.

Our examination in these cases revealed the usual chronic purulent otitis. It is remarkable that in almost all cases a total destruction of the drum-membrane was present without that any sufficient cause, like scarlet fever, could be elicited. The patency of the Eustachian tube and the considerable loss of hearing did not make us suspicious of tuberculosis, as the general appearance of the patients was excellent. In the subsequent course of the disease the discharge became scanty, though it was impossible to arrest it completely, although various methods of treatment were adopted, except in one case where a cure was brought about after 2½ years.

One symptom abruptly led us to the correct diagnosis; it did not appear before ¾ to 6 years of treatment. On the occasions of the patient's complaining of a freer discharge without known cause, we made a careful otoscopic examination and found the following condition: Situated on the inner tympanic wall, usually on the promontory or near the tubal ostium, there was a grayish thick membrane which could not be removed; occasionally bare bone could be felt with the probe through this membrane. The membrane adhered for a long time, and thereby differs from the membrane on the drum-membrane and bony wall of the auditory canal found in otitis externa crouposa. The condition of the membrane remained stationary from two to six weeks, when small pieces were dislodged by sprouting granulations, and in a few weeks more the entire membrane disappeared. The granulations contracted and became covered with epithelium or epidermis as before. The otorrhœa again became scanty and persistent.

This membranous formation has returned in only one patient after a length of time several times. In this respect also is the process different from the otitis externa crouposa acuta. As we had observed a similar process in the advanced form of middle-ear tuberculosis (Bezold [1]), we immediately made an examination of the discharge for tubercle bacilli and found them present in all cases in numerous quantities. The membrane was also found to contain tubercle bacilli. After the disappearance of the membrane repeated examinations of the discharge proved negative, except on two occasions.

When the correct diagnosis of the middle-ear affection had been made, we examined the patients for other signs of tuberculosis. In all, more or less distinct evidence of tuberculosis was found; but these changes were not pronounced and either were healed or showed a tendency to healing. In five of the cases the ear trouble was secondary, in one it was questionable.

The difference in the clinical picture of the just-described type and the advanced form of middle-ear tuberculosis is

[1] *Arch. f. klin. Med.*, Bd. xliv.

striking, and depends chiefly on the general health. As the health of those with the mild form of aural tuberculosis is good, so the course of ear trouble is benign. There was no destruction of tissue, at least at the time the patients came under our observation. The mucous membrane is granulating and a large part of the middle-ear is covered with epidermis. In the phthisical patients granulations are very rare, and epidermis-formation does not occur. The prognosis as to life in our cases is not unfavorable. The otorrhœa is equally persistent in the two groups. The mild form of middle-ear tuberculosis resembles chiefly the usual chronic purulent otitis. The membrane which we have described will aid in the diagnosis, but is transient in appearance and may not occur for years. The discharge must therefore be examined for bacilli, and the patient for any other sign of tuberculosis.

The total defect of the drum-membrane, the free patency of the Eustachian tube, and the considerable diminution of the hearing power are of some importance for a group of cases but not for a single one. When a case of chronic otorrhœa does not yield to regular antiseptic treatment during years, tuberculosis must be suspected in cases where the otorrhœa is not complicated with cholesteatoma. I have not been able to find Koch's bacillus in the cases of chronic purulent otitis with cholesteatoma.

The histological examination of the above-mentioned membrane has shown that it is composed of a fibrine-like substance, but not true fibrine. The basal membrane is a light-colored, granular mass, which does not stain easily, even with Weigert's method. In this mass there are a number of larger granules of irregular outline and which take on the stain more easily; they are presumably old cells and resemble connective-tissue elements. There are no vessels. In one of the specimens, cells with vesicular nuclei could be indistinctly seen, also numerous well-stained leucocytes. This membrane hardly seems to be necrotic tissue; it is much more likely to be an excretory product. Schmauss and Albrecht[1] have shown in their article on the caseous

[1] *Virchow's Archiv*, cxliv., 1896.

necrosis of tubercular tissue that there is a primary stage in the caseation of the tubercle, where a tissue similar to the one above described is found. This substance resembles fibrine but does not stain by Weigert's reaction. Hence these authors have named it fibrinoid, and think that the process may stop at this point, persist, or change to hyaline.

FURTHER CONTRIBUTION TO THE PATHOLOGY OF INTRACRANIAL COMPLICATIONS OF EAR AFFECTIONS.

By Dr. W. KÜMMEL, Breslau.

Translated by Dr. Adolph O. Pfingst, M.D., Louisville, Ky.

It is my purpose in this communication to add some recent observations to my previous report of otitic brain affections (these Archives, vol. xxvi., No. 4). In two of the cases which I shall report the presence of a brain abscess was diagnosticated and the pus evacuated, not early enough, however, to prevent a lethal termination.

In another case an extensive intracranial involvement was entirely overlooked.

Case 3.—Otitis media of long standing with perforating necrosis of the tegmen tympani and abscess of the temporal lobe. Evacuation of the abscess. Death from meningitis.

L. R., thirty years old, farmer, has had a discharge from the right ear and defective hearing on that side as long as he can remember. The discharge had at intervals become more profuse and along with the increased flow had taken on an offensive odor. While in this state the patient had suffered from pains in his head, which always left him when the discharge again became diminished. He has never felt any dizziness.

Eight days ago after a longer period of quiescence than usual the otorrhœa again increased and took on a foul odor. His headache was more severe than at previous attacks. He consulted me August 1st. His physician informed me that for several days there had been an irregular rise of temperature (maximum 103.2° F.), frequent vomiting, constipation, and finally diarrhœa. When I saw him, his temperature was 101.4°, pulse 74. He was

in a state of high mental excitability, his headache so intense that he continuously entreated me to administer chloroform. In walking, he would drag his feet in a sluggish manner and would step upon the entire sole. When he sat down, he did so very slowly and cautiously. There was no tendency to fall, but to sway slightly from one side to the other, which was not increased on closing the eyes. A slight tremor of the hands was noticeable, but all the other functions, including those of the face and eyes, were undisturbed.

Examination of the left ear revealed nothing abnormal. The right external auditory canal was filled with fetid pus, and when cleansed of this showed a mass of grayish-red granulation tissue occupying its entire lumen. The polypus was hanging down at a pedicle from above and anteriorly, emanating, evidently, from the attic. Owing to the hypersensitive condition of the patient efforts at its removal proved futile.

The history of this case—headache, vomiting, and irregular rise of temperature—and the presence of intense headache, marked physical derangement, and alteration of the gait of the individual, indicated almost beyond a doubt the existence of some intracranial inflammatory process. In arriving at a diagnosis, the existence of a thrombus of the lateral sinus could reasonably be excluded in view of the absence of all objective signs of this condition and of the typical pyæmic temperature. Furthermore, notwithstanding the long continuance of the ear affection, metastatic inflammatory foci had nowhere developed. The exclusion of thrombosis left for differentiation meningitis, extradural abscess, and abscess in the brain substance, either of the cerebrum or cerebellum.

There was no spasmodic contraction of the posterior cervical muscles, nor derangement of the ocular or facial muscles to denote meningitis, while the entire preservation of equilibrium favored the non-existence of a cerebellar abscess. The history of increased headache with increase in the discharge of pus from the ear, along with the absence of characteristic symptoms of cerebral destruction, rather indicated epidural abscess which at intervals discharged its contents spontaneously through the tympanic cavity. From the absence of tenderness over the mastoid process and

marked sensitiveness over the squamous portion of the temporal bone I inferred that the primary disease was located in the attic, and that the possible situation of the epidural abscess was above the tegmen tympani. The location of the primary disease in the attic was also suggested by the mass of granulation tissue seen projecting from it into the external auditory canal. The continuance of the symptoms on the following day, with a temperature of only 100.2° and pulse of 74, was conclusive evidence of compression of the brain, and influenced me to operate with a view of finding and relieving the cause. I proposed to open the antrum and to proceed thence, as indicated by the conditions found, into the middle cranial fossa, or the temporal lobe, or to expose the lateral sinus.

The operation was performed as follows: After exposing the mastoid by making the customary semicircular section, the cells were opened with a chisel until the lateral sinus was laid bare without finding pus. The middle cranial fossa was then opened by extending the operation upwards. The exposed dura appeared normal and did not pulsate. No pus was found. An exploratory puncture with a needle extending through the dura and upward into the brain substance revealed a pus cavity not far from the surface. The dura was divided by a sagittal section, and a scalpel, plunged into the cavity, allowed a large quantity of foul pus to escape. A drainage tube was then inserted to the depth of about 4 *cm* and a bandage applied. The temperature on that evening rose to 101.4°, pulse 72. The wound discharged so freely that the dressing was soaked.

Aug. 3d (following day).—At noon, temperature 104°. The face and extremities of ths left side were paralyzed. The patient was somewhat depressed. By night he was more cheerful, and the temperature had fallen to 100.4°. He continued to improve up to August 5th, taking liquid nourishment and showing no unfavorable symptoms. On that night there was a slight but sudden rise in temperature to 100.7°, and a reduction of the pulse beat to 64.

Aug. 6th.—Temperature 101.6°, pulse 58. Patient was fed with a stomach tube. Fearing that other parts were involved, I exposed a larger surface of the sinus, removing the bone with Luer's forceps, but found it healthy. An exploratory puncture was also

made into the cerebellum with a negative result. A diagnosis of meningitis was now made.

On the afternoon of August 7th the temperature rapidly rose to 104°, pulse to 166. Stupor increased, the heart becoming weaker until death took place.

At the **Autopsy,** held on the following day, it was found that brain substance had filled the opening in the right temporal bone. The Pacchionian bodies of the right side were much more numerous than on the left. The gyri of the right cerebral hemisphere were flatter than those of the opposite side, while the sulci were partly obliterated. The pia of this side was dry and contained a large hemorrhagic infiltration extending over the frontal and temporal regions, and over the fissure of Sylvius to the base of the middle cerebral lobe. The dura around the wound corresponding to the opening behind the ear was infiltrated and had a greenish-yellow hue. Over the tegmen tympani it carried a small, reddish-black, teat-like mass, which projected into the tympanum through an opening in the bone about the size of a pin-head. The bone around the opening was also discolored yellow. The lateral sinus appeared normal. On dissecting the cerebrum, the abscess cavity of the temporal lobe could be distinctly outlined. It now appeared as an irregular cavity narrowed above by the projecting brain substance. The surrounding brain tissue was infiltrated and soft, the degeneration extending to a less degree into the corpus striatum. Its intraventricular portion seemed almost obliterated, while the portion external to the ventricle was much enlarged. The ventricles were all distended and tensely filled with coagulated blood. From the posterior cornu of the lateral ventricle a canal was found running upwards and forwards and joining it with the abscess cavity. Its lumen had a diameter of about 8 *mm*, and contained fresh coagula. The surrounding brain substance was softened.

At the base of the brain the pia mater was opaque, and over the optic chiasm and just behind it contained purulent and gelatinous deposits. Infiltration of pus could be traced in the pia as far back as the cerebellum.

Sections of the right temporal bone through the tympanum showed this cavity to be filled with thick, fetid pus. Upon removing this a small grayish-black polypus was exposed, hanging from above, and entirely occluding a hole in the drum-membrane. It was found to spring from the lower end of what remained of the

malleus (just below the processus brevis). The tendon of the tensor tympani was intact. The attic was entirely filled with granulation tissue which imbedded within it the body of the malleus and the incus. Nearly the entire tegmen was necrotic, the sequestrum extending to the upper border of the petrous bone. Its rough line of demarcation left two small defects anteriorly between the diseased and healthy bone, creating a free communication between the tympanic and cranial cavities. Into the largest of these (1½ *mm*) the teat of granulation previously mentioned was projecting from the dura.

The vestibule and cochlea appeared normal.

This case furnishes a typical instance of extension of disease of the ear to the brain through the tegmen tympani. A small extradural abscess, which was no doubt an intermediary process, had on account of its minute size and its median position been overlooked. The course of the extension into the brain substance could not be traced, owing largely to the distortion occasioned by the prolapse of brain substance.

While it is probable that the operation was performed too late, *i. e.*, after infection of the meninges had occurred, this cannot be positively asserted, as there was ample time after the operation for changes such as the autopsy revealed to have taken place. The meningeal space could have become infected during the operation by a dissemination of infectious particles from the concussion of chiselling.

Infection of the arachnoid by its contact with the necrotic dura and an extension by gravity to the posterior cranial fossa is, in consideration of the predominance of the meningitis in that region, also a reasonable theory. Another possible avenue by which the inflammation could have spread to the meninges is the canal referred to connecting the abscess cavity with the posterior cornu of the lateral ventricle. Supposing this to have been the course of the process, the extension was evidently slow, the evacuation of the pus cavity having prevented more rapid and severe symptoms. Involvement of the meninges could possibly have followed the degeneration of the brain substance which took place around the abscess cavity.

CASE 4.—**Chronic suppurative otitis media. Cessation of the process. Infection of some of the mastoid cells, extension to the cranial fossa through the hiatus subarcuatus. Large extradural abscess and abscess of the temporal lobe. Evacuation of both. Death from pneumonia.**

D. O., thirty-six years old, travelling man, when admitted to the clinic November 2d, was in a stupor and to all appearances severely ill. The history of the patient, elicited from his wife, showed that he had been a frequent sufferer from otorrhœa on the left side and that on divers occasions paracentesis of the drum had been made. Otherwise little attention had been paid to the trouble.

Three weeks ago the patient was suddenly taken with severe headache and fever, and there appeared behind the left ear a painful swelling, which has since gradually increased in size. No pus came from the ear. The patient did not visit the clinic until driven to it by the intolerable pain, and until he was scarcely able to stand or walk alone. He had to be supported by a companion. His gait was laborious, and he dragged his feet in walking. Unsupported, his knees would give way from under him. There was no tendency to fall in any one direction.

The skin behind the left ear was reddened and tensely swollen, but not fluctuating. The swelling extended upward over a considerable area of the squamous bone and down beyond the limits of the mastoid process. The walls of the ear canal were swollen; the drum-membrane reddened, but not bulging. No discharge followed paracentesis of the drum. Temperature 103.1°; pulse 96. Examination of the fundus of the eye and functional examination of the ear were not made. The muscles of the eyes and face showed no disorder. There was no opisthotonus.

It seemed apparent, from the severity of the symptoms, that, besides the mastoiditis and the invasion of the external soft parts with pus, we had to deal with some intracranial complication, the nature of which could, for want of definite symptoms, not be determined. From the slow pulse and the absence of muscular rigidity, meningitis could, with a reasonable amount of certainty, be excluded. There was nothing characteristic to indicate a sinus thrombosis. Which of the other possible conditions might be present was left for the operation to determine. The patient was operated upon by Dr. Tietze soon after being admitted to the hospital. On making the section through the soft parts behind the ear, a quantity of pus was evacuated, and on removing the

periosteum from the bone, it could be seen oozing freely at three points from the mastoid. One of these points corresponded to the mastoid foramen, the other was more anterior at the base of the process, while the third was situated above the temporal ridge. Upon opening the bone with a chisel, the pneumatic spaces were found full of pus. They were removed with the chisel as thoroughly as possible, also the bone in a backward direction until the posterior cranial fossa behind the lateral sinus was exposed. An area of bone 5–6 *cm*, forming part of the floor and lateral wall of the middle cranial fossa, was also removed. The space between the openings into the skull represented the extent of the extradural accumulation of pus. A canal of communication between this abscess and the mastoid cells could not be found. The exposed dura over the cerebellum was very tense, and over the temporal lobe was distinctly pulsating. Several exploratory punctures into the cerebellum through the disinfected dura failed to bring pus, while the first puncture of the temporal lobe entered an abcess cavity at about 4–5 *cm* from the surface. The needle was left in place, and after a vertical section of the dura, the cavity was opened with a scalpel by following the needle. Two tablespoonfuls of foul pus were removed, a drainage tube was then inserted, a tampon of iodoform gauze applied around it to check the bleeding from the vessels of the pia mater, and the bandage applied.

Nov. 3d.—The patient passed a restless night on account of headache. His mind seemed clearer in the morning, but the stupor gradually increased toward evening. In changing the dressing at that time, the drainage tube was found choked and was replaced by a new one. The morning temperature was 103.1°; pulse 96. The evening temperature 102.4°; pulse 112. The fundus of the eye was examined and found normal.

Nov. 4th.—The patient was extremely restless during the night, singing and screaming alternately.. Toward morning he began belching. During the day he passed into a stupor, and toward evening vomited twice. On dressing the wound at night, additional punctures were made into the cerebrum and cerebellum without finding more pus. Broken-down brain tissue was coming away from the wound.

Nov. 5th.—The dressing was found saturated. The patient passed into a state of unconsciousness, being unable to swallow, and to void his urine. Temperature 99.2–100°; pulse 76–92. During the night he passed into a comatose condition.

Nov. 6th.—There was profuse diaphoresis, a rise in temperature, an increase in frequency of the pulse and respiration, and persistent eructation. Coma had become more pronounced.

Temperature 99.5°; 100.9°; 103.1°.

Pulse 120; 126; 156.

Respiration 26; 32; 54.

Nutrition was supplied artificially.

Nov. 7th.—Temperature 105.2°; pulse 156; respiration 64. Yesterday and to-day crepitant rales were heard over a large area of the lungs. No dulness on percussion.

Exitus letalis at noon.

Autopsy.—Outside of a marked fatty degeneration of the heart, there were no changes of the internal organs that would have a bearing on the case. The left tibia was thickened, evidently an old osteomyelitis. The wounds of the temporal bone made at the time of the operation contained prolapsed bloody purulent, softened brain tissue. On removing the calvarium, the dura was found tense. The longitudinal sinus contained a blood clot. At the base of the brain, particularly around the pons and medulla, the parts were obscured by a grumous mass situated in the pia mater and arachnoid. At the posterior inferior part of the temporal lobe, the drainage tube was found leading to a dirty, yellowish-red, softened mass. The discolored area was wedge-shaped, its apex being directed towards the dilated posterior cornu of the lateral ventricle. The tube seemed to be lodged in the cornu. The bone in the region of the tegmen tympani was marked by several translucent areas, which, upon removal of the dura, were found to be breaches in the bone covered over with a thin membrane. Corresponding to the highest portion of the tegmen (eminentia arcuata), near the upper border of pétrous bone, an area was found as large as a pea, which was discolored yellowish white and perforated by a large number of minute canals filled with pus. The dura had been removed from over this area at the autopsy, so that its condition could not be ascertained. The mastoid antrum contained no pus, although some was found in a number of remaining pneumatic cells. The drum-membrane was intact; the tympanic cavity normal. The vestibule, semicircular canals, and the cochlea were filled with a gelatinous, almost transparent mass. The finely perforated area of bone previously mentioned extended to within close proximity of a recess of the antrum, which projected upwards between the

superior and the horizontal semicircular canals. The lamina of bone separating it from the antrum was yellow, and was subsequently found by microscopic examination to be inflated with round cells. The elongated recess, as well as the rest of the antrum, was lined with delicate granulation tissue. Microscopic sections also showed a band of connective tissue, 1 *mm* wide, extending from the granulation tissue of the antrum, between the superior and the horizontal semicircular canal, to the previously described perforated area near the upper margin of the petrous bone. The tissue was infiltrated with small round cells. The surrounding bone, especially in a backward direction towards the internal auditory canal, was likewise infiltrated, and, judging from its reluctancy to take on stain, was undergoing necrosis. The semicircular canals were filled with loose connective tissue. No trace of the normal membranous semicircular remained.

The thought of an extension to the brain from the labyrinth at once suggested itself in this case on account of the abnormal contents of the labyrinth. A thorough microscopic study of the pathological changes persuaded me that the necrotic, infiltrated area near the superior semicircular canal was of more importance than was at first apparent. Waggenhauser (*Archiv für Ohrenheilk.*, Bd. xix., p. 95), v. Troeltsch, and others, after a close study of the process of dura mater, which in fœtal life enters a large opening in the petrous bone (fossa arcuata) to terminate in the cells under the superior semicircular canal, and of its disposition in after life, called attention to the possibility of cerebral infection taking place along this channel. A number of cases demonstrating this mode of extension have since been published by v. Troeltsch, Voltolini, Hartmann, and others. The band of connective tissue, described in our case, passing through the bone, corresponded in situation to the process of dura of fœtal life, so that the inference of an extension of the inflammatory process along its vessels from the middle ear to the labyrinth, and, simultaneously or subsequently, to the cranial cavity, would be justifiable. The inflammation, while terminating in resolution, left a band of connective tissue. A recurrence of the inflammation in this area at intervals probably rekindled the

trouble in the ear, so that, outside of the first attack, the otitis occurred secondarily to inflammation of surrounding parts. While we have no reliable history of our case to aid us in determining the cause of the primary ear trouble, I am inclined to believe that the affection dates back to the early years of the patient, and to associate it with the osteomyelitis of the tibia, which had existed for thirteen years. Along with the osteomyelitis of the tibia, the existence of a similar affection of the eminentia arcuata and of the bone surrounding the process of dura referred to is possible.

Little or nothing has been written about genuine osteomyelitis of the petrous bone. In the single case reported (Steinbrügge, in Orth's *Lehrbuch der speciellen pathologischen Anatomie*, 1891, p. 116) the author was not positive in the diagnosis. However, the history in Steinbrügge's case, as well as in the case just described, would suggest a secondary affection of the ear from diseased portions of the petrous bone. The view is strengthened by the frequent recurrence of the apparently healed process at the least provocation, such as a slight traumatism or cold. The case may at least serve as an incentive to search for osteomyelitis of the bone in fatal cases of brain complication of otitis.

Our case also presents some interesting features from a diagnostic standpoint. The discovery of an extradural abscess of such proportions, and the evacuation, would ordinarily have satisfied the operator, especially so as the dura presented a healthy appearance. The exceptionally tense condition of the dura prompted me in exploring the deeper parts in this case. After making an unsuccessful exploration of the cerebellum, to which I was led by the absence of pulsation of the dura over that part, I continued the search for pus, the marked internal pressure as evidenced by the tense dura convincing me of the presence of an abscess within the brain substance. Aspiration of the temporo-sphenoidal lobe through the pulsating dura verified the diagnosis.

The cause of death in our patient was undoubtedly the broncho-pneumonia superinduced by a debilitated state of the body. The infection of the lung may have been the

result of a general septic condition originating in the abscess or of the aspiration of particles of food into the lung.

CASE 5.—**Chronic purulent otitis media with cholesteatoma. Latent brain abscess with meningitis and sinus phlebitis—Diagnosis not made. Sudden death without operation.**

R. W., a boy, twelve years of age, with a good personal and family history, has an otorrhœa which began one and a half years ago without pain or any other symptom. It seems that the discharge gradually became more profuse, but the boy was not seen by a physician until a short time ago. Finding an aural polypus in the right ear-canal and frequent headache with an irregular rise in the temperature, the attending physician suspected an intracranial complication, and referred the case to our clinic. When I examined the patient on August 6th, his left ear was, outside of a retracted drum, found to be normal. The right ear-canal was filled with thick pus, which had but a slight odor. It was removed by irrigation and a mass of granulation tissue exposed in the upper anterior part of the canal, hiding the drum-membrane. Pus was exuding from behind it. As much of the mass was removed as was possible with the snare and curette. The function at this time for voice = 0, while the tuning-forks could barely be heard through the bone. There was no symptom of facial paralysis and no disturbance of speech or locomotion. The fundus of the eye was normal. No headache. Temperature 98.6°, pulse 72. Pressure over the mastoid and squamous bones elicited some tenderness. As the boy was bright and apparently not seriously affected, it was decided to watch the case for a while.

August 7th.—Irrigation of the attic brought little pus. Points of remaining granulation tissue were cauterized with chromic acid, and boric acid was insufflated. Temperature 98–99.1°, pulse 64–68.

August 8th.—No change in the general condition. The right ear was discharging pus freely. Soon after eating his evening meal the patient vomited, but afterwards felt comfortable. The fundus of the eye was still unchanged. We thought we were able to recognize a slight facial paresis, although this was questionable. Temperature 97.8–99.1°, pulse 64–72. During the night the patient vomited once and complained of severe headache. At 5 o'clock of the next morning his temperature was

100.7°. He again vomited, and not long afterwards passed into a state of unconsciousness in which he died at 6.45 A.M.

At the post-mortem examination made on the following day the right cerebral hemisphere was found to be 1½ times as large as the left. Upon incising the dura over the right ear several drops of pus escaped. The convolutions of the brain were more or less flattened on this side; the brain, outside of a softened, discolored, reddish-black area over the petrous bone, otherwise normal. This dark disintegrated area extended to within a few centimetres of the apex of the petrous bone. Over the tegmen tympani the dura and pia mater were adherent, a fibro-purulent deposit having formed between them. In making a transverse section of the right cerebral hemisphere, about 5 *cm* behind the apex of the temporal lobe, a large abscess cavity filled with yellowish-green pus was opened.

The walls of the cavity, which was about the size of an orange, were disintegrated and soft, and were speckled with small black areas. The brain substance around this well-defined capsule was softer than usual, especially in a backward direction. The ventricles of the brain were displaced, but in no way communicated with the abscess cavity.

The temporal bone, which had been sawed through the long axis of its petrous portion, was discolored grayish green over the tympanum from close to the eminentia arcuata to near the facial canal. The tympanic cavity was filled with granulation tissue which had perforated the drum-membrane at the upper and posterior portion, leaving but a small rim below and anteriorly. The manubrium and the long process of the incus were missing. The portions of the bones which remained intact were firmly imbedded in the granulation tissue. Above the bones, in the vault of the attic, a large, shining cholesteatomatous mass was found, separated from the hole in the drum by granulation tissue.

The white stratified mass extended into the mastoid antrum, in whose upper portion it was infiltrated with bright yellow pus. Posteriorly the enlarged antrum was separated from the sigmoid sinus by a very thin, dark red, porous lamella of bone. Both the cochlea and vestibule contained dried pus. The contents of the lateral sinus were also purulent, the abscess being limited at each end by a delicate thrombus.

We have in this case an instance of pus breaking into the cranial cavity from the ear by two separate and distinct

perforations of the bone, the one of the tegmen tympani admitting infection to the middle cranial fossa, the other of the mastoid wall giving access to the posterior fossa. The origin of the trouble seems to have been in the cholesteatomatous mass found in the attic, as it contained pus only in the small portion extending into the mastoid cells. However, the possibility of an external origin of the cholesteatoma with encroachment on the attic could not be excluded,

The failure to make a diagnosis in this case was deplorable. inasmuch as the age of the individual and his otherwise normal condition would have given him some chance of recovery, notwithstanding the magnitude of the cerebral abscess and the presence of encapsulated pus in the sinus. If only the mastoid operation had been undertaken it would undoubtedly have led to the discovery and relief of the other conditions.

The most remarkable feature of the case to me was the complete absence of symptoms with such extensive changes going on.

I have been unable to find a parallel case in literature. The only point which might have suggested complication of the ear trouble (of sinus phlebitis) was the irregular rise in temperature noted by the family physician.

ON RADICAL TYMPANO-MASTOID OPERATIONS.[1]

By HERMAN KNAPP, New York.

Mr. President and Gentlemen:

AMONG the surgical procedures cultivated so successfully by otologists during the last decades, the most important, but also the most difficult, is the so-called radical mastoid operation. It is called radical in contradistinction to the typical opening of the mastoid according to Schwartze. The radical operation, as it is now practised by Küster, Zaufal, Stacke, Schwartze, Jansen, and every active ear surgeon, means the free exposure and thorough removal, *à plein ciel*, of all diseased parts in the mastoid, tympanum, attic, and the numerous pneumatic cavities surrounding the ear. All these spaces are in connection with the auditory organ in the same manner as the air cavities of the face are in connection with the nose. Also the diseases of the one set are duplicated by those of the other. The excellent pioneer work in the treatment of mastoid disease done by Tröltsch, Schwartze, and others has been universally appreciated, but a new impetus was given to aural surgeons when Küster, of Berlin, in 1889, censured them for doing their work in the dark. He dwelt upon the necessity of free exposure of all the cavities of the middle ear during the operation and during the after treatment. The principle was so clear that it was at once generally adopted. Foremost in its application were Zaufal and Stacke, who simul-

[1] Read before the meeting of the Western Ophthalmological and Oto-Laryngological Society in Chicago, April 7, 1898. The discourse was illustrated by blackboard drawings, and followed by the demonstration of anatomical specimens.

taneously devised radical operations. At first their methods differed somewhat, but now, by the force of facts, they have become virtually identical. The problem is to lay bare and eradicate the morbid process from its origin to the remotest nooks and corners. Zaufal began his operation by penetrating into the antrum through the outer table of the mastoid, thence he proceeded through the aditus ad antrum into the attic, whereas Stacke went from the attic through the aditus into the antrum. Zaufal thinks his way is the easier, whereas Stacke contends that his is safer. Stacke says that he is sure not to injure the facial nerve or any other important part, when he passes a probe from the tympanum through the aditus, and chisels away the bone over the probe. When he has the aditus sufficiently widened, he opens the antrum from behind the ear-canal, chisels away the posterior wall of the latter, removes the anterior wall of the attic, and cleans out all these spaces just as Zaufal does. At the beginning, Stacke began the operation with detaching the cutis all around the ear-canal, and pulled it out, so as to gain a clearer view into the depth of the canal. At the end of the operation, he put the integument back into its place. Zaufal, and later also Stacke, began the operation with detaching the integument only from the posterior, upper, and, if necessary, part of the lower wall, and held it with a knee-bent retractor pressed against the anterior-lower wall. This has proved sufficient for almost all purposes.

Gentlemen, the operation is quite difficult and long. It is neither possible nor proper for me to describe it here in its many details; all I shall tax your patience and indulgence with is to make some remarks on the technique of the more difficult steps and the importance of this operation.

First, I desire to premise that so extensive an operation should not be done if a simpler one, viz., the opening of the mastoid alone, would be sufficient, as in the great majority of cases of *acute mastoid empyema.* On the other hand, there are many cases in which even the most radical tympano-mastoid operation is not extensive enough to cure the patient, namely, in the intracranial complications of purulent middle-ear disease. Yet, for the cure of these complications,

the radical operation is the indispensable initial step, just as it is the best prophylaxis of their occurrence.

As to the technique, I want to point out, above all, how to avoid the **chief danger** in this operation, the **injury to the facial nerve.** In mastoid operations we have, as a rule, first to expose the antrum, the starting-point for all further steps. The most natural way to enter the attic is from the mastoid through the aditus ad antrum. The latter being situated in the prolongation of the horizontal process of the incus and in the medial wall of the tympanic cavity, we can easily ascertain whether the bottom of the hole we have dug into the antrum has reached this plane or not, if we first introduce a probe through the ear-canal down to the bottom, and compare the depth of its penetration with that of the artificial hole in the mastoid. As long as the latter is less than the former, we may confidently chisel on, deepening the cavity, and removing the posterior osseous wall at the same time. In doing this we should always bear in mind that the facial nerve passes from the medial wall of the antro-tympanic canal not directly downward, but downward and somewhat outward, to the styloid foramen, which is situated near the anterior end of the mastoid groove.

In ordinary cases, after fully exposing the outer surface of the mastoid from the tip to about 1 *cm* beyond the upper wall of the external meatus, and denuding the upper and posterior bony wall, we proceed directly toward the antrum, by chiselling away the bone from above downward and from below upward in thin layers (Zaufal chisels in a horizontal direction), deeper and deeper, but all the time having the surface clear in view by carefully removing chips, blood, pus, granulations, or other tissue, examining with the eye and probe not only what we have before us but also what the condition of the successive strata is. When we have reached the antrum, we introduce a bent probe up and forward into the aditus, and over it or over a broader-bent probe—Stacke's protector (Schützer)—chisel the posterior wall of the bony meatus-wall away. While doing this down to the hard ridge which encloses the facial from the aditus to the styloid foramen, we have the face of the patient watched for twitchings, indicating interference with the nerve.

In case it is difficult to find the aditus by way of the antrum, we seek it by way of the tympanic cavity. Stacke, in his recent monograph[1] (which, though colloquial and verbose in style and controversial in character, is in a high degree impressive, attractive, and instructive), states that he prefers to begin the radical operation in the middle ear, because in this way he is always sure readily to find the antrum. Zaufal[2] and Schwartze and his assistants[3] do the same when they fail to find the antrum and the aditus from the side of the mastoid. I have in some cases, where I could not introduce the probe freely into the aditus from the side of the antrum, passed another from the attic up and backward to meet the first. In this way I could ascertain not only the position but also the curve and length of the antro-tympanic canal.

Another danger inherent in the radical operation is the **injury to the horizontal semicircular canal.** This canal is surrounded by a dense bony wall, which, during the operation, presents itself as a shuttle-shaped white, compact mass, slightly curved, with the convexity upward, and resting on the upper-posterior part of the Fallopian canal. Its upper end is part of the posterior wall of the antrum canal, on a level with the Fallopian canal. During the operation, it is protected by the single or double probe. If we are careful, having good light and the surface free from blood, it is easily recognizable—in fact, a very conspicuous landmark in this region, and not so liable to be injured as the facial nerve.

The most difficult but also the most important part, in my estimation, is the **clean removal of the lateral** (anterior) **wall of the tympanic vault** (the attic), which passes from the antral canal to the tympanic orifice of the Eustachian tube, hiding the upper parts of the mallet and anvil. It can be removed with a chisel either through the meatus or side-

---

[1] "The Operative Exposure of the Middle-Ear Cavities, after Detachment of the Auricle: a Radical Operation to Cure Inveterate Otorrhœa, Caries, Necrosis, and the Cholesteatomata of the Temporal Bone, with the Histories of 100 Cases." Tübingen, 1897 (in German).

[2] Zaufal, "Zur Geschichte u. Technik der operativen Freilegung der Mittelohrräume." *Arch. f. Ohrenhk.*, Bd. xxxvii., S. 33, etc., 1894.

[3] Grunert, "Beitrag zur operativen Freilegung der Mittelohrräume." *Arch. f. Ohrenhk.*, Bd. xx., S. 237, 1896.

ways through the antrum, but also with an appropriate rongeur-forceps (Zaufal, Hartmann, and others). I am accustomed to do it with a chisel from the side of the antrum, being careful lest the ossicles fall into the mouth of the Eustachian tube.

The main object in this, as in all other steps of the radical operation, is cleanly to remove all diseased bone and necrosed or heterogeneous substances, in particular the inspissated masses of secretion and necrobiosis, and the various epidermoid formations described under the comprehensive name of cholesteatoma. The latter, by the way, do not seem to be so frequently met with in America as in Europe, perhaps because we have not been so accustomed to look for them as our longer-trained colleagues on the other side of the Atlantic.

All this dead and decaying tissue is apt to cause and propagate the well-known deleterious processes of suppuration, caseation, necrosis, epidermization, thrombosis, pyæmia, meningitis, etc. With this object in view, we have to expose clearly and inspect attentively, by bright daylight or electric light, the surfaces which separate the ear cavities from the cranial fossæ. If these surfaces are discolored or corroded, they should be removed as far as they are diseased, and even if they appear healthy, but fever and other symptoms point toward the presence of an otogenous difficulty we should make an **exploratory opening** into the middle or posterior cranial fossa, or both. As it is not easy to discriminate between a meningitic irritation and a beginning meningitis, we may, in a given case, stop after a thorough mastoid operation, but must watch the patient carefully, and extend the operative interference if the cerebral symptoms do not abate in the next few days.

In reviewing the results of my operations, I scarcely ever have found cause to blame myself for doing too much, but frequently for not going far enough, or doing what was right, too late.

Will you, Mr. President and Gentlemen, now allow me to conclude my remarks by relating, in abstract, a few cases selected from my recent practice.

CASE I.—Mr. W. Moldauer, a strong man of thirty-six, came to me November 8, 1897, with otorrhœa in left ear, dating from childhood. Has been treated in Vienna. Suffered fifteen years from repeated attacks of pain in L. mastoid, and on the side and back of his head, more in winter time. Pain relieved when ear discharged. Large perforation of lower part of *Mt*, the upper and posterior thickened and red. Tip of hammer visible. L *h* $= \frac{c}{24}$; V $= \frac{20}{60}$. R *v* $= \frac{20}{20}$. Tenderness over mastoid.

Dec. 10, 1897.—*Radical operation;* posterior and upper part of soft wall of ear-canal detached; the bone wall chiselled away; lateral wall of attic and ossicles, partially carious, removed; the tip of mastoid chiselled open; no pus found but congested mucosa and soft diploic bone. Skin of canal horizontally split, pressed against posterior wall of wound by packing ear-canal with sterilized gauze.

Fever, temp. up to 102° F., and redness, swelling, and painfulness of the skin, neck, and adjacent part of chest on left side; all disappearing in five days. Discharged from hospital in two weeks, feeling comfortable. Discharge from ear greatly diminished. He came to see me three times, had pain and some dizziness, which disappeared after scraping out granulations from posterior end of ear-canal and medial surface of tympanum. He came to me twice more, feeling well, strong, and cheerful.

As I did not see him for two months, I wrote him a note asking how he was doing. I received the subjoined answer:

"NEW YORK, April 3, 1898.

"SIR,—We received your letter, and we are very sorry to state that your patient will never come to see you again. It is just eight weeks to-day that Mr. Moldauer died. He made a visit to your hospital on February the 2d and attended to his business afterwards. In the afternoon of Feb. 3d he complained of a great pain in his head, and he went up to his house to take a rest. In the morning of Feb. 4th he felt a little better, so he dressed himself to make you a visit. He only reached as far as the street when he felt a dizziness in his head. He had to be assisted back to the house and we laid him in bed, and before we had time to ask him how he felt, his head died, and in a few hours afterwards his body died after a terrible struggle, and this is why he could not come to see you again.

"M. MANDEL, 43 Bayard Street."

This patient suffered from chronic otorrhœa, which must have had another source than the tympanic cavity. He probably had an abscess in the temporo-sphenoidal lobe, which discharged through the roof of the attic during occasional aggravations of inflammation. Rapid death by perforation of the abscess into the third ventricle or into the subarachnoid cavity. After the operation he gradually improved, and when I last saw him he was so cheerful and free from all discomfort that I did not suspect a grave complication.

CASE 2.—Mrs. E. P., twenty-five years, came first in September, 1893, having had otorrhœa R. eight years. *V:* R $\frac{10}{60}$, L $\frac{20}{20}$. Headache, nausea, offensive discharge, drum-walls swollen, covered with white material; attic caries. Paracentesis, attic scraped, granulations removed. Symptoms temporarily relieved. Later, under cocaine, attic scraped in every direction. Anvil and head of hammer carious. Removal advised. Feels better. Headache, foul-smelling discharge, dizziness, nipple-shaped perforation in Shrapnell's membrane, rough bone and at times polypi scraped and removed. Syringed with tympanic syringe.

Oct. 6th.—Fistula in attic enlarged by incision. Part of *carious incus removed.* No malleus found. The carious walls of attic scraped. No reaction. After-treatment: wiping out of attic, and injections with tympanic syringe. Discharge scant, but offensive. Feels better, but at times has had severe attacks of headache, nausea, vomiting, and especially dizziness. Discharge offensive, purulent; feels free from head symptoms. She was treated persistently with the tympanic syringe, nitrate of silver, alcohol, under varying improvements and aggravations. The odor of the discharge did not disappear, and there were the occasional attacks of occipital headache and dizziness, giving warning. Therefore, a *radical operation* was performed Oct. 26, 1897.

The mastoid antrum and tympanic attic were thoroughly curetted, no fistula or necrosed bone found on roof of attic. The lateral wall of attic was removed. The ossicles were absent. When the patient came to after the etherization her mouth was crooked and she could not close her right eye (*facial paralysis*). No twitches of the face had been observed during the operation. There was headache, dizziness, nausea, and occasional vomiting for several days. Temp. normal, pulse slow (64). Wound and auditory canal

packed with gauze. Some swelling around wound, and a great deal of offensive discharge. These symptoms disappeared in six days.

From now on the patient made a slow but regular recovery. The facial paralysis disappeared in three months, the discharge grew scanter and has lost its odor almost completely ; two or three times after the operation I had to scrape off granulations from the upper-posterior corner ; she has had a few spells of headache and dizziness, but they were light and transient. In the attic region there is no smelling, no cheesy or scaly deposit any more, but slight granulations are there still : the tympanum is in a fair way of epidermization. The patient is in good health and cheerful.

This is the first time in all my operative practice that a case of paralysis of the facial occurred. It vexed me greatly because I consider it an avoidable accident, if proper care be employed. I was out of my guard after the posterior wall had been removed and the antrum and attic exposed in the manner described above. The wounding of the nerve must have occurred during the curetting, which, on account of the obstinacy of the case, and the long and inefficient treatment, I did quite thoroughly. In other cases I had noticed twitching of the face but no paralysis.

The wounding can have been partial only, for the paralysis was not complete and has entirely disappeared, which is alleged to be less common when the paralysis occurs during the operation than some days later.

CASE 3. Mrs. E. Gerth, aet. fifty, New York. Has had otorrhœa since childhood. When she was small, Prof. Bruns of Tübingen made a paracentesis of the left membr. tymp. for an abscess of the middle ear. Ear has discharged off and on ever since, but not copiously, and the hearing in it was poor. In 1893 she came to me for treatment. There being attic trouble (offensive discharge, flaky deposit in upper part of drum—cholesteatoma), I removed the anvil, the hammer having been destroyed by the suppuration. The patient was relieved, not cured. In January, 1898, she came again, complaining of intense pain in the ear and head. The discharge was moderate, but very offensive. The attic when probed, showed roughness of the walls.

Febr. 12, 1898. *Regular radical mastoid operation*, the tympanic

cavity, attic, and mastoid antrum converted into one cavity, the walls of which, especially those of the attic, were thoroughly scraped.

The recovery, thus far, has been smooth. The cavity in mastoid and ear were packed with gauze at first, in a week the upper part of the mastoid opening was sutured, the lower left open and kept open by a perforated silver tube. Water syringed into the ear escaped freely through the mastoid opening, which is now (April 1, 1898), almost closed. No granulation tissue in middle ear, apparently. Cutization from below. No discomfort in head or anywhere. "Feels like another person."

This is one of those cases—what the approximate percentage is I know not—in which the suppuration with more or less distress continues a lifetime. The patients do not die, but the disease is never cured. This probably depends on the more or less favorable conditions for free exit of the discharge.

The three cases here briefly detailed testify to the truth of the saying of Sir Wm. Wilde: "If an ear once discharges we never can tell what will be the end of it." In Case 1, it was death; in Case 2, apparent, but not yet certain, recovery; in Case 3, perfect recovery, as far as we can tell so short a time after the operation.

CASE 4.—Flossie Heissenbüttel, æt. three, offers an example of middle-ear disease in its progress to the sigmoid sinus, which was stopped and a cure effected by a radical operation. It was a case of *caries and necrosis of the mastoid with perisinuitis, checked and cured by operation.* She came Nov. 3, 1896. General health poor. Measles seven months previously, then broncho-pneumonia, mumps, suppurating glands of neck, fistulæ and sequestra in mastoid. Operation. Immediately under the skin there was a mass of necrosed bone, granulations, and pus. The sigmoid sinus was found to be beset with dark-red granulations which when removed exposed a healthy-walled sinus, soft to the touch with a sharp spoon. All the granulations were scraped away, the aditus ad antrum cleansed of granulations, the attic and tympanum laid bare and cleansed; also the posterior wall of the auditory canal was removed with a spoon. One immense cavity was thus formed out of the auditory canal, the interior of the mastoid, the tympanic

cavity, the attic, part of the posterior cranial fossa, and the pneumatic cells of the adjacent petrous and squamous portions of the temporal, all of which was carefully cleaned out with a spoon.

The first two days after the operation, temp. only 100°. The little patient picked up excellently. The after treatment required great and prolonged care. The improvement was steady. In May 31, 1897, almost completely well, no discharge. Child looks healthy. There is a large cavity behind the ear, the walls of which are evenly cicatrized. No discomfort. Seen again in the winter of 1897–1898. Perfectly well.

This child had the appearance of a consumptive. Its life was rescued by care on the part of the mother no less than by the energy and persistence of the physician, in which the assistants leading the after treatment were entitled to as much credit as the operator and surgeon in charge.

Shortly afterward another child was brought to the clinic, both of whose ears were affected in like manner as the one of the preceding case. The parents not caring to have a totally deaf and sickly child live, took it home some days after the operation where it died in a few weeks.

In conclusion, I want to mention the case of a woman who had *pyæmia* (pneumonia, etc.), in consequence of *otitic sinus thrombosis*, who was cured by a radical operation made years ago; and a child who suffered from an *otitic abscess* in the temporo-sphenoidal lobe, who was cured by a *radical mastoid operation*, lasting two hours, followed by *trephining* of the *skull, puncturing the brain, and letting out a large quantity of pus*, five years ago. The mastoid operation was far more difficult than the cerebral operation. It was radical, for the patient gradually was cured of all the discharge and discomfort from the ear; the cavity cicatrized, and has given no more trouble. Both patients, whose cases I published some years ago, are living and well. The cure of an intracranial lesion, brilliant though it may be, will not be permanent if the source of the difficulty, the mastoid disease, is not rooted out. All of which proves that the radical mastoid operation is the most important operative interference in ear surgery. It is the cataract operation in otology, and, I think, ranks as high as any operation in general surgery.

THE DETERMINATION OF ONE-SIDED DEAFNESS.

SIX ADDITIONAL CASES OF NECROSIS OF THE LABYRINTH. SUPPLEMENT TO ARTICLE ON LABYRINTH - NECROSIS AND PARALYSIS OF THE FACIAL NERVE.[1]

By Professor F. BEZOLD (Munich).

Translated by Dr. Arnold H. Knapp (New York).

With Plate III. of Vol. XXXI., German Edition.

IN my monograph on "Labyrinth-Necrosis and Paralysis of the Facial Nerve,"[2] 41 cases collected from the literature to the year 1886 and five cases of my own were described. Since then I have observed five additional cases, and in a sixth, belonging to Dr. Hummel, I was enabled to perform the autopsy. Necrosis of the labyrinth is unquestionably one of the severest morbid processes that attack the auditory organ. The mortality, according to my previous paper, is 16 to 20%. The necrotic process follows a chronic middle-ear suppuration of many years' standing; its occurrence is rare, and according to my statistics there is one case of labyrinth necrosis to 500 of chronic otitis media purulenta. Where the bony parts of the labyrinth have been destroyed, a destruction and loss of function of the soft parts can be assumed to have taken place. These cases furnish us with the opportunities of determining how much an ear can hear without its labyrinth.

This question is both of theoretical and practical interest.

[1] These Archives, vol. xvi., p. 297.
[2] Wiesbaden, Bergmann, 1886.

I shall hence first give the further course of my five original cases and then describe the six additional ones.

In CASE 1 (Kuhn).—I cannot be absolutely sure of the existence of a labyrinth-necrosis as I did not see the sequestrum myself and must rely on the statement of the physician in charge.

Supplement to CASE 2 (Rieger) (see chart).—Extraction of cochlea in 1883. The patient was seen again in Feb., 1885, after one month of fetid otorrhœa without other symptoms. Facial paralysis persists. In Dec., 1888, the middle-ear spaces are dry; the facial paralysis has practically disappeared. During the following years to 1895 occasional otorrhœa, from 1895 to 1897 the cavity has remained dry. No change in the facial paralysis.

FINAL EXAMINATION OF THE HEARING.

Right, whisper in 6 *m*.

Lower tone-limit: Right, 16 d. v.; left, f sharp'[1]

Upper tone-limit, Edelmann-Galton whistle: Right, 0.2 in 30 *cm*; left, 4.4.

Duration of hearing by air-conduction.

		Normal Duration.	Right Ear.	Left Ear.
A_2	clamped	35 sec.	— 5 = 0.86	not
A_1	"	75 "	± 0 = 1.0	"
A	unclamped	102 "	± 0 = 1.0	"
a	"	60 "	— 5 = 0.92	"
a'	"	88 "	± 0 = 1.0	"
a''	"	72 "	± 0 = 1.0	— 60 = 0.17 of normal duration
f'''	"	33 "	— 3 = 0.91	— 23 = 0.3 " "
c''''	"	70 "	± 0 = 1.0	— 42 = 0.4 " "
f sharp''''	"	28 "	— 4 = 0.86	— 14 = 0.5 " "

Supplement to CASE 3 (Blaim, 1885).—Re-examined in May, 1897. (See chart of functional exam.)

No otorrhœa after 1885. Complete facial paralysis. Lagophthalmos.

Hearing tests.

Whisper: right, 80 *cm*; left, not at all.

Ordinary speech: right, 6 *m*; left, several numbers, as well with closed ears, no improvement on approaching from distance of 20-40 *cm*.

Lower tone-limit: right, 18 v. d.; left, a'.

Upper tone-limit: right, 0.2 in 8 *cm*; left, 7.3 in 3 *cm*.

[1] These examinations were all made with the Edelmann new tone-series.

Weber's test: A to right + 7; a to right ±0; a′ to right + 4.
Rinne's test: right + 20 sec.; left, — ℞.

Duration of hearing by air-conduction.

		Right Ear.	Left Ear.
A_2	clamped.	0.71[1]	not
A_1	"	0.80	"
A	unclamped	0.85	"
a	"	0.88	"
a′	"	0.94	"
a″	"	0.86	0.11
f‴	"	0.42	not
c⁗	"	0.59	"
f sharp⁗	"	0.82	0.36

This case is peculiar, because the hearing duration in the tone-scale does not continuously increase from a″ to f sharp⁗, and that there is a hiatus between f‴ and c⁗. This is explained by the poor perception of those tones on the other ear.

CASE 4 (Dallmaier, 1883), Supplement.—Re-examination, May, 1897. The sequestrum comprised the cochlea and a part of the vestibule. (See chart.)

The left ear has only been dry during the last half-year. The auditory canal is completely shut off at a depth of 1½ *cm.* Deep scar over root of mastoid. Complete facial paralysis.

Right *Mt* diffusely clouded, small round scar in post. half.

Hearing-tests.

Whisper: right, 3½ *m*; left, not.
Lower tone-limit: right, 23 v. d.; left, a.
Upper tone-limit: right, 0.2 in 5 *cm*; left, 2.0 in 15 *cm.*

Absolute air-conduction.

		Right Ear.	Left Ear.
A_1	clamped	0.73	not
A	unclamped	0.72	"
a	"	0.76	only at impulse.
a′	"	0.66	" "
a″	"	0.88	0.22
f‴	"	0.73	0.33
c‴	"	0.77	0.50
f sharp⁗	"	0.79	0.54

[1] The normal hearing duration for each fork is omitted and only the resulting fraction given.

In this case the other ear shows a moderate shortening of the hearing duration for all tones, which is probably due to slight changes in the internal ear. The diminution is too slight and too uniform to be reproduced in the hearing range of the affected ear.

CASE 5 (Stirnweiss), Supplement.—The sequestrum consisted of almost the entire petrous bone; in addition, the other ear was also diseased. Recently, on inquiry, I learned that this patient had died in 1891, after a prolonged illness, during which she became totally deaf.

NEW SERIES.

CASE 6 (see chart).—Keller, age fourteen years. Otorrhœa, right, since childhood. Was examined July 1, 1887. Complete facial paralysis on right side for two weeks; some vertigo, no ataxia. On testing the hearing A, c′, a′, and a″ were not perceived. A large sequestrum could be felt with the probe. During subsequent treatment the sequestrum was discharged in fragments, the otorrhœa became very scanty, but the facial paralysis remained. Ten years later, the middle-ear cavity was found dry The facial nerve had partly recovered. The left *Mt* was normal..

Whisper: left, 6 *m*; right, several numbers are heard, but as well when ear is closed. Conversational voice: the numbers 23 and 99 are heard at 20 *cm*, but not directly at ear.

Lower tone-limit: right, h; left, 16 d. v. and lower.

Upper tone-limit: right, 1.9 in 3 *cm*; left, 0.1 in 25 *cm*, 0.2 in 6 *m*.

Hearing duration.

	Right Ear.	Left Ear.
A_2	not	0.77
A_1	"	0.89
A	"	0.92
a	"	1.0
a′	0.14	1.0
a″	0.29	1.0
f‴	0.42	>1.0
c⁗	0.51	>1.0
f sharp⁗	0.54	1

CASE 7.—Seemüller, sixty-two years old, examined April 26, 1889. The hearing in the left ear has been poor since childhood.

During the last two months profuse otorrhœa, severe pain and facial paralysis. Vertigo and tinnitus. The probe touches bare bone. *Right Mt* is opaque.

Hearing tests.

Whisper: right, 5 *cm*; left, not.

Left.—None of the deeper forks are perceived by air-conduction up to a″ inclusive.

A from the vertex — 5, a′ from the vertex to right.

Rinne A, right; — × Rinne a′, right + 18.

Upper tone-limit: right, a′′′′ (Galton 13.5); left, es′′′′.

On May 24th a sequestrum is removed with the forceps from the upper and back part of the middle ear, it appears to be a part of the vestibule. The patient did not return, and we were subsequently informed that he had died ten days later, after being unconscious for four days.

Case 8 (see chart).—Kimmerle, fifty-three years old, examined on Dec. 7, 1894. Left-sided offensive otorrhœa for four years, though hearing has always been poor. During last six months, pain and facial paralysis, which later disappeared. Vertigo for one year. During preceding week renewed pain. The post. wall of auditory canal is swollen; the region behind the ear is also swollen. No signs of a perforation.

Hearing tests: None of the deep tuning-forks are perceived on the left side up to a″, by air-conduction. A and a′ are lateralized to the sound ear.

Right *Mt* is retracted. Whisper heard in 6 *m*.

The radical operation was performed on Dec. 10th, on account of the narrowness of the bony canal. In the mastoid fossa and below the temporal crest the bone was found carious and partly covered with granulations. The tympanum contained polypi. The aditus and antrum are laid bare and the outer surface of mastoid removed. Körner's plastic.

On Feb. 23, 1895, the greater part of the first turn of the cochlea came away during syringing. Nov. 30, 1895, the entire wound is healed.

The hearing was again tested. Right ear: whisper in 6 *m*. Lower tone limit, 16 v. d. and more. Upper limit 0.9 (Galton whistle normal 0.8). Left ear: whisper not heard. Lower tone-limit, a sharp″ (old series).

Hearing duration.

	Left Ear.			
a''	0.19	of the	normal	duration.
f'''	0.24	"	"	"
c''''	0.47	"	"	"
f sharp''''	0.57	"	"	"

The forks d sharp'' to f''' appeared to my ear to be reinforced as they were passed by the patient's auditory canal which from the operation had become enlarged to twice the normal size and seemed to act as a resonator. The same phenomenon was noticed when I held one end of an auscultation tube close to the meatus.

Owing to the proximity of the two petrous bones, the conversion of the auditory canal of the ear with the defective labyrinth to a resonator for certain tones must influence the transmission of sounds to the other ear.

To exclude this influence, I introduced a rubber tube of the size of a normal canal in the enlarged canal and surrounded it with wet cotton to obliterate the cavity; the right canal was again occluded with wet cotton. Conversational speech was now heard by the sound ear in 3° *cm.* On the left side numbers were heard better at a distance of 2 *cm* from the cranial wall than close to the meatus.

Forks from d sharp'' up were perceived. The forks f,''' c'''', f sharp'''' were perceived from the left frontal eminence just as long as in front of the tube; a'' 3 sec. longer at the tube. After removal of the cotton, the forks showed the same perception, but a'' was heard 5 sec. longer at the auricle. Hence the increased resonance seems to apply to the vicinity of a''.

The whistles of the tone series were heard to their lowest limit f'' in 6 *m* with the right ear lightly closed, but exactly as well when the left canal was occluded with cotton.

The functional examination was repeated on May 22, 1897. The canal has become still broader.

Whisper, right, 6 *m.*

Lower tone-limit: right, 7.16 d. v.; left, d sharp'.

Upper tone-limit: right, 0.2 in 20 *cm*; left, 4.7 in 3 *cm.*

Weber's test: A, a, a', a'', to right ear.

Rinne's test: left, A, a, a' — ϑ.

Duration of hearing.

		Right.	Left.
A_2	clamped	0.9	not
A_1	"	0.95	"
A	unclamped	0.9	"
a	"	0.95	"
a′	"	0.89	"
a″	"	0.88	0.28
f‴	"	1.0	0.48
c⁗	"	0.91	0.54
f sharp‴	"	0.89	0.54

The duration for a″, c⁗, and especially f‴ has increased. This is too large to be an error in observation, and can be explained by the increased dilatation of the canal since the last examination, by which the canal is tuned higher, and serves as a resonator for the other ear.

CASE 9 (see chart).—Frühwald, thirty years old, was examined on May 19, 1896. At the age of six, otorrhœa, lasting one or more years. The left ear began to discharge again one year ago, with pain. Attacks of vertigo and tinnitus. Facial paralysis during fourteen days. At present the area in front of tragus is swollen. The mastoid is not tender. Profuse otorrhœa. Polypi. Right *Mt* has a scar.

Whisper: right, 7 *m*; left, uncertain.

a′ not perceived, lateralized to right.

The polypi and granulations were removed. On June 7th a piece of dead bone with sharp edges was removed.

As the canal was narrow and cheesy masses were still present in middle ear, the radical operation was performed. The middle-ear spaces contained blackish granulations, but no sequestrum. Körner's plastic.

Subsequent healing normal, except at one place, the lower and inner portion of the inner tympanic wall. On August 5th, fainting spells for five days. No vertigo or nausea. Nystagmus on looking to the right. From the unhealed place a small piece of bone was extracted on August 30th, and on November 6th a larger piece, consisting of the first turn of the cochlea. The wound then healed entirely. On May 25, 1897, the functional examination gave:

Whisper: left, uncertain.

Conversational voice: left, most of the numbers in 30 *cm*, worse directly at ear; not worse when both ears are closed.

Weber's test: A to right, sound ear ⫠ o; a′ to left, sound ear ⫠ o.

Rinne's test: right, + 28; left, — ϑ.

Lower tone-limit: right, 19½ v. d.; left, a.

Upper tone-limit: right, 0.1 in 12 *cm*; left, 0.4.

Duration of hearing.

		Right.	Left.
A_2	clamped	0.63	not
A_1	"	0.84	"
A	unclamped	0.84	"
a	"	0.92	"
a′	"	0.89	0.09
a″	"	0.88	0.23
f‴	"	1.0	0.37
c⁗	"	0.93	0.46
f sharp⁗	"	1.0	0.53

The duration for tones from a to f sharp⁗ is diminished so little that they can be regarded as normal. A stronger shortening is shown by A_2, and the lower limit of 19½ v. d. does not quite reach the lower end of the scale. Both speak for a slight change in the conducting apparatus, as is shown by changes in the drum-membrane.

CASE 10 (see chart).—Steinhauser, forty-one years old, examined on Oct. 9, 1896. Otorrhœa from both ears since tenth year. Sixteen days ago, headache and left total facial paralysis appeared. Right mastoid is tender; the left is not. Both *Mtt* wanting, with defects in bony canal. In the right middle ear, the floor and the aditus present granulations. In the left ear, the lower half of the inner tympanic wall is covered with granulations and polypi.

Hearing tests.

Whisper: right, 7 *cm*; left, not.

Lower tone-limit: right, f sharp; left, no fork up to a″ (incl.) is perceived.

Upper tone-limit: left, 4. 8.

A and a′ lateralized to right ear.

Rinne a′: right 12, left ϑ.

The headache and fever, and pain over right mastoid remained until Oct. 13th. Considerable vertigo. The otorrhœa, right, ceased, and the bony cavity healed. In the left ear, the granulations had to be repeatedly removed, and each time the granulation

showed a central fistulous canal. On Dec. 22d, a yellow sequestrum, consisting of the greater part of the cochlea with the straight portion of the first turn, was removed. The discharge then ceased and the wound healed. On March 23, 1897, the left-sided facial paralysis has almost entirely disappeared.

On June 18, 1897:

Lower tone-limit: right, E; left, a.

Upper tone-limit: right, 0.6 in 3 *cm*; left, 3.8 in 3 *cm*.

Duration of hearing.

	Right.	Left.
A	0.3	not
a	0.47	"
a′	0.34	"
a″	0.50	0.07
f‴	0.51	0.21
c‴	0.69	0.39
f sharp⁗	0.64	0.54

In this case the other ear was also defective, whisper was only heard in 7 *cm*. The duration showed a gradual diminution from the upper end of the scale down as it is customary in defects of the sound-conducting apparatus. Irregularities like f sharp⁗ and a′ point to an involvement of the labyrinth on that side.

CASE 11.—*Necrosis of cochlea, meningitis; autopsy.* Scheurer, twenty-one years old, admitted June 18, 1897, to Dr. Hummel's service. Otorrhœa after scarlet fever since seventh year. Three days ago, increased deafness, tinnitus, and pain in left ear. The canal is narrow, contains pus, and there is pain about the auricle. Granulations in middle ear. Temperature 38°, pulse 84; pupils react slowly. Whisper and fork a′ are not heard; a′ lateralized usually to better ear. During the following three months, headache off and on, slight fever, vertigo, vomiting, and profuse otorrhœa. The local condition in the ear was treated. General condition fair. During the night of Sept. 14th, the patient awoke with intense headache, vomiting, vertigo, contracted pupils, abdominal wall retracted and tender. On the 15th, severe chill, the pulse grew rapid, coma, rigidity of neck, and death on the 16th.

Autopsy: Dura tense. Pia vessels congested. After removal of brain, cloudy serum is found in the middle and posterior fossæ. The dura over the tegmen tympani is covered by granulations

which are surrounded by a purulent exudate. Purulent infiltration of the meninges in the base and over the Sylvian fossæ. The ventricles contained sanguinolent fluid. The brain substance shows hemorrhagic spots and superficial softening, but no abscess.

Left temporal bone: The dura, in addition to the change at the tegmen, is thickened along the posterior surface of the petrous bone. The lateral sinus is normal. The lower and anterior part of the inner tympanic wall is covered with granulations. The middle ear and a part of the internal ear are transformed into a cavity, open above and filled with sequestra and granulation-tissue; the affected part of the internal ear is situated in the posterior wall of the pyramid and extends to the porus acust. int. In the anterior part of this large cavity there is a freely movable sequestrum consisting of the cochlea. Another sequestrum is contained in the antrum; the remaining mastoid process is sclerosed. The distance from the antrum to the outer surface is 15 *mm.*

COMPREHENSIVE REMARKS ON NECROSIS OF THE LABYRINTH.

My eleven cases permit me to give a sufficiently clear picture of the symptoms of a purulent inflammation of the labyrinth which has progressed to the sequestration of bony parts. I have even been able, in the last few cases observed at my clinic, from the characteristic conditions to predict the appearance of a labyrinthine sequestrum, and which has really later occurred.

Etiology.—Labyrinthine necrosis is a condition following chronic purulent otitis. An otorrhœa of many years' duration usually goes before; there is extensive destruction in the middle-ear spaces, usually absence of drum-membrane, and a defect in the inner part of the upper and posterior bony walls of the canal, and the ossicles are more or less absent.

The otorrhœa in two cases began after scarlet fever, once after trauma, and in the other cases after unknown causes. If healthy individuals were attacked, the purulent otitis ceased soon after the casting off of the sequestrum.

In one case, No. 10, the affected ear, and also the other, showed the characteristic cholesteatomatous formation.

All of these cases applied for treatment at a time when the symptoms of an extension of the suppurating process were pronounced, and the chronic purulent otitis had previously received no treatment. In opposition to these eleven cases in which the sequestration had progressed to a certain degree, I have not seen one, among the many cases of chronic purulent otitis which have visited the clinic and have been kept under observation, where a sequestrum from the labyrinth has been cast off.

I do not believe that it is any particular form of suppurating process, or one with a peculiar germ or a general diathesis which induces these severe complications, but that they, like most severe middle-ear complications, are due to neglect of the local process.

Among the cases which I collected in 1886 was one, Christinneck, which was peculiar both as to its origin and course, and because it made the impression upon me of being a primary suppuration of the labyrinth ending in necrosis. Similar cases have been reported by Kretschmann and Trautmann. Since then a tardy occurrence or absence of perforation of the drum-membrane, especially in severe and extensive suppurations, in the middle ear, has been repeatedly observed by others and by me, and I now regard the diagnosis of primary labyrinth-necrosis as no longer justifiable. These three cases simply show that exceptionally an acute otitis media may lead to labyrinth-necrosis, though it is usually a very chronic process.

In order to examine more closely the *ways of extension of the suppuration to the labryinth*, the data furnished by the limitation and extent of the sequestrum are valuable. In nine cases where I was able to extract the sequestrum myself, it consisted six times of the completely preserved inner bony skeleton of the cochlea, once together with a portion of the vestibule. In the remaining two cases, one sequestrum cast off in early childhood was made up of the greater part of the petrous bone, including the bony labyrinth. In the second, to all appearances the wall of the vestibule was sequestrated. The sequestrum in the tenth case had previously been removed, and was said to be shaped

like a curved tube, hence might have been the semicircular canal as well as the cochlear canal. In the case that came to autopsy a sequestrum of the cochlea was present.

Generally the inner cochlear skeleton, with the entire or a part of the first turn, is the structure most liable to necrosis.

There are two ways by which the middle-ear suppuration may extend to the cochlea. First, by the accompanying inflammation of the small cells at the base of the tympanum and the commencement of the Eustachian canal, which surround the lower aspect of the cochlea to a varying degree. This system of air cells, which does not communicate with the mastoid group, is a homologue to the bulla ossea of the mammals. Secondly, by a perforation into the cochlea after rupture of the delicate membrane of the round window. In the first set it is to be expected that a part of the lower cochlear capsule should be cast off with the modiolus. This occurred, however, in only two cases. The necrosed bone usually consists of a larger or smaller piece of the internal cochlear skeleton. The beginning of the first turn is almost always found, with occasionally a neighboring part of the vestibule. The origin and extent of the sequestrum consequently make the second mode of infection, the invasion through the round window, the more frequent.

In the two cases of sequestration in early childhood, the necrosed bone was very extensive, including, in the one, the entire modiolus, with a large part of the vestibule and the porus acust. int.; in the other, the greater part of the petrous bone, with the entire labyrinthine capsule. All of the other sequestra which were removed from adults consisted only of a small part of the labyrinth, belonging, except in one, to the internal cochlear skeleton.

A survey of all the cases shows that the sequestrum formation is very much more extensive in the early years than in later life.

It is probably justifiable to regard the origin of the labyrinth-necrosis in the early years as a different one from that in adults. An inflammatory process of the well developed and vascular spongy substance surrounding the labyrinth, or extradural suppurative processes may be the cause for this

extensive necrosis. The fact that labyrinthine necrosis has been usually seen in early years of life may be explained by the sequestrum being so much larger and less liable to escape detection than in adults. In my own cases, labyrinth-necrosis occurred with equal frequency in all ages, and a peculiar predisposition in children cannot be upheld.

The initial affection, the suppurative otitis media, dates back to early youth in most cases and follows the exanthemata and the usual causes.

Whether a localized tubercular process in the auditory organ is a factor in the development of labyrinth-necrosis required some investigation. It is a well-known fact that in the final stage of a tubercular otitis media purulenta carious and necrotic processes are often present and destruction of portions of the wall and windows of the labyrinth frequently occurs. A real casting off of parts of the labyrinth is, however, very rare. In my cases of labyrinth-necrosis there were no symptoms pointing to a florid tuberculosis. I have never been able to observe in the living, nor in the thirty-nine autopsies of tubercular otitis described by Hegetschweiler, nor in the subsequent cases, a single instance of demarcation of any part of the labyrinth. A true migration and final expulsion of sequestra through the auditory canal does not occur in the tubercular processes. There is usually no, or a very slight, granulating process about the sequestrum, which is almost a constant condition in the middle ear of the tubercular otitis media in a later stage. An inflammatory reaction and formation of granulations is a necessary factor in the line of exfoliation of necrosed portions of the labyrinth. The profuse granulating process which we always saw preceding the extrusion of a sequestrum is to be regarded as the normal reaction of a healthy organism and an essential factor in the ultimate recovery.

The *clinical picture* of the labyrinth-necrosis has been fully described and I need only add a few remarks. To determine the time from the beginning of the labyrinth-invasion up to the elimination of sequestrum, we must have examined the hearing before and during the later stages. Most of my cases came under my care only a short time be-

fore or even after the elimination of the sequestrum, and total loss of hearing could only be ascertained.

Disturbance of equilibrium with simultaneous tinnitus and occasional vomiting, was mostly present (in only two cases, according to the patients, it was absent during the entire trouble) and would be more easily noticed by the patient than the occurrence of deafness in a previously impaired ear. Vertigo disappeared with the extrusion of the sequestrum, and with the tinnitus and vomiting it can be regarded as an irritative symptom of the nervous terminals in the ampullæ and sacculi. These symptoms are evident not only in the beginning of the labyrinth affection but may persist more or less continuously until a short time before the expulsion of the sequestrum. By one patient (8 and 9), whose answers were found very reliable, the vertigo was noted eight months, and, by another, one year before the sequestrum cast off. They may, therefore, be taken as the date for the extension of the middle-ear process to the labyrinth.

Paresis or paralysis of the facial nerve is a constant symptom of labyrinth-necrosis and usually appears one or several months after the first attack of vertigo. This, with the appearance of exuberant granulations in the middle ear, can probably be regarded as a sign of the progressive demarcation and commencing loosening of the sequestrum. In my previous paper I placed the frequency of facial paralysis at 80%. This is probably too low, because in the ten cases which I have followed the paralysis existed in nine. In the tenth case, which was examined six years after the removal of the sequestrum, complete paralysis existed for some time. The sequestrum in this case is the largest in my possession and comprises, in addition, practically the entire Fallopian canal. Nevertheless, no trace of facial paralysis could be found at the examination six years subsequently. The paralysis was permanent in five of the cases. In the other cases, the paralysis had existed only for a short time and had disappeared before the sequestrum was extruded.

Prolonged pain was a constant symptom and was of such severity as to prevent sleep for weeks and months, and produced a poor physical condition and emaciation. This pain

came on from two to nine months before the expulsion of the sequestrum; it was at first felt in the entire half of the head and accompanied by fever, vomiting, etc., probably due to meningeal irritation. Later the pain became localized to the ear and took on a more boring character.

Preceding or at the beginning of the symptoms the *otorrhœa* becomes *more profuse* and is creamy and very fetid.

Exuberant polypoid hypertrophies were present in all the cases, originating in the middle-ear spaces and protruding into the auditory canal. One of the cases, which was complicated with cholesteatoma and large bony defects, permits me to study closely the origin of these granulating masses. At the lower and anterior portion of the inner bony wall of the tympanum, a granulation, the size of a pea, reappeared every three or four days after removal, and always showed a central depression where a drop of pus would appear. The probe led to dead bone through this central perforation. This granulation recurred fifteen times until the sequestrum became loose. I have observed a similarly centrally perforated granulation in protracted cases of acute otitis media purulenta, and occasionally in chronic cases where a more or less large piece of dead bone proved to be the cause.

The *treatment* of labyrinth-necrosis can be discussed in a few words. It consists of systematic cleansing, insufflation of boric acid powder, and removal of granulations. This usually suffices to alleviate the acute symptoms, and the facial paralysis often disappears. A forcible extraction of the sequestrum before it is loose is not advisable. The *mastoid process is rarely involved.* In one case (No. 4), that of a 1¼-year-old child, several pieces of dead bone belonging to the mastoid had to be removed by Wilde's incision. In two cases (3 and 9), I performed a radical operation with use of Körner's flaps on account of threatening general symptoms, and thus prepared a broader exit for the sequestrum. I think that a properly executed radical operation insures a safer recovery than if the sequestrum is spontaneously eliminated through a narrow canal, especially if signs of general disturbance are present. In the two

operated cases and the case which came to autopsy, the mastoid process, except the antrum, was found solid and sclerosed. After the removal of the sequestrum all symptoms quickly subsided.

The *final result* in the ten cases was: In six, complete recovery with epidermization of the cavity. Case 7 was reported as cured by the physician. In Case 8 an atresia of the bony canal resulted. Case 9 had died probably from a complication in the other ear, which had suffered from a severe ear disease; the patient became totally deaf before his last illness. In the 10th case, death ensued eleven days after removal of the sequestrum, presumably of meningitis.

FUNCTIONAL EXAMINATION.

Some otologists have thought that even after loss of portions of the labyrinth some remnants of hearing remained. I consider this erroneous and due to the fact that it is impossible to exclude the other ear from the act of hearing.

Bec has come to the same conclusion after a large series of observations. von Stein in the "functions of the different parts of the labyrinth" has shown the various errors and mistakes which the cases with presumable remnants of hearing are liable to.

The conditions in a number of bilateral labyrinth-necrosis would be conclusive. The only two cases which were published by Gruber and Max were totally deaf, and the child observed by Max became a deaf-mute. This result, it might be said, need not necessarily occur in all ears. The preceding observations of labyrinth-necrosis have fully convinced me of the difficulty of diagnosing one-sided deafness. Reliable evidence of a remnant of hearing which could with certainty be referred to the side with the defective labyrinth could not be obtained.

In regard to the hearing of speech, a certain number of words are heard, the sound ear being closed, at some distance, though the perception is as good when the affected ear is tightly closed as in Dennert-Lucae's test.

It is striking that the improvement of hearing during this test is not proportional to the increased proximity to the

ear, as is customary in an ear with defective hearing, but on the contrary it is reversed. This condition is explained by Guye, who thinks that the head acts as a hearing screen for the other ear. A more definite picture is obtained by the use of clear tones in the testing than by speech. With aid of the continuous tone-series, we are enabled for the first time to obtain a satisfactory survey of the defects in hearing due to labyrinth-necrosis.

The results of the *osteo-tympanic* sound-conduction can be passed over in a few words, as a complete exclusion of the other ear is even more difficult than in air-conduction. Weber's test is of least value, as the results are difficult to ascertain. In none of my cases was the tuning-fork placed on any part of the skull lateralized with certainty to the affected side. The duration of bone-conduction can be lengthened or shortened according as a middle-ear affection, a normal condition, or internal-ear disease is present in the sound ear and thus gives us no data concerning the affected ear. Rinne's test with a′ or a deeper fork is of course always negative on the side with the labyrinth defect, as the fork is not perceived by air-conduction and is transmitted per bone to the sound ear.

The *aëro-tympanic* tests are therefore the only ones to give us conclusive proof of the hearing power in the affected ear. I have been able to examine seven ears in this manner. To determine the extent and size of the hearing-remnants, we must find the (1) lower and upper limits in the tones which are perceived, and (2) the duration of hearing of a number of sounds within the perceived portion of the scale.

1. Determination of the upper and lower limits of hearing.

The lower limit was determined with aid of the clamped forks of my former tone-series and with those of the new Edelmann's series. As the tones in the latter series are louder, the lower limit was found with them to be somewhat lower. In the old series, the lowest tones were found to be 3 times d sharp″, twice g′, and once f sharp′. The seventh patient (Case 10), whose other ear showed limitation of the lower part of the scale from f‴ down, could not hear any forks of the old series to a″; the loud resounding unclamped

a′ was the first to be perceived. Excepting in this case, the lower tone-limit in the old series was situated between d sharp″ to f sharp′. These lowest tones were only perceived by the strongest percussion with the elastic hammer directly at the ear. This explains why their perception in previous tests often escaped me. In the new Edelmann's series the lower limit was once a′, f sharp′, d sharp′, h, and 3 times a; *i. e.* between the octave a′ to a″.

The considerable force of sound made necessary by these experiments made it difficult to exclude the other ear. It was easy, on the other hand, to see the total defect for all tones situated lower down in all these cases of defective labyrinths. Below the a of Edelmann's series, which is heard by a normal ear at many metres' distance, not a single tone was perceived.

The upper tone-limit was determined by the modified Edelmann-Galton whistle. The upper limit for the normal ear is 0.2, occasionally at 0.1. As soon as we go down somewhat lower than this upper limit, the impossibility of excluding the sound ear becomes evident. The limit varies therefore much more than at the lower end of the scale, and my results have varied very much during the different tests. The limit 0.4 was reached but once; in 5 cases it varied between 1.9 and 4.9; in case 7 the upper limit was at 7.3. This case showed for the other ear a restriction for the upper part of the scale from f‴ up.

2. *Determination of the duration of hearing.*

A satisfactory survey of the hearing-remnants in ears with a defective labyrinth can only be obtained by studying the continuity and the duration of hearing of the various tones contained in the preserved hearing range after the upper and lower limits have been determined. For this purpose I have employed the unclamped tuning-forks A, a, a′, a″, f″, c⁗, and f sharp⁗, as in my examination of deaf-mutes. These unclamped tuning-forks have a much longer period of vibration than the clamped ones; notwithstanding the greater intensity of the latter at the outset, the former are better suited for these tests. The same difference means a smaller error for the forks which die out slowly than those

which fade away more rapidly. Small errors in observation are magnified with the abbreviation of the period of vibration in the forks employed. The duration of hearing was expressed in the scale of a common unit for all tuning-forks; the normal duration was called 100 or 1, and thus the results could be directly compared. Gradenigo has given a graphic statement of the hearing-remnants in an ear with a defective labyrinth. As will be seen lower down, our results compare favorably.

The duration of hearing was determined for the above mentioned seven cases with the unclamped tuning-forks. Five ears furnished a duration measurable in seconds from a″ up; two, where the other ear was normal, showed a duration from a′ up. The lower tones which still were perceived by certain of the ears faded away so rapidly that they could not be measured. With one exception, of which mention will be made later, all of the ears with defects in the labyrinth showed a remarkable similarity in their preserved ranges of hearing from a″ or a′ upward.

The average of tones in the hearing range of the four cases where the other ear was normal gives us a′ = 0 06, a″ = 0.26, f‴ = 0.39, c⁗ = 0.48, f sharp⁗ = 0.53, and in the two cases where the hearing of the other ear was not perfect a′ = 0, a″ = 0.15, f‴ = 0.27, c⁗ = 0.45, f sharp⁗ = 0.54. We thus find a continuous increase of the hearing duration from the lowest to the highest tones within the hearing range.

Under the supposition that some nervous parts of the labyrinth remained to transmit the tone perception in the given ranges, we should not be entitled to expect such an agreement of results, but rather the opposite. If remnants of hearing, they must, in the various parts of the tone-scale, correspond with the size and position of the defects in the labyrinth, and the duration of hearing for the various tones must be an atypical one. The continuity of the hearing ranges, their constant position in the scale, and the gradual increase in the duration with the pitch of the tone would remain unexplained.

On the other hand, all of our results are easily explained by

regarding them as the evidence of the more or less imperfect exclusion of the hearing ear. We may convince ourselves of this by closing both ear-canals with the finger and noticing the tones of the forks employed in the tests. The higher we ascend in the scale, the farther can the vibrating fork be removed from the ear without our losing the sound. We find here an instance of the interesting physiological fact that the intensity with which the ear perceives tones of various pitch is in inverse relation to the amplitude, and in direct relation with the number of the vibrations in the time unit. The law begins to lose its significance near the upper end of our hearing range in the Galton whistle.

In the two cases where the hearing was defective on the other side, the hearing duration on the side with the defective labyrinth were shortened. a′ was heard for so short a time that it could not be counted. f sharp′′′′ alone was heard as long by these as by the others, probably because this tone was heard very long by the other ear, and on account of its rapid extinction did not furnish very reliable results. In the same two cases, the duration of hearing showed a more rapid augmentation than in the remaining four cases. This discrepancy is explainable if we notice that the duration for the same forks for the other ear in one of these cases shows an augmentation corresponding to the middle-ear affections present.

The above mentioned exception, Case No. 3, is of the greatest interest. There is no continuity in the hearing range on the defective side, and there is a gap betwen f′′′ and c′′′′. If we notice the duration of hearing on the other ear of this patient, we see that these two tones show a considerable diminution, namely, to 0.42 and 0 59 of the normal hearing duration, while the two neighboring tones, a′′ and f sharp′′′′, are decidedly longer, nearer the normal 0.86 and 0.82. On the defective side we find a duration for these latter tones similar to the remaining cases where the other ear was normal. By a lucky coincidence, one of the patients with a labyrinth-necrosis showed a gap in the hearing range on the sound side. If we review the various hearing ranges which we have found for the ears with de-

fective labyrinths, we see that they only reflect, more or less completely, the hearing conditions of the sound ears. This proves that an ear without a labyrinth has *no independent hearing power.*

Furthermore, we have found a prototype of how every totally deaf ear reacts to the tests when the other ear possesses relatively normal hearing.

Exact knowledge of the functional condition in one-sided deafness is in future to be counted among the essential foundations for the functional examination of the ear and a correct interpretation of its results. The practical value of a sure diagnosis of one-sided deafness manifests itself in its influence on the prognosis and treatment of the case, and on medico-legal questions.

REPORT ON THE PROGRESS OF OTOLOGY IN THE THIRD QUARTER OF THE YEAR 1897.

By Dr. A. HARTMANN.

Translated by Dr. Arnold H. Knapp.

EAR.

ANATOMY.

203. Donalies. Histology and pathology of the malleus and the incus. *Arch. f. Ohrenheilk.*, vol. xlii., 3, 4.

204. Hammerschlag, V. On the function of the Eustachian tube. (A reply to Lucae's remarks in the preceding volume of the *A. f. O.*) *Arch. f. Ohrenheilk.*, vol. xliii., p. 65.

205. Brühl, G. A method of injection of the temporal bone. *Anatom. Anzieger*, xiii., No. 3.

203. The ossicles consist, principally, of compact bone ; a true spongiosa scarcely exists. In the outer layers the Haversian canals run in line with the axis of the bone ; in the inner layers their course is irregular. The medulla has, in general, the outline of the bone, and is divided into many small spaces by bony septa ; it is present in all bones, and extends to the very tips. The blood-supply is free. Krause.

204. Hammerschlag reiterates his belief that the Eustachian tube is normally open to the respiratory current. Bloch.

That the view of the author, that the middle ear and the naso-pharynx are in open communication, is wrong is shown by the experiments with the pneumatic cabinet, which I described in 1877 in the *Arch. f. Anat. u. Physiol.* When the pressure is increased in the pneumatic cabinet no equalization of pressure between the tympanum and the naso-pharynx takes place during respiration ; this occurs only with deglutition. No air ever enters the tympa-

num with the phonation of pure vowels or palatal notes. In one case only, where the tubes proved to be patent during the state of repose in other experiments, did an equalization take place without the act of swallowing. HARTMANN.

205. The macerated temporal bones are slowly decalcified, washed in water, and dehydrated in alcohol. After closing the porus acusticus int. and the round window, mercury with glycerin is injected into the óval window with a hypodermic syringe until the metal comes out at the aqueductus. The decalcified bone is cleared in carbol-xylol and xylol, and then mounted in the latter fluid. KRAUSE.

PHYSIOLOGY.

206. STUMPF and MEYER, M. The determination of the rate of vibrations of very high tones. *Annalen der Phys. u. Chem.*, N. F., vol. lxi., 1897.

206. The authors have determined the heights of tones by the method of difference in tones in the case of Edelmann's Galton whistle, of Appunn's whistles, and tuning-forks. The conformity of their results with those of König and Melde speaks for the accuracy of the method. A constant air current should be used to blow the whistles instead of a rubber bag. They found that the rates of vibration, as determined with Appunn's forks, were inexact, and that the upper tone-limit does not lie in 50,000 vibrations, as previously accepted, as the highest tones are produced with the Galton whistle at 1.5, which represents about 20,000 vibrations. FRIEDRICH.

GENERAL.

a.—REPORTS AND GENERAL NOTICES.

207. BUSSENIUS. The clinic for diseases of the nose and throat. *Arch. f. Laryngol.*, v.

207. This is a description of the nose and throat department of the Charité, which is under the direction of B. Fränkel; 162 cases were treated during the first half-year. ZARNIKO.

b.—GENERAL PATHOLOGY AND SYMPTOMATOLOGY.

208. GÖPPERT, F. The middle ear of nursing infants in healthy and diseased conditions. (From the University Child's Hospital, Berlin.) *Jahrbuch f. Kinderkrankh.*, vol. xiv., 3.

209. ROHRER. The relations of the diseases of the ear to those of the eye. Haug's *Klinische Vorträge*, vol. ii., 5, Jena, 1897.

210. HAMON DU FOUGERAY. Note sur les diverses lésions de l'oreille, du nez et du larynx que l'on trouve chez les enfants places dans les institutions de sourds-muets ; importance de leur traitement. *Rev. hebdom.*, No. 37, 1897.

208. GÖPPERT has examined the ears of all the nursing infants under one year—73 in number—during a period of two and a half months at the Charité. The results relate chiefly to the middle-ear affections of atrophic babies. Vascular injection of the hammer in the 1st–2d month may be normal. In purulent otitis media, all injection may be wanting, and the diagnosis must be made by the opacity. In 36 autopsies both the antrum and the middle ear contained pus ; no caries. Of 145 ears, only 24.5 % were found healthy on admission, and only 9.7 % remained so. The author arrives at the following conclusions, which apply only to infants in poor general condition :

1. Otitis media is caused by coryza, pulmonary affection, and intestinal derangements ; in fact, by any disease preceded by vomiting.

2. The intestinal disease produces the aural affection by the vomiting rather than by the general marasmus.

3. Meningitis may cause otitis by the vomiting.

4. Otitis media accompanying coryza is the most frequent form to lead to perforation or to clinical symptoms.

5. Otitis media after intestinal troubles is the most benign.

6. The danger of a general infection, or meningitis, is much less than in older persons.

7. Fever or prolonged restlessness is rare, and disappears after paracentesis.

8. During the entire period, no case of convulsions due to the otitis media was observed. Directly after, a case with convulsions was observed, when the convulsions ceased after paracentesis.

9. The mild course of otitis media purulenta in these children is due, according to Kossel, to the free discharge per Eustachian tube.

209. The relation between the diseases of the ear and those of the eye, ROHRER prefaces by quoting Waldeyer's morphological parallel between the two organs : retina, organ of Corti ; choroid, connective-tissue wall of cochlear duct ; sclerotic, bony labyrinth

capsule; conjunctival sac, tympanum; cornea, membrana tympani; nasal duct, Eustachian tube; orbit, bony auditory meatus. Among the points of physiological relationship the author mentions the observation of d'Arsonval, that he became deaf for one to one and a half hours after having looked at an arc light for a few moments. Experimental physiology shows us that ocular movements may be produced by reflex paths from the ears. Cyon produced rotatory movements of the eyes by section of the semicircular canals. Baginski caused nystagmus in rabbits by injecting water into the middle ear. Mention is made of the relation of the ear and eye to the nose, to the intracranial affections (tumors, etc.), to nervous diseases (tabes, multiple sclerosis, hysteria), to general diseases (syphilis, rickets, scrofula). Nystagmus occurs frequently in chronic otitis media (Jansen, Kipp, Urbantschitsch). Obscurations of visual field (Knapp), mydriasis, and hemiopia (Moss) have been noted in Ménière's disease. The most important connection between the two organs is the change observed in the optic disc on intracranial extension of a purulent otitis. Zaufal, as early as 1881, considered operative interference to be indicated at the sign of an optic neuritis. The absence of optic neuritis, on the other hand, does not confirm the non-existence of an intracranial complication, especially of a sinus thrombosis.

BÖNNINGHAUS.

210. H. DU FOUGERAY criticises the lack of special treatment or examination of the inmates in the French deaf-mute institutions. Of 45 children in one asylum, he found 14 to be suffering from diseases of the middle ear, and was able to improve the hearing by appropriate treatment in 13. ZIMMERMANN.

c.—METHODS OF EXAMINATION AND TREATMENT.

211. KUHN, F., Giessen. A sterile, water-proof, adhesive dressing. A contribution to aseptic surgery. *Münch. medic. Wochenschr.*, 36, 1897.

212. V. STEIN, ST. The centrifuge in aural affections. *Studies out of the Bazanova Clinic, Moscow*, vol. i., No. 1, 1897, 43 pages.

213. MARTIN. Du chlorhydrate d'eucaine en rhinologie, otologie, laryngologie, comparé au chlorhydrate de cocaine. *Rev. hebdom.*, 27, 1897.

214. NICHOLS, J. E. H. A self-retaining operating aural speculum. *Transactions American Otological Society*, 1897.

215. VANSANT, E. L. A novel method for the use of dry heat in the middle-ear disease and otalgia. *Journal American Med. Association*, Oct. 9, 1897.

211. The material "Protection" is made by Evens and Pastor, in Cassel. It can also be used to hold back the hair in mastoid operations. SCHEIBE.

212. To test the static and active dynamic function of ear patients, v. STEIN has examined the passive dynamic ocular functions with a centrifugal machine. The apparatus is arranged to seat the patient, and gives a place for the physician who is observing the movements of the eyeball. In the preceding number the author has described the aim of the examination and the results he has obtained in healthy persons and those with ear trouble.

FRIEDRICH.

213. MARTIN prefers eucaine because it is less toxic, and does not cause contraction of the mucous membrane. ZIMMERMANN.

214. The speculum has been devised for examinations and operations of the ear. The interior of the speculum consists of two passages in its larger and outer two thirds, and of one passage in its inner and smaller one third. The upper passage contains a small incandescent lamp of four-candle power. Operations are carried on through the lower passage. The speculum is held in position by a spring head-piece, so that the surgeon has both hands free. GORHAM BACON.

215. VANSANT describes an apparatus which is a modification of an instrument which was first devised for the purpose of dental surgery, consisting of a metallic bulb, or barrel, which contains a piece of carbon, a rubber hand-ball air-compressor, and a long, curved, pointed, steel nozzle. After heating the bulb, a current of air is forced through it by means of the hand-ball.

GORHAM BACON.

EXTERNAL EAR.

216. HAUG. Further contributions on neoplasms of the external ear. *Arch. f. Ohrenheilk.*, vol. xliii., p. 10.

217. COHEN TERVAERT and DE JOSSELIN DE JONG. A lymphangiosarcoma of the external ear. *Arch. f. Ohrenheilk.*, vol. xliii., p. 53.

218. HESSLER, Halle a. S. On rarefying ostitis of the mastoid process after infectious external otitis. *Deutsche medic. Wochenschr.*, No. 29, 1897.

216. A micro-cystofibroma of the cartilaginous auditory canal, a cylindroma of the fossa conchæ, a polyp containing cartilage tissue, springing from the border of the membrana tympani, and finally, elephantiastic hypertrophy of the auricle are fully described both clinically and histologically. BLOCH.

217. A recurring tumor of the auditory meatus situated in the soft part was easily removed after detachment of the auricle.

BLOCH.

218. HESSLER observed two cases of mastoiditis subsequent to an external otitis where the symptoms pointed to an acute empyema of the mastoid antrum. On operating, the antrum was found free from pus, but the bone, especially in the vicinity of the antrum, was discolored, brownish, brittle, but not carious. The operations were successful, though the convalescence was protracted. As the infection process could not have travelled by way of the middle ear, the author is inclined to consider these two cases as constituting a peculiar clinical picture.

NOLTENIUS.

MIDDLE EAR.

a.—ACUTE OTITIS MEDIA.

219. JACK, F. L. Some of the indications for opening the membrana tympani. *Boston Med. and Surg. Journal*, Aug. 19, 1897.

220. LAURENS. Un cas de périostite mastoidienne. *Ann. de mal. de l'or.*, etc., No. 8, 1897.

221. HAUG. Gravitation abscess below the mastoid process, and retropharyngeal abscess subsequent to acute purulent otitis media. *Arch. f. Ohrenheilk.*, vol. xliii., p. 17.

222. LUC. De la pyémie d'origine auriculaire sans thrombosinusite. *La médecine moderne*, July 10, 1897.

223. FORUS. Pourquoi les otites moyennes suppurées sont-elles si fréquentes et les mastoidites si rares. Explication de ce phénomène par des découvertes anatomiques personelles. *Ann. mal de l'or.*, etc., No. 8, 1897.

219. JACK recommends early paracentesis in cases of acute middle-ear inflammation accompanied with severe pain, marked infection, and bulging of the drum-membrane; and also in cases where there is a collection of fluid, either serous or mucous, in the tympanic cavity, following an acute catarrhal inflammation of the

nose and throat. Before puncturing the drumhead, the auditory canal and drumhead should first be rendered aseptic by instillations of a 1:5000 corrosive sublimate solution.

GORHAM BACON.

220. One of those rare cases where, after an acute otitis, a collection of pus was found on the mastoid process, though antrum and the mastoid cells proved to be free from disease. LAURENS does not believe that a mastoiditis at first existed and then recovered, but the infection was carried by the blood-vessels to the periosteum. ZIMMERMANN.

221. The title describes the case. The correct diagnosis and treatment in this case of Bezold's mastoiditis saved the patient's life. BLOCH.

222. LUC reports two cases of otitic pyæmia with symptoms of pyæmia without sinus thrombosis (osteophlebitis of Körner). *1st Case:* A boy, ten years old, was taken ill with a double otitis media after angina, in February, 1892. Paracentesis was performed on both sides with temporary relief. After a few days, a typical pyæmic fever set in, with rigors, rapid rise of temperature, and periods free from fever, which ceased, together with the otorrhœa, in the middle of April. Tenderness in the joints and tendon-sheaths, swelling and redness of the legs followed each attack. Abscesses were formed in the calf, the heel, and the dorsal region of the foot. The mastoid process never was tender. Protracted convalescence, finally cure. The angina, otitis, and abscesses were caused by streptococci. *2d Case:* A boy, eight years old, had otitis media after measles with spontaneous otorrhœa, on February 1, 1897. On February 9 a distinct pyæmic fever set in with rapid rise of temperature and almost daily chills. Notwithstanding a broad opening into the drum-membrane the fever did not stop before February 26. The only metastatic appearance was pain in the left inguinal region and behind the right trochanter on one occasion. No signs of mastoiditis. Rapid recovery.

According to Körner, free otorrhœa, no signs of mastoiditis, metastases in joints and muscles (not in the lungs), good prognosis, are the main points of this form of pyæmia, which usually occurs after an acute otitis and is different from the variety occurring in chronic cases with sinus thrombosis. The author agrees with Körner that these cases are due to a phlebitis of the small veins in the bones surrounding the tympanum and the

antrum, similar to the pyæmia after osteomyelitis of the long bones. BÖNNINGHAUS.

223. FORUS has constantly found in a large number of fresh temporal bones a delicate vertical septum dividing the tympanum in two parts: the one antero-inferior, the tubal part; the other, a postero-superior, the attico-mastoid part. This septum is supposed to be a remnant of the embryonal mucous membrane and stretches like a sail from the ostium of the Eustachian tube between the inner and outer tympanic wall, surrounds the tensor and the chorda tympani, and is attached to the malleus in the form of numerous points and the well-known ligaments. Forus considers this membrane to be present in all fresh temporal bones, and regards it as the main check to the progression of infectious processes from the tube to the mastoid antrum. The resistance of this septum was tested by injecting water through the Eustachian tube; water never entered the antrum unless the septum had been burst under considerable pressure.

ZIMMERMANN.

b.—CHRONIC OTITIS MEDIA PURULENTA.

224. BUCK, A. H. Remarks on the non-operative treatment of chronic suppurative disease of the antrum and vault of the tympanum. *N. Y. Med. Record*, Sept. 25, 1897.

224. BUCK believes that the so-called cleansing method, if patiently and systematically carried out, is sufficient to cure the disease in many cases, rather than the operative method, viz., removal of ossicles and Stacke's method. There are many cases, however, where an operation is necessary, but the writer believes that when the opening in the tympanic membrane through which the pus and the products of disease escape into the auditory canal is fairly large, and particularly if it occupies a high position, there can be no question about the propriety of giving the cleansing method a fair trial. The latter method consists in injections of hydrogen dioxide through curved glass tubes, the removal of all granulation material, cast-off epithelium, etc., and the insufflation of iodoform or other powders. GORHAM BACON.

c.—CEREBRAL COMPLICATION OF PURULENT OTITIS MEDIA.

225. HAEDKE, M. A case of meningitis and epidural abscess due to the influenza bacillus (Stettin City Hospital). *Münch. med. Wochenschr.*, No. 29, 1897.

226. GREEN, J. ORNE. Some of the general principles which should govern operations for otitic brain disease. *Boston Med. and Surg. Journal*, Aug. 12, 1897.

225. Pus in the temporal bone also showed presence of influenza bacilli. The connection between the epidural abscess on the frontal lobe of the brain and the suppuration in the temporal bone could not be established anatomically. SCHEIBE.

226. In otitic brain disease early operation is advisable, but an early exact diagnosis is often impossible.

The chances are 79 in 100 that a fistula through the bone from the ear will lead directly to the brain disease.

The infected ear requires operation in any case, and this operation can be combined with an exploration for the bony fistula and the recognition and treatment of the brain disease.

GORHAM BACON.

d.—MIDDLE-EAR EXTENSION.

227. SHEPPARD, J. E. Mastoiditis without, or with but little, involvement of the tympanic cavity. The *Brooklyn Med. Journal*, July, 1897.

228. LELAND, G. A. Two cases of lateral sinus thrombosis with abscess of internal jugular vein ; operated ; one recovery. One case of isolated thrombosis of bulb ; death. *Transactions American Otological Society*, 1897.

229. MALHERBE. De l'évidement petro-mastoidien appliqué au traitement chirurgical de l' otite moyenne chronique sèche. *Arch. internat. de lar. d'ot.*, No. 2, 1897.

230. MIOT. Opèration faite avec succès dans une cas d' otite moyenne sèche. *Rev. hebdom.*, No. 32, 1897.

231. EITELBERG, A. The treatment of sclerosis with thyroidine tablets. *Arch. of Ohrenheilk.*, vol. xliii., p. 1.

232. HAMON DU FOUGERAY. Un cas d' epithelioma primitif de la caisse du tympan développé à la suite d' un otite moyenne purulente chronique d' autant de 12 ans. *Ann. des mal. de l' or.*, etc., No. 8, 1897.

227. SHEPPARD reports a number of cases and draws the following deductions : A running ear is by no means always a precedent or accompaniment of mastoiditis. The most constant symptoms are pain in the mastoid region and over the side of the head ; tenderness in the mastoid region, especially at the apex,

developed by firm, deep pressure, or by percussion; a distressingly loud tinnitus, variously described by patients as throbbing, beating, puffing, or pumping; a less constant symptom, but of much significance when present, is the bulging of the posterior superior canal wall into the lumen of the canal. The late-appearing external symptoms of mastoiditis, redness, œdema, and pushing out of the auricle, should never be waited for, because of the evident fact that the time thus allowed to the pus to work its way through the outer mastoid cortex gives it the same opportunity for breaking through the inner cortex and involving the intracranial structures. While, as a general rule, where mastoiditis is suspected, it is quite proper for a few days to make use of the usual antiphlogistic abortive measures, still there are many cases where immediate operation should be advised, and as between early and late operation, the former is always the safer course. GORHAM BACON.

228. Two of the cases were those of lateral sinus thrombosis, secondary to acute inflammation of the middle ear, both with abscess of the internal jugular vein; one ending in death, the other in recovery. The third case was one of thrombosis of the jugular bulb, with the sinus free above it, followed by death.

CASE I.—A widow, thirty-two years of age, of neurotic temperament and subject to quinsy sore throats. She had an acute suppurative otitis media with considerable pain. Later there was vomiting with nausea; chilly sensations; right meatus filled with pus; drumhead perforated in the inferior portion. A few days later there was a distinct chill with high temperature. Tenderness developed over the mastoid and the neck became stiff, and there was tenderness over the jugular vein. A week later it was decided to do a Wilde's incision. The symptoms again becoming more alarming, the original Wilde's incision was, about two weeks later, reopened and prolonged. The mastoid cells were broken down and filled with pus. The sinus was exposed. A thrombus was found in the sinus and considerable pus about it. The thrombus was removed. The patient's condition was slightly improved at first, but later she became worse and died. *Autopsy.*—Thrombosis with organization and obliteration of right lateral sinus. Purulent softening of thrombus in beginning of right int. jugular vein. Small, old, adherent thrombus in left lateral sinus. Acute sero-fibrino-purulent meningitis. Old tuberculosis in the apices of the lungs. Streptococci in lateral sinus, and in pus of pia mater of both

sides, and around cerebellum; numerous in colonies and chains; a few in longitudinal sinus.

CASE 2.—A boy, eight years old, had an acute suppurative otitis media, right side, followed by mastoid inflammation and pain in the head. He had a chill, followed by fever and sweating. The mastoid was opened and found soft. There was an epidural abscess and a clot in the lateral sinus. The boy recovered.

CASE 3.—A man, twenty-seven years of age, had chronic purulent otitis media, right side. Four weeks previously there was cessation of discharge and onset of pain over the whole head, with some delirium. Other symptoms developed, viz.: chill, high temperature, some swelling in ant. cervical triangle. The mastoid cells were opened and found to contain fœtid pus. In exposing the sigmoid groove, a considerable amount of foul-smelling pus came away—the contents of an epidural abscess. The mastoid antrum contained cheesy masses and granulations. The thrombus in the sinus began just posteriorly to the jugular bulb, and filled the bulb also. At the junction of the sinus with the bulb, on its upper surface, was a soft spot, where probably the septic material entered the sinus from the mastoid. The patient was not relieved by the operation. A few days later, a trephine opening was made in the skull over the right auricle, but exploration in various directions failed to show any pus. The patient died with symptoms of septicæmia, with cerebral œdema. An autopsy was refused. GORHAM BACON.

229. As the hearing is sometimes improved after operation in chronic purulent otitis, MALHERBE was induced to operate in cases of sclerosis without labyrinthine involvement. On the day following the operation, and occasionally on the same day, the hearing in spite of the thick bandage was improved and the subjective noises had gone. This extraordinary result is said to have remained in two patients even after one year. The author has operated on five cases altogether. ZIMMERMANN.

230. During the last year MIOT has removed the membrana tympani in fourteen cases of sclerosis; he describes the following case: A young man (no age given) heard the watch, left on contact, right in 12 *mm*; after the operation, was able to hear the watch, left in 6 *cm*, right in 18 *cm*; it is not stated whether subjective noises were present or altered, or not. Miot says the hearing of all patients operated upon fluctuated, accord-

ing as the exposed tympanic mucous membrane was caused to swell. The operation is indicated when the affection is bilateral or when it is monolateral with oppressive noises and loss of accommodation (?). ZIMMERMANN.

231. Eight cases were treated with thyroidin; from the given data it is difficult to say whether these were really cases of sclerosis. Though the results were meagre, the author advises continuation of the experiments. BLOCH.

232. A woman forty-three years old suffered with a fœtid otorrhœa, great pain, and frequent hemorrhages from the left ear. An operation was refused and when seen again a few months later the mastoid process was very much swollen. The operation was then undertaken and the middle ear and antrum were found converted into a large cavity, filled with tumor-like masses which had broken through the tegmen. A radical extirpation was impracticable and the patient died in six weeks. No autopsy. The histological examination showed the growth to be a carcinoma of the squamous epithelial type. The tumor had evidently at the beginning been confined to the middle ear and had progressed anteriorly. ZIMMERMANN.

NERVOUS APPARATUS.

233. LEWIS, ROBERT, Jr. A remarkable angio-neurosis of the tongue, due to the application of chromic acid to granulations on the upper and posterior portions of the tympanic membrane. A contribution to the physiology of the chorda tympani nerve. *Transactions American Otological Society*, 1897.

234. BURNETT, C. H. Ear vertigo, from anæmia of the labyrinth. *Philadelphia Polyclinic*, July 10, 1897.

235. BLAKE, C. J. Intra-tympanic disease as a factor in the causation of aural vertigo. *Boston Med. and Surg. Journal*, July 1, 1897.

236. BARNICK, O. On fractures of the base of the skull and the accompanying hemorrhages in the aural labyrinth. *Arch. f. Ohrenheilk.*, vol. xliii., p. 23.

237. KREPUSKA. Primary sarcoma of the Gasserian ganglion, and its relation to the function of the auditory organ of that side. *Sitzungsber. des Gesellsch. der Ungar. Ohren. Kehlkopfärzte*, No. 4, 1897.

238. FRIEDRICH, E. P. Contribution to the study of tabetic deafness. *Verhandl. der deutsch. otol. Gesellsch.*, 1897, pp. 38–48.

233. The case reported by LEWIS was that of a married woman, aged forty-eight, of average good health, not of a nervous temperament, who was suffering from a left chronic otitis media purulenta of some years' duration. On examination, there was found a perforation in the posterior superior quadrant of the drumhead, filled with granulation tissue. The latter tissue was removed with a curette, and the base cauterized with chromic acid. She was directed to syringe the ear with a bichloride solution, to be followed by the instillation of alcohol drops. Later, powdered aristol was insufflated. She complained shortly after this that her tongue suddenly became so swollen that she could hardly breathe for a few hours. The discharge had ceased at this time, and but little was thought of the swelling of the tongue. About six months later, however, there being a renewal of the discharge, it became necessary to cauterize the granulations again. Twelve hours after the application of the chromic acid, her tongue began to swell very rapidly, so that she could not protrude it, nor could she shut her jaws. By the administration of purgatives, the local employment of ice, tannic acid, leeches, etc., about three hours after the œdema first showed itself, the swelling began to subside, and within twenty-four hours after the application of the chromic acid the œdema had practically disappeared. Accompanying the glossal œdema and the œdema in the submaxillary region, there were small areas of œdema over the right frontal eminence, over the balls of both thumbs, over the internal malleolus of one ankle-joint, and under the ball of the right foot.

GORHAM BACON.

234. Anæmia of the labyrinth, causing deafness, tinnitus, and vertigo, may be diagnosed in two ways, viz.: by the temporary congestion induced by eating, and also by the inhalation of nitrite of amyl. If temporary improvement in all or any of these symptoms ensues after eating or after the inhalation of a few minims of nitrite of amyl, the conclusion is that the case is one of chronic anæmia of the labyrinth, and that the case may be beneficially treated by doses of trinitrin $\frac{1}{100}$ grain two or three times daily.

GORHAM BACON.

235. The writer believes that the sense of degree of disturbance of equilibration is, all other things being equal, in definite relationship to the degree of fluid displacement induced by mechanical causes, and, second, that the auditory nerve offers no exception to the general rule of acquired toleration of a dis-

turbing influence of a degree within the possible limits of compensation.

The writer reports two cases of aural vertigo, in one the cause being due to the presence of granulations about the stapes, and in the other, to cholesteatomatous masses about the incus and stapes. Both cases were relieved of the vertigo by removing the granulations in the one and the cholesteatomatous masses in the other.

GORHAM BACON.

236. CASE 1.—Fatal fall on occiput, transverse fracture of the right petrous bone, fissure through roof of antrum with blood in tympanum, hemorrhages in the trunks of the acoustic and facial nerves, in the basal winding of the scala vestibuli, the bony canals of the labyrinthine nerves, and in the region of the maculæ acousticæ.

CASE 2.—A fall of twelve feet; death four hours later. Fracture of the right squama passing through the upper wall of the canal and the tegmen tympani, rupture of the drum-membrane, fissure in the floor of the auditory canal and the tympanum to the post. lacerated foramen, separation of apex of petrous bone, numerous hemorrhages in vestibule and semicircular canal, in the Fallopian and other canals. Cochlea normal.

CASE 3.—Rapidly fatal fall of nine feet. From the occipital bone numerous fissures pass outward in both petrous bones; R. through the apex; L. through the tegmen tympani. Blood in pneumatic spaces of both sides. L. the fracture passed through the round and the oval windows, leaving both widely open. Cochlea contained hemorrhages.

CASE 4.—Jump from a moving train, fracture of base, death in two days. R. petrous bone separated from the squamous portion and the mastoid process. Tear through membrana flaccida, dislocation of both joints, hemorrhage in all pneumatic cavities, in the cochlea, in the trunk of the auditory and the nerves of the semicircular canals.

Five further cases are described which terminated favorably, though a fracture was probable. BLOCH.

237. The history and autopsy report of a case of alveolar sarcoma of the right Gasserian ganglion with numerous metastases. The intense otalgia with which the disease began is diagnostically important for disease of the trigeminus. The increasing deafness and tinnitus on the affected side are regarded by the author as a reflex action of the fifth nerve on the terminal portion of the eighth nerve. FRIEDRICH.

238. The views in regard to the site and kind of lesion in tabetic deafness are still divided. This deafness has been supposed to be due to atrophy of the auditory nerve, to atrophic disturbance of the middle ear caused by a tabetic affection of the trigeminal nerve, or finally to a syphilitic disease. Based on the reported autopsies and clinical histories the author thinks that the most frequent form of the affection with gradual onset and leading to marked nerve-deafness is due to a lesion in the primary neurone of the acoustic tract. Thus the process must begin in the peripheric terminations of the auditory nerves, and is analogous to the atrophies of peripheric sensory nerves observed in tabes. Concerning the apoplectiform variety with the Ménière symptom-complex, the author is of the opinion that it is probably a disease of the acoustic nuclei, and that the clinical picture is a form of auditory crisis.

NOSE AND PHARYNX.

a.—ANATOMY.

239. BERGEAT, M., Munich. The air cells in the middle turbinated bone. *Münch. med. Wochenschr.*, No. 35, 1897.

239. The author has found that air cells are found much more frequently in the middle turbinated bone than has previously been supposed. He differentiates between air spaces which are only contained in the middle turbinated, those which communicate with the sup. nasal meatus and have only been shut off by the middle turbinal, and those which have been caused by adhesions between the middle turbinal and the septum. In forty cases of cellular turbinals, pus was found three times. KRAUSE.

b.—METHODS OF EXAMINATION AND TREATMENT.

240. LICHTWITZ, L., Bordeaux. Illumination with acetylene gas in laryngology, rhinology, and otology. *Münch. med. Wochenschrift*, No. 39, 1897.

241. MINK, P. J., Zwolle. A nasal forceps. *Arch. f. Laryngol.*, vol. vi., No. 1.

242. SCHEIER, MAX, Berlin. On the use of X-rays in rhinology and laryngology. *Arch. f. Laryngol.*, vol. iv., No. 1.

243. LINDT, W., Bern. The direct inspection and treatment of the naso-pharynx. *Arch. f. Laryngol.*, vol. vi., No. 1.

244. JANKAU, L., Munich. A new nasal speculum and inspirer. *Arch. f. Laryngol.*, vol. vi., No. 1.

245. WANDLESS, H. W. Curettes for operating in the naso-pharyngeal vault. *Journal Amer. Med. Associat.*, July 17, 1897.

246. WANDLESS, H. W. New intranasal instruments. *N. Y. Med. Journal*, Aug. 21, 1897.

240. LICHTWITZ prefers acetylene gas to the Welsbach or the electric light. It is also cheaper, and without danger.

SCHEIBE.

241. MINK has devised a delicate forceps similar to Juracz's, to remove polyps and hypertrophies of the post. ends of the turbinals through the nasal passages. ZARNIKO.

242. On the plate of barium-platinum cyanide held parallel to the median line next to the head of the patient, the antrum of Highmore appears a lighter area, the frontal sinuses are sometimes quite transparent, and the sphenoidal cells cannot be recognized. Foreign bodies in the nose or in the accessory cavities are noticeable if they prevent the passage of the X-rays. The various shades of lightness in the accessory cavities are as inexact as in transillumination with ordinary light. In a case of purulent discharge from the nose, a foreign body (a bullet in the frontal sinus) was supposed to be the cause; the X-ray photograph showed that the bullet was lodged near the Gasserian ganglion.

ZARNIKO.

243. LINDT has suggested, independent of Katzenstein, a method for the direct view of the naso-pharynx. After the post. pharyngeal wall and the soft palate have been cocainized, the soft palate is drawn forcibly forward with a special hook, and the patient's head is thrown back. The middle recess of the pharyngeal tonsil can then be seen in favorable cases, also a part of Rosenmüller's fossa, the salpingo-pharyngeal plica, and the pharyngeal mouth of the Eustachian tube. These parts can be easily treated locally. The author considers this method as a supplement, the indirect rhinoscopy. ZARNIKO.

244. An egg-shaped instrument of vulcanite is inserted in the vestibulum nasi, so that the lateral opening is directed down and the rounded pole looks back; it is supposed to hold the alæ nasi apart easier than the instrument of Feldbauschi. This instrument can also serve as an inhaler. ZARNIKO.

245. WANDLESS devises a pair of curettes, each of two different sizes. One pair with a flat curve is adapted only to the pos-

terior wall of the pharynx; the other, set at an angle of 45° to the handle, for the removal of adenoids from the roof of the vault. M. TOEPLITZ.

246. WANDLESS devised (1) for the removal of small spurs or uneven portions after operations, an intranasal rasp, made right and left; (2) a pair of new nasal saws, with low teeth wider than the blade, cutting with both to and fro movements, made of stiff metal, and having a narrow point; (3) a pair of groove-saws, round, with teeth on convexity, to substitute the knife, gouge, or punch. M. TOEPLITZ.

c.—OZÆNA.

247. MENDELSOHN, Dr. MARTIN. On ozæna and the treatment with interstitial cupric electrolysis. *Monatschr. f. Ohrenheilk.*, No. 8, 1897.

248. BRINDEL. The treatment of ozæna with interstitial electrolysis. *Rev. hebdom.*, Nos. 34 and 35, 1897.

249. COMPAIRED. The new treatment for ozæna. *Ann. des mal. de l'or., du lar.*, No. 5, 1897.

250. MOURET. On the treatment of ozæna. *Rev. hebdom. de lar., d'ot.*, No. 38, 1897.

247. MENDELSOHN's experience with electrolytic treatment of ozæna in ten cases was not favorable. The temporary improvement consisted in diminution of the fetor and removal of the crusts. One mild case seemed to be cured after five months. On the day of treatment and on the following days, pain in the face and head was complained of. KILLIAN.

248. BRINDEL has tried Bayer's method of treatment with electrolysis in 30 cases, and concluded that permanent relief is not obtained. During the first two weeks there is some improvement in the symptoms, but relapses soon come on again. He believes to have obtained better results with massage of the mucous membrane and subsequent application of the nitrate of silver. ZIMMERMANN.

249. The author warmly recommends the serum therapy. The injection dose is 5 to 6 cubic *cm*; the subjective symptoms disappeared after the third injection; the objective symptoms somewhat later. He has thus far treated 27 cases of ozæna with good results. ZIMMERMANN.

250. A complete clinical history of an ozæna patient. The secretion contained streptococci, diplococci, and a peculiar bacil-

lus. The treatment consisted in cleansing and insufflation of aristol; later massage, and cauterization with zinc chloride. Then serum injections were practised, and finally electrolysis, also without result. ZIMMERMANN.

d.—SEPTUM.

251. POLLAK, J., Vienna. On perichondritis serosa of the nasal septum. *Wien. med. Wochenschr.*, No. 27, 1897.

252. COLONNA-WALEWSKI, A. DE. Abscess of the septum. Paris, G. Steinheil, 1897.

251. POLLAK believes that a primary inflammation of the quadrangular cartilage is the etiological factor in the perichondritis serosa, as well as in the hematoma and the ac. idiopathic perichondritis. The process is similar to that which has been described for the auricular cartilage as the cause for the othæmatoma by Parreidt, L. Meyer, Gudden, and Pollak, and consists in a degeneration of the cartilage, softening, vascular new formation. POLLAK.

252. COLONNA-WALEWSKI gives a complete picture of the abscesses of the septum from 36 cases, some of which are new. The origin is usually traumatic and succeeds a hematoma. In the idiopathic cases the infection takes place through very small ulcerations. The treatment is incision and gauze packing. HARTMANN.

e.—OTHER AFFECTIONS OF THE NOSE.

253. SEIFERT, Würzburg. Rhinitis nervosa. *Münch. med. Wochenschr.*, No. 36, 1897.

254. JOAL. Epistaxis dues aux odeurs. *Rev. hebdom.*, No. 26, 1897.

255. SACHS, R., Hamburg. Primary tubercular tumor of the nose and larynx; operation; cure. *Münch. med. Wochenschr.*, No. 38, 1897; supplement No. 42.

256. MILLIGAN, WM. A large exostosis removed from the right nasal passage. *Brit. Med. Jour.*, Aug. 7, 1897.

257. CAMPBELL, J. T. Croupous rhinitis. *Annals of Otology, Rhinology*, etc., August, 1897.

253. After a review of the well-known symptoms, SEIFERT states that he always found nervousness present in his cases. During the quiet periods the mucous membrane appeared pale but very relaxed; during an attack one or both lower turbinates

are swollen, the mucous membrane remains pale, and the epithelium is still more relaxed. Cocaine has but little effect on the swelling. SCHEIBE.

254. In three nervous persons hemorrhages ensued from the nose after the smell of flowers, of incense, of petroleum, and of various perfumes. The objective signs are slight; in one case it could be directly observed that the lower turbinals became injected, with sneezing and hypersecretions. It is probably a vasomotor process, which can lead to a congestion or rupture of the blood-vessels. ZIMMERMANN.

255. The tumor in the nose originated in the cartilaginous septum and contained tubercles, and in places cheesy parts. Bacilli were not found. Lungs normal. Healing after curetting and lactic-acid application. In one case the tubercular growth was bilateral. The largest tumor measured 6 *cm* by 2½ *cm.* SCHEIBE.

256. At a meeting of the British Laryngological, Rhinological, and Otological Association, held on July 16th, MILLIGAN showed an exostosis measuring 1½ by 1¼ inches, and weighing 9 drachms, which had been removed from the right nasal passage by means of an incision along the side of the nose; it projected upwards through the right lachrymal bone, displacing the lachrymal duct, and was found to spring from the right orbital plate of the superior maxilla, and to have grown upwards and outwards, destroying the lachrymal bone, filling up the antrum, and almost completely occluding the nasal passage; its pedicle, ¼ inch in length, had become gangrenous and the exostosis lay free in the cavity it had formed. The patient made an excellent recovery. CHEATLE.

257. CAMPBELL gives a complete review of the literature on fibrinous rhinitis, from which he collects 120 cases, including four of his own observation, eighty of which were bacteriologically examined. Sixty-five cases presented Klebs-Loeffler bacilli associated with streptococci and staphylococci, one with Fraenkel's pneumococcus, and one with erysipelas. In two thirds of all the cases fibrinous rhinitis must be recognized as local diphtheria. M. TOEPLITZ.

f.—NEW FORMATIONS IN THE NOSE.

258. MACDONALD, GREVILLE. Injections of chromic acid for nasal polypi in a hæmophylic. *King's College Hospital Reports*, vol. iii., 1897.

259. LICHTENBERG, K., Budapest. Removal of a nasal polyp, ac. otitis media, otogenous abscess of the middle fossa; antrectomy; trephining of skull; recovery. *Wien. med. Wochenschr.*, No. 29, 1897.

260. FINDER, GEO., Charlottenburg. Some remarks on malignant tumors of the nose. *Arch. f. Laryng.*, vol. v.

258. MacDONALD's patient was a man aged thirty, who had both nostrils blocked with large polypi; he had had them removed at two hospitals at various times; the hemorrhage, even when the galvano-cautery was employed, was so great that plugging had to be resorted to. Injections with a hypodermic needle of a solution of chromic acid (10 grains to the ounce) were tried, from 5 to 10 minims being injected into the polypi of each nostril at a sitting. After three or four sittings he could breathe quite comfortably, and the treatment was continued, with still more rapid results, by thrusting a grooved needle, on which was wound a film of cotton wool, into the bases of the polypi, the needle with the cotton wool having been previously dipped into a saturated solution of chromic acid. The patient never suffered from any pain or irritation of the nostrils.

ARTHUR CHEATLE.

259. After removal of a nasal polyp an ac. otitis media set in with fever, delirium, vomiting, insomnia, and headache. There was a small perforation in the upper and posterior quadrant with continuous discharge of pus. On operating, the mastoid was found carious at a depth of $\frac{3}{4}$ *cm*, but antrum contained no pus nor any fistulous tract. A trephine opening was then made over the temporal line and considerable pus escaped from a subdural abscess. Recovery. POLLAK.

260. Among 28,000 patients at Fränkel's clinic, the author found ten unquestionable cases of sarcoma of the nasal passages (two round-celled, two spindle-celled, one epithelioma), and several uncertain cases. This shows the relative frequency of sarcoma. He advises great circumspection in the question of metamorphosis of benign to malignant tumors; the observations are usually erroneous. The author emphasizes with Dreyfuss the frequency of hemorrhages in sarcoma and their rarity in carcinoma. Carcinomata tend to slough; the sarcomata lead to protrusion of the bones. He was unable to agree with Dreyfuss that carcinoma showed little tendency to involve regionary lymph glands and that the sarcoma frequently produced metastases. The diagnosis is often

difficult. Prognosis in carcinoma is absolutely bad, in sarcoma somewhat better, as operative interference may insure freedom from recurrence for years. Carcinoma should not be operated upon ; a careful institution of nasal breathing is the best that can be done. ZARNIKO.

g.—AFFECTIONS OF THE ACCESSORY CAVITIES.

261. ALEXANDER, A., Berlin. Nasal polypi, their relation to the empyemata of the accessory cavities. *Arch. f. Laryng.*, vol. v.

262. ALEXANDER, A., Berlin. Mucous cysts of Highmore's antrum. *Arch. f. Laryng.*, vol. vi.

263. PHOTIADES. A new after-treatment for empyema of the accessory nasal cavities. *Ann. des mal. de l'or., du lar.*, No. 5, 1897.

264. ESCAT. Contact illumination of the maxillary sinus or retromaxillary illumination. *Rev. hebdom.*, No 28, 1897.

265. LUC. Acute traumatic suppurative meningitis checked by opening of the skull and antiseptic irrigation of the pia. *Arch. internat. de lar., d'ot.*, No. 2, 1897.

266. SCHEPPEGRELL, W. The treatment of suppurative diseases of the accessory sinuses and of the ear by ozone gas. *Med. News*, July 31, 1897.

267. FEHLEISEN, F. Diagnosis and treatment of affections of the frontal sinuses. *Medical Record*, August 7, 1897.

268. MYLES, ROBERT C. Diseases and treatment of nasal accessory sinuses. *Medical News*, August 7, 1897.

269. HOWARD, W. T., and INGERSOLL, J. M. Notes on the etiology of inflammation of the accessory sinuses. *Medical News*, Sept. 25, 1897.

270. WÜRDEMANN, H. V. Empyema of the maxillary, ethmoidal, and sphenoidal sinuses, attended by general septicæmia, following attempted removal of inferior turbinated body ; operations ; recovery. *Annals Otology*, etc., August, 1897.

261. ALEXANDER has examined the accessory cavities in 274 cases at Fränkel's clinic: 69 cases of nasal polypi without empyema, 125 empyemata without polypi, and 80 cases of empyemata with nasal polypi. In these the antrum of Highmore was diseased 57 times, the ethmoid cells 8 times, the sphenoidal cells 5 times, and the frontal cells once. A middle

turbinal containing bony cells with pus and showing œdematous swelling and polyp-formation was examined microscopically in serial sections. The results of Hajek, *Arch. f. Laryng.*, vol. iv., were confirmed. The author regards polypi as inflammatory new-growths. ZARNIKO.

262. ALEXANDER obtained serous fluid by aspiration from the maxillary antrum in six patients; in four the antrum was broadly opened and showed that the serum came from mucous cysts. Neither the subjective nor the objective symptoms are sufficient to make the diagnosis of mucous cysts. They are usually not discovered before aspiration or opening of the cavity is practised. ZARNIKO.

263. PHOTIADES thinks that by free ventilation the duration of frontal sinus empyema can be shortened, and inserts a silver drainage-tube with lateral openings. ZIMMERMANN.

264. ESCAT has devised a small 4-volt light to be placed behind the last upper molar and so transilluminate the maxillary antrum from behind forward. In three cases where the transillumination from the mouth showed shadows, he was able by his method to show a transparent cavity, and once to confirm the shadow found by the usual method. ZIMMERMANN.

265. A woman, thirty-three years old, was operated upon for a tumor at the upper and inner eyebrow with apparent success four years ago. The swelling returned, with pain and exophthalmus. At operation, the outer wall of the frontal sinus was soft and protruding, the bone eroded. A colloid material was evacuated, and the cavity contained fungous masses which had perforated the lower side. Curettage, cauterization, drainage to nose, closure of external wound. The symptoms persisted, and as the fungous masses proved to be sarcomatous, a wide opening into the orbit was made, and the tumor masses were thoroughly scraped; drainage to nose, external closure. The exophthalmus was relieved, but intermittent fever, pain, and general weakness led to a third operation. Behind the healthy dura a square *cm* of purulently infiltrated pia was found, but no abscess. Later two abscesses in the frontal lobes were found. Further remarks on this case are promised. ZIMMERMANN.

266. SCHEPPEGRELL has made a number of tests with oxygen gas, as recommended by Dr. George Stokes, but his results were unsatisfactory. He describes an apparatus for generating ozone, which he has used in chronic antral disease, in a case of combined

empyema of the frontal and maxillary sinuses, three cases of chronic otitis media, and two cases of ozæna. He claims to have had remarkably good results from its use. GORHAM BACON.

267. FEHLEISEN differentiates, like Kuhnt, a sinusitis catarrhalis, blennorrhoica, pyorrhoica, and capsulated empyema, without drawing strict lines between them. The etiological factors are *infection*, by simple coryza or infectious diseases (measles, diphtheria, typhoid fever, pneumonia, influenza, and syphilis), *traumatism*, and tumors, parasites, or foreign bodies. For diagnosis he lays great stress upon Kuhnt's sign of tenderness of the bone upon pressure, particularly at the floor of the sinus. He thinks the importance of the obstruction of the ductus naso-frontalis to be greatly overrated. He prefers the operation from in front for radical operation, but only after opening the ductus naso-frontalis by sounds, and after removal of the anterior end of the middle turbinal. In radical operations the duct is left untouched, if found to be closed. M. TOEPLITZ.

268. MYLES has opened six frontal sinuses externally; in one case through the anterior wall of the ethmoid cells and the floor of the sinus. Two cases of fronto-ethmoidal necrosis were opened through the nose by removal of the anterior end of the middle turbinated body, the internal wall of the infundibulum, and part of the floor of the frontal sinus. In eight out of ten cases, there existed polypoid degeneration, which caused, according to Myles, but against the reviewer's views, two thirds of the ethmoid cases, the others being due to atrophic rhinitis, to non-syphilitic necrosis by retention of pus, and to syphilis and tumors. Three cases of sphenoidal empyema were opened through the upper wall; two were of polypoid, one of syphilitic, origin. The treatment is expectant, explorative, and radical. The different methods, through the alveolus, canine fossa, between hard palate and alveolus, or through malar ridge, are all good in suitable cases.

M. TOEPLITZ.

269. Among eighteen cases examined, the antrum Highmori was involved in fifteen, with a total of seventeen antra, alone in eleven, combined with ethmoid or frontal affection in three and one, respectively. Three antral cases were acute, two after influenza. The different bacilli causing these conditions are well established for each case, and the reader is referred for the details to the original. The chronic cases were due to influenza, coryza, pneumonia, syphilis, dental caries, and atrophic rhinitis; nasal

polypi were present in three cases. In three cases the frontal sinuses were affected, in two alone, in one combined with antral and ethmoid affection, and their bacteria were fully described. Primary inflammation of frontal sinuses is not uncommon; inflammation of ethmoid cells, however, is, according to authors, observed only as secondary to antral or frontal disease.

M. TOEPLITZ.

270. A young man, æt. twenty-four, was operated for supposed polypi and hypertrophy of the left inferior turbinated body, with forceps, snare, and saw, during eighteen hours. Seven days later, when first seen by WÜRDEMANN, pain had developed in left side of face, with swelling of left face and neck, exophthalmus, chemosis, prolapse of conjunctiva, pus from left nostril, 101.3° F. After opening the maxillary antrum from the nose and canine fossa, and the ethmoid and sphenoid sinuses from the nose, the condition was impaired, and only improved thirteen days later by incision in suborbital furrow, through which two and a half ounces of foul pus were discharged. M. TOEPLITZ.

NASO-PHARYNX.

271. SIEBENMANN, Bâle. On adenoid habitus and leptoprosopia, and on the short septum of the chamæprosopes. *Münch. med. Wochenschr.*, No. 36, 1897.

272. ARROWSMITH, H. A clinical study of 701 cases of naso-pharyngeal adenoids observed in 2000 dispensary patients. *N. Y. Med. Journ.*, August 28, 1897.

273. BECKMANN, H., Berlin. On the pathology and therapy of the pharyngeal tonsil. *Monatschr. f. Ohrenheilk.*, No. 9, 1897.

271. SIEBENMANN, after a number of measurements which are described in a dissertation of Fränkel, holds the generally accepted view, that the arching of the hard palate occurs more frequently in individuals with adenoids than in those with a healthy naso-pharynx, to be erroneous. Individuals with arched palates have narrow nasal passages, hence are troubled more with insufficient breathing space than those with low palates and wide noses. Facial measurements of adenoid patients have shown that the face and nose are narrow (leptoprosopia) when the palate is high and broad, chamæprosopia, when the palate is low.

SCHEIBE.

272. ARROWSMITH finds among 2000 patients, 858, or 42.9 per cent., subject to chronic hyperplasia of the faucial, pharyngeal, or lingual tonsils. The hyperplasia is more common in the female sex, particularly as lingual tonsils. Up to the fifteenth year of age the males are suffering more from adenoids (283 : 209); in later periods, the proportion is reversed. Adenoids alone were observed in 18.4 per cent.; adenoids and tonsils in 16.65 per cent.; tonsils alone in 5.05 per cent.; and lingual tonsils in 2.8 per cent. M. TOEPLITZ.

273. BECKMANN removed adenoids with his own instrument down to the basilar fibro-cartilage, and sometimes a thin layer of this is also removed. He operates in 50 per cent. of the patients that come to his clinic, and thus has performed the operation 5000 times. He considers the previous methods of operating to be insufficient, and that the operation is not often enough performed. In his mind, adenoids are the beginning of most of the diseases of the upper air-passages and the ears. Acute coryza is a primary inflammation of the pharyngeal tonsil. Angina lacunaris and peritonsillar abscess are secondary to disease of this tonsil. The pharyngeal tonsil is an etiological factor in chronic catarrhs of the nose, pharynx, and larynx, in granular pharyngitis, ear trouble, etc. The author operates on children with acute coryza and acute otitis when they are over three weeks old. In 1893, 63 children under one year were operated on. Infections after operation have occurred. The frequency of post-operative hemorrhage is not stated. KILLIAN.

SOFT PALATE, PHARYNX, AND BUCCAL CAVITY.

274. BLODGETT, ALBERT N. Entire destruction of soft palate and velum by syphilis. *Boston Med. and Surg. Jour.*, Aug. 5, 1897.

275. GAREL. Intermittent paresis of the soft palate in neurasthenia. *Rev. hebdom.*, No. 33, 1897.

276. HEGMANN, P. Stricture and adhesions of the pharynx and naso-pharynx. Reprint of the *Handbuch d. Laryng. u. Rhinol.*

277. MIKULICZ, J., and KÜMMEL, W., Breslau. I. Diseases of the mouth. II. Local diseases of the mouth. Reprinted from the *Twentieth Century Practice.*

278. RENNER, W. S. Chronic follicular tonsillitis. *Med. Record*, Aug. 28, 1897.

279. GLEITSMANN, J. W. Treatment of chronic affections of the faucial tonsils. *N. Y. Med. Jour.*, Sept. 4, 1897.

274. A boy, æt. fourteen, was infected with syphilis three and a half years ago, by vaccination with humanized virus, and as the result had lost the velum and soft palate, the defect being of irregular contour with indurated and undermined margins.

M. TOEPLITZ.

275. GAREL has observed three cases of intermittent paresis of the soft palate. Speech would suddenly become nasal, and in swallowing, particles of food would enter the nose. On examination the soft palate was vertical and immovable. No previous history of diphtheria, and the paralysis would disappear in several seconds or minutes. Neurasthenia was present in all cases. In the treatment, faradization was of no benefit.

ZIMMERMANN.

276. Uniform narrowing of the pharynx and naso-pharynx, according to the author, produce symptoms more often than is supposed. A description of stricture due to abnormal membranous formation, deformities of the vomer, and lordosis, and finally those due to cicatrization are discussed. They are most often due to syphilis; in some regions they are produced by scleroma; also by lupus and diphtheria, and occasionally traumatism. In conclusion the treatment is discussed.

PASSOW.

278. RENNER distinguishes the chronic follicular tonsillitis, which is characterized by the formation of plugs of secretion in the crypts of hyperplastic tonsils—the plugs being yellowish white, offensive, of cheesy consistence, and composed of leucocytes, epithelium, chalk, mucus, various bacteria, and leptothrix—from mycosis of the tonsils with dense projections like cockspurs made up entirely of leptothrix or other mycotic growth, recurring rapidly when removed. For diagnosis the anterior pillar is to be pulled forward. Cases with varied and obscure symptoms are cited. M. TOEPLITZ.

279. GLEITSMANN describes the chronic inflammation of the follicles of the faucial tonsils, in which they present an irregular contour, with destroyed follicles, the lacunæ filled with white masses. The inner surface and the uppermost (velar) portion of the tonsil is brought into view by a palate hook. The crypts are opened with Mor. Schmidt's hook, but with sharpened edges, also used for the separation of adhesive pillars. Associated with the

above-described condition is a fold on the tonsils. This is best removed by a modification of Ruault's punch, with considerably smaller blades, now cutting in a horizontal plane. The same instrument, still smaller, may be used as a conchotome.

M. TOEPLITZ.

MISCELLANEOUS.

THE AMERICAN OTOLOGICAL SOCIETY will meet July 19th at the Pequot House, New London, Conn.

AMERICAN MEDICAL ASSOCIATION, Pres., GEO. M. STERNBERG, Washington, D. C. Place of meeting, Denver, Colo., June 7–10, 1898. Section of *Laryngology and Otology*, Pres., B. ALEX. RANDALL, Philadelphia, Pa.; Sec., S. E. SOLLY, Colorado Springs, Colo.

We received the following announcement, which we heartily endorse.—ED.

138 CLINTON STREET, BROOKLYN, N. Y.

DEAR DOCTOR:—It is the desire of the undersigned to bring out in the immediate future a "Review of the Work in Otology during 1897," on the plan of Blau's similar work in German. This "Review" will consist of a thorough résumé of the work published; conflicting opinions and deductions being placed in comparison; work involving new researches, new methods, and new ideas being treated *in extenso*. In other words, the desire is to make this work a review from the aurist's standpoint, containing the gist of the year's work in otology, and written in such manner that, in general, the reader will not find it necessary to refer back to the original article for explanation or amplification, as has invariably been necessary in the case of the reviews on otology published in English heretofore.

In order to bring out this work, it is necessary that a certain number of subscribers pledge themselves to purchase the book: the price has been fixed at five (5) dollars per copy.

Will you kindly sign enclosed blank and fill out slips and return as soon as possible to address given. Very truly yours,

H. A. ALDERTON.

Messrs. LEA BROTHERS & CO., Philadelphia and New York, announce for early publication:

A MANUAL OF OTOLOGY. By GORHAM BACON, A.M., M.D., Professor of Otology in University Medical College, New York. In one handsome 12mo volume, with numerous illustrations.

DISEASES OF THE NOSE, THROAT, NASO-PHARYNX, AND TRACHEA: A Manual for Students and Practitioners. By CORNELIUS G. COAKLEY, M.D., Professor of Laryngology in University Medical College, New York. In one volume, 12mo, of about 400 pages, with numerous illustrations, many of which are in colors.

BRITISH NOTES.

The ROYAL VICTORIA EYE AND EAR HOSPITAL, Dublin. Her Majesty the Queen has been graciously pleased to direct that the institution recently formed

under the Act of Parliament, which amalgamated ST. MARK'S OPHTHALMIC HOSPITAL, Lincoln-place, and the NATIONAL EYE AND EAR INFIRMARY, Molesworth St., shall be called the ROYAL VICTORIA EYE AND EAR HOSPITAL, Dublin.

BEQUESTS, ETC.

The late Mrs. ELLEN H. HARRIS has bequeathed £1,000, and the late Mr. JAMES BILLING £500 to the THROAT HOSPITAL, Golden Sqr.

The record collection in aid of the Cork Hospitals has amounted to £3,350, of which £400 has been allocated to the EAR, EYE, AND THROAT HOSPITAL, by the Executive Committee.

The late Mr. B. I. BARNATO bequeathed £1,000 to the JEWS' DEAF AND DUMB HOUSE.

HONORS AND APPOINTMENTS.

FELIX SEMON, Esq., M.D., late Laryngologist to ST. THOMAS'S HOSPITAL, and President of the Laryngological Society of London, has received the honor of Knighthood from Her Majesty the Queen. We beg to offer him our sincere congratulations.

CONNAL, J. G., M.B., M.S., Glasgow, has been appointed a physician to the Throat and Nose Department of the GLASGOW CENTRAL DISPENSARY.

LAKE, R., F.R.C.S., has been appointed Surgeon Laryngologist to the NORTH LONDON HOSPITAL FOR CONSUMPTION, Hampstead.

PAGET, STEPHEN, M.A., F.R.C.S., has been appointed Aural Surgeon, and Lecturer on Laryngology and Otology to the MIDDLESEX HOSPITAL, London.

KERR, J., M.A., M.D. Cantab., D.P.H., has been appointed Honorary Surgeon to the BRADFORD EYE AND EAR HOSPITAL, *vice* J. H. BELL, M.D., appointed Consulting Surgeon.

POTTER, E. FURNISS, M.D. (Brŭx), M.R.C.S., L.R.C.P., has been appointed Assistant Surgeon to the LONDON THROAT HOSPITAL.

WAGGETT, E., M.B., has been appointed Assistant Surgeon to the LONDON THROAT HOSPITAL.

LAKE, R., F.R.C.S., has been appointed Assistant Surgeon to the ROYAL EAR HOSPITAL, London.

YEARSLEY, MACLEOD, F.R.C.S., has been appointed Assistant Surgeon to the ROYAL EAR HOSPITAL, London.

THE ULSTER EYE, EAR, AND THROAT HOSPITAL.

A new wing has recently been opened at this Hospital. The extension comprises eight new private wards, new day-rooms, a new operating-room, new bath-rooms, etc.

BRITISH LARYNGOLOGICAL, RHINOLOGICAL, AND OTOLOGICAL ASSOCIATION.

The following are the office-bearers for the ensuing year: President, Dr. DUNDAS GRANT; Vice-Presidents, Mr. F. MARSH, Mr. G. C. WILKIN, Dr. J. DAVISON; Council, Dr. W. MILLIGAN, Dr. A. B. KELLY, Mr. WYATT WINGRAVE, Dr. WM. HILL, Mr. P. JAKINS, Dr. H. WOODS, Mr. R. LAKE; Hon. Treasurer, Dr. MACNEIL WHISTLER; Hon. Secs., Mr. ST. GEORGE REID, Dr. F. POTTER.

We notice that *The Laryngoscope*, which has met with apparently rapid success in America, is to be issued in Great Britain with the co-operation of Dr. ST. CLAIR THOMSON, Surgeon to the ROYAL EAR HOSPITAL, London, and other associate editors and contributors in different parts of the world whose names guarantee good work. The special aim of the paper is to supply interesting matter on the subjects of Diseases of the Nose, Throat, and Ear to General Practitioners, who are becoming more aware of the importance which these subjects possess. The first joint number will appear in January, 1898. It will be issued monthly, the price being one shilling per month, or ten shillings per annum, post free, prepaid. We welcome *The Laryngoscope* and wish it every success.

Contents of the Latest Number of the Zeitschrift für Ohrenheilkunde.

Vol. XXXII., No. 3. Issued March, 1898.

18. Prof. PASSOW, Heidelberg. On the retro-auricular opening after the radical operation of chronic middle-ear suppuration (illustrated).

19. OLE BULL, Christiania. Lipoma of external ear canal.

20. H. PREYSING. Otitic and rhinitic sinus and general affections. Further, on central deafness in intracranial purulent inflammations. (From the Rostock Ear and Throat Clinic.)

21. F. VOSS, Riga (Russia). A new symptom in obstructing thrombosis of the lateral sinus.

22. STAN. VON STEIN, Moscow. A case of epidemic cerebrospinal meningitis with bilateral otitis. Trephining of both lateral sinuses. Recovery.

Reports on the Austrian and Paris Otological Societies. Reviews.

Obituary (Prof. W. Moldenhauer, Leipzig).

Reviews.

Report on the Fourth Quarter of 1898.

Vol. XXXII., No. 4. Issued April, 1898.

23. FR. BEZOLD, Munich. Statistical report of the years 1893–1896.

24. J. E. SHEPPARD, Brooklyn. Three fatal cases of otitic brain-disease. (Translation from the Engl. ed.)

25. H. TREYSING, Rostock Clinic. Multiple tumors of skull and both drum-membranes.

26. THOS. BARR, Glasgow. Case of cerebellar abscess, etc. (Translated from the Engl. ed., year 1897, p. 241.)

Book Review (of *Jacobson's Text-Book*).

edies, and instruments, and to discuss in a progressive, yet conservative spirit all questions of present importance.

The ARCHIVES contain exclusively original papers on all branches of Ophthalmic and Aural Surgery, and original reports on the progress of Ophthalmology and Otology throughout the world. The original papers occupy about three-fourths of the space, and their scope embraces all subjects of scientific and practical interest in the departments of Ophthalmology and Otology.

Special attention is paid to the preparation of the Reports on the Progress of Ophthalmology and Otology. These Reports are intended to furnish *complete, systematic, and early reviews* of the current Ophthalmological and Otological literature of the world, and the work of preparing them is divided among a specially selected number of collaborators.

Under the heading of "Miscellaneous Notes" there will be published all kinds of professional news that concerns the Oculist and Aurist, *e.g.*, appointments, honors, resignations and vacancies, new ophthalmic and aural hospitals, prize questions and essays, announcements of Society meetings, etc.

Each volume contains besides a specified table of contents, an index of subjects and authors, both of the original papers and the reports, and a general index of the preceding seven years is added to every seventh volume.

Original papers of value from any source are solicited.

Communications for the English edition of the ARCHIVES OF OPHTHALMOLOGY should be addressed to DR. H. KNAPP, 26 West 40th Street, New York, those for the ARCHIVES OF OTOLOGY either to DR. H. KNAPP, or to DR. U. PRITCHARD, 26 Wimpole Street, W., London, England.

G. P. PUTNAM'S SONS, Publishers

NEW YORK — 27 & 29 WEST 23D STREET.

LONDON — 24 BEDFORD ST., STRAND.

PUBLISHER OF THE GERMAN EDITION

I. F. BERGMANN

20 Schwalbacher Strasse, Wiesbaden.

EDITORIAL NOTE.

In asking for continued support of the ARCHIVES from subscribers and contributors, the Editors offer no new program, but point to the record of the work that has been accomplished during the past twenty-eight years. At the first appearance of the ARCHIVES in 1869, they constituted the only periodical of their class in America, and had only a few predecessors in Europe. The international character of the ARCHIVES was a novel and distinctive feature.

The original program of the ARCHIVES to publish only original papers in semi-annual independent numbers has, in the course of years, been extended by the addition of reviews of the current ophthalmological and otological literature.

With the eighth volume, in 1879, the combined ARCHIVES, issued semi-annually, were divided into two separate journals, issued quarterly, and each of about the same size as the combined journal, and the reviews were converted into quarterly reports, systematic and comprehensive, though concise, on the progress of ophthalmology and otology.

Since that date, the ARCHIVES have developed into an extensive and conveniently arranged storehouse of knowledge for the instruction of the student and for reference by the practitioner and the investigator.

For more than ten years, the valuable material offered to the ARCHIVES has been so abundant that it has not been practicable to utilize for the English edition the full series of papers from the German, or the converse. Many articles had to be abridged, while of others abstracts only could be printed. Any one of our readers could, however, have secured, and can secure in future, from the American editor, or the German publisher, the loan of the original papers presenting the complete text.

It is the purpose of the editors to arrange, in the department of Reports, for the review of every publication which in their opinion contains material that can be called distinctive and important. It is, of course, impossible, within the limits of the ARCHIVES or of any similar journal, to give attention to every publication in their department of science. We may state further that it is not a part of our program to furnish a complete report on the *bibliography*, but only on the **progress** of ophthalmology and otology.

Though the systematic arrangement of the reviews is of importance for reference and comprehensive information, we shall publish, as early after the meetings as practicable, reports of the proceedings of societies, always bearing in mind that the ARCHIVES are not intended to be only a repertory of knowledge, but also a journal of news.

It is natural that the English edition of the ARCHIVES should give the advantage of time and space to Anglo-American contributors over the German, and *vice versa*. It is evident, however, that the association of the two editions lends strength to each, furnishing to the authors a wider circulation for their papers, and to the readers a larger and more diversified field of information.

NOTICE TO CONTRIBUTORS.

The editors and publishers of the ARCHIVES beg to offer some suggestions to authors who propose to favor them with their contributions.

1. As original communications the ARCHIVES can accept only such papers as have never been printed nor are intended to be printed in other journals. If a preliminary communication on the subject of a paper has been published, the author is requested to state this in the letter accompanying his manuscript. It is understood that contributors to these ARCHIVES and editors of other periodicals will make no abstracts of the original papers published in this journal without giving it due credit for the same.

2. Authors will receive gratuitously twenty-five reprints of their articles. If a greater number is desired,—notice of which should be given at the head of the manuscript,—only the additional cost of presswork and paper will be charged to the author.

3. In preparing manuscript for the compositor it is requested that the following rules be adhered to:

a. Write on one side of the paper only.

b. Write without breaks, *i. e.* do not begin a new sentence on a new line. When you want to begin a new line or paragraph at a given word, place before it in your MS. the sign ¶.

c. Draw a line along the margin of such paragraphs as should be printed in smaller type—for instance, all that is clinical history in reports of cases, etc.

d. Words to be printed in *italics*, should be underscored once, in SMALL CAPITALS twice, in LARGE CAPITALS three times.

4. Authors may receive proofs for revision if they will kindly return them without delay. We beg however to remind our contributors that changes in the copy are equivalent to resetting, causing so much additional expense. We therefore request them, to make, if possible, no alterations at all in their MSS., or, at least, to limit these to what is of essential importance.

CONTENTS OF VOLUME XXVII., NUMBER 3.

PAGE

1. Three Cases of Intracranial Abscess: the First Two Cerebellar and Fatal (Autopsies); the Third Subdural (Recovery); with Remarks. By **James F. McKernon**, M.D. 209

2. On the Retro-Auricular Opening after the Radical Operation for Chronic Middle-Ear Suppuration. By Prof. **Passow**, of Heidelberg. Translated by Dr. J. A. SPALDING, Portland, Me. (Five sketches in the text and nine figures on Plates I. and II. of Vol. XXXII., German Edition) 223

3. Three Cases of Brain Abscess Following Otitis Media. By **Arthur H. Coe**, M.D., Spokane, Wash. 237

4. A Case of Chronic Suppurative Otitis Media, Followed by Cerebral Abscess and Suppurative Meningitis—Operation—Death—Autopsy. By **Edward B. Dench**, M.D. 247

5. A Case of Perisinuous Epidural Abscess, with Facial Paralysis—Operation—Recovery. By **Fred. Whiting**, M.D. 250

6. Report of the Meeting of the New York Otological Society of May 24, 1898. By Dr. **H. A. Alderton**, Secretary 259

   J. F. McKernon: A Case of Bezold's Mastoiditis with Double Perforation 257

   Discussion: Drs. H. KNAPP, WILSON, WHITING, GRUENING, KIPP, and C. H. BURNETT (of Philadelphia).

   H. A. Alderton: Cholesteatoma of the Attic and Antrum . . 261

   C. J. Kipp: Accidental Opening of a Semicircular Canal . . 262

   C. H. Burnett: Etiology of Acute Mastoiditis 262

   Discussion: Drs. KIPP, GRUENING, and FRIDENBERG.

   C. H. Burnett: A Case of Tetanus 263

   E. B. Dench: Brain Abscess 264

   Discussion: Drs. GRUENING and H. KNAPP.

7. Report on the Progress in Otology for the Fourth Quarter of the Year 1897. By Dr. **A. Hartmann**. Translated by Dr. ARNOLD H. KNAPP 266

8. Report of the Transactions of the Section on Ophthalmology and Otology of the New York Academy of Medicine. By Dr. **W. B. Marple**, Secretary 297

E. B. Dench: A Case of Ossiculectomy, Wounding of Jugular Bulb, Septic Thrombosis of the Internal Jugular; Operation; Recovery 297

R. G. Lewis: Cholesteatoma Complicating a Bezold's Mastoiditis. 299

F. Whiting: Extradural Abscess with Extirpation of the Petrous Pyramid 300

Discussion: Drs. GRUENING, KNAPP, MCKERNON, and WHITING.

J. F. McKernon: Operation for Subdural Abscess 302

H. Knapp: Perichondritis of the Auricle 302

Discussion: Drs. COBURN, WHITING, TYSON, MCKERNON, F. COHN, GRUENING, DENCH, and H. KNAPP.

M. Toeplitz: Otorrhœa Cured by Radical Operation and Other Measures 304

E. Gruening: *a*. Streptococcus Mastoiditis Followed by Erysipelas. *b*. Mastoiditis with Cholesteatoma in a Child 304

Discussion: Drs. WHITING, DENCH, KNAPP, COHN, MCKERNON, PHILLIPS, TOEPLITZ.

T. J. Harris: Marked Improvement in Hearing as a Result of the Use of the Bougie 306

ARCHIVES OF OTOLOGY.

THREE CASES OF INTRACRANIAL ABSCESS: THE FIRST TWO CEREBELLAR AND FATAL (AUTOPSIES); THE THIRD SUBDURAL (RECOVERY); WITH REMARKS.[1]

By JAMES F. McKERNON, M.D.,

ATTENDING AURAL SURGEON, N. Y. EYE AND EAR INFIRMARY.

CASE I.—**Abscess of Cerebellum, Complicated by Thrombosis of the Lateral Sinus and Mastoiditis, Resulting from Suppurative Inflammation of the Middle Ear—Operation—Death.**

AS this case has already been reported in full in the Transactions of the New York Eye and Ear Infirmary, for the year 1897, I will here give but a brief résumé, dwelling particularly upon those points which seem to me to be of special interest in this class of cases.

M. L., female, age seventeen years, native of the United States, applied at my service for treatment March 10, 1897, giving the following history. She stated there had been a discharge from both ears, at frequent intervals, for the past eleven years, particularly upon taking cold, and for the past four years she had suffered from violent headaches on the right side, especially at the base of the skull.

Ten days before she presented herself at the clinic she had experienced a slight pain in the right ear, lasting for half a day, when the ear began to discharge and the pain ceased. For the next six days the right ear discharged freely, then the discharge lessened and the pain commenced again; this pain had lasted steadily for the past four days, with headache over the right side and pain behind the ear. Her temperature was 100.4°, pulse 108.

[1] Read before the American Laryngological, Rhinological, and Otological Society at its fourth annual meeting at Pittsburg, Pa., May 12, 1898.

Upon inspection of the ears, a slight watery discharge was seen coming from the canal of the right side. There was absence of the drum membrane, except a small portion in the posterior superior quadrant, which was bulging. A large amount of granulation tissue was present, and this was covered with gray-colored muco-pus. Pressure over the right mastoid caused considerable pain, especially over the upper third. The left ear showed nothing wrong in particular, except the remains of an old residual purulent inflammation, there being no tenderness on that side.

The patient was advised to enter the hospital, and have an ice coil applied, but this she refused to do. Incision was made in the remaining portion of the drum membrane and a few drops of pus were evacuated. Leeches were applied over the mastoid and she was given instructions to syringe the canal every three hours with a solution of bichloride, 1 : 3000, and report at the hospital the day following.

Two days later she returned, still suffering from pain in the right ear, over the right mastoid, and the right side of the head, the discharge now having almost entirely ceased. She now consented to remain in the hospital. An ice coil was applied over the right mastoid, and irrigation of the canal was kept up with bichloride every three hours, and a calomel purge, followed by a saline, was given with good results. The coil was kept on until noon of the following day, when it was removed, and the slightest pressure over the mastoid caused the patient to cry out with pain. The discharge from the canal had entirely ceased, but she complained of very severe pain over the right side of the head. Her temperature was now 101.2°, pulse 102.

The *operation of opening the mastoid* was now advised and accepted, as she said she could not possibly bear any more pain. She was etherized and the usual mastoid incision made; upon retracting the soft tissues, the mastoid presented an irregular outline, rather narrow, with color white and glistening. The antrum was opened and found to contain a few drops of pus and a small mass of granulation tissue. The situation of the antrum was very high up, and in entering it a small chip of bone was removed above, exposing the middle fossa. Granulation tissue was also found in the tympanic cavity and removed with the curette. The mastoid throughout its whole extent was removed and found to be dense and hard as ivory; the pneumatic spaces were completely obliterated and filled in by dense bone tissue; the sinus was not

exposed. The usual dressing was applied and the patient taken to the ward.

The next day the patient still complained of pain over the right side of the head and in the wound region; her temperature was 102°, pulse 114.

For the next four days she complained of headache on the right side and did not rest well at night, always saying that the pain was as bad as before the operation; during this time the temperature ranged from 99° to 102°, pulse never above 108 per minute.

On the 17th, five days after the operation, the dressing was removed and the wound inspected. The mastoid area did not look healthy, and there was a slight tendency to slough at the lower angle of the wound. The wound was cleansed and a dressing reapplied. That night the patient complained so much of pain in the wound and headache that it was necessary to give her an opiate, to get even an hour's rest.

The next day pain continued with a gradual rise in temperature to 104°, and Dr. Dench was asked to see her in consultation. The dressing was removed from the mastoid, which presented a grayish look over its entirety, and upon palpating with a probe softened bone tissue was found over the central portion of the lateral sinus; at one point, just below the centre, the probe passed through this softened bone and entered the sinus, and upon being withdrawn was not followed by any flow of blood.

A second operation was decided upon, the patient etherized, and, with the assistance of Dr. Dench, the upper portion of the sinus was exposed for about one inch. The bone over it was very soft and carious, and the sinus was found collapsed; the dura over this upper portion was incised and a large amount of dark-colored pus and granulation tissue were removed, the curette was used freely, and circulation restored above. This was controlled by packing iodoform gauze against the sinus. The lower portion of the sinus was now uncovered as far as the jugular bulb. The bone covering this part was exceedingly thick, its cancellous structure being carious. The dura over this portion of the sinus was opened as far down as the bulb, and pus and granulation tissue similar to that found in the upper part were removed; the sinus was curetted, and a free hemorrhage took place from below, which was controlled by packing iodoform gauze firmly into the lumen of the vessel. It was noticed, while operating, that the

posterior dural wall of the lower half of the sinus was somewhat thickened.

The patient rallied poorly from the ether and required active stimulation for four hours afterward. The next day she complained of severe headache, saying she could not possibly stand the pain; she vomited a yellowish fluid at four different times during the day. Her temperature was 103.5°, pulse 122. Upon the nurse's report that no urine had been passed that afternoon, the catheter was used, twelve ounces were drawn, and upon being examined was found to contain nearly 2 per cent. of albumen. At six o'clock that evening she become very restless, delirious, tried to get out of bed, and was unable to answer questions. Her temperature was now 105°, pulse 154, respiration 38. The dressing was removed, and free hemorrhage took place from the sinus; this was controlled by packing with gauze as before.

The posterior dural wall of the lower half of the sinus, which was noticed thickened at the second operation, showed a slight fulness. The dura over this point was opened and a grooved director was introduced downward, backward into the cerebellum for about two inches, and, upon withdrawing it, was followed by a discharge of about an ounce of foul-smelling pus, together with disorganized brain tissue.

The opening into the cerebellum was now enlarged sufficiently to admit the finger, which, passed downward and inward, was followed by a still further discharge of pus of a very offensive odor. The cavity was sponged with gauze as gently as possible, packed loosely with iodoform gauze, and a dressing quickly applied; as the patient's condition was very weak, active stimulation with strychnia, digitalis, and whiskey was needed to rally her.

After three hours she roused somewhat, and could speak, and took liquid beef peptonoids for nourishment at frequent intervals during the next six hours.

At three P.M., twelve ounces of urine were drawn, and upon examination showed a larger quantity of albumen present than the specimen examined eight hours previous. During the early part of the following day she was conscious and took nourishment, her temperature at no time since the evacuation of the abscess falling below 104°, with pulse 140.

Since the time that albumen was discovered in the urine, counter-irritation over the kidneys was used, followed by digitalis poultices, which were kept up continuously, and a diuretic was given internally.

At five P.M. the wound was dressed again, and upon removing the gauze from the abscess cavity, a brownish, purulent fluid escaped, together with more disorganized brain tissue. The cavity was cleansed with small strips of sterile gauze, soaked in a normal salt solution, and loosely packed as before with iodoform gauze. During this dressing the patient complained of very little pain. For the next four hours she was conscious and said she felt better. Her pulse and respiration were better and she continued taking nourishment. The next morning she became very restless, and finally passed into complete coma. Saline solutions were retained by the rectum for a few hours. The poultices were continued over the kidneys, but no urine could be obtained by catheter, and she gradually became weaker. Active hypodermic stimulation was used, and at the end of three hours, four ounces of urine were drawn and found to contain a very large amount of albumen and many casts. Coma continued during the night and the patient died next morning at eleven o'clock. Just before death the temperature reached 107.4°.

Previous to the evacuation of the abscess, the eyes were examined by Dr. C. S. Bull, the result being negative.

Upon *autopsy*, no ante-mortem clot was found in any sinus of the dura, or any other intracranial involvement, except the two here mentioned.

I wish to call attention to the very dense and firm condition of the mastoid, the absence of pneumatic spaces, and the thickened condition in its entirety of the mastoid tissue. Bacon [1] lays particular stress upon this point in his report of brain-abscess cases, saying that when the mastoid is found firm and dense upon operation, and the symptoms still continue, he believes we are justified in further exploration of the cranial cavity, and that by so doing we shall many times discover the seat of the trouble, where otherwise it would be passed over.

Also attention is to be drawn to the fact of the bone being found carious over the sinus five days after the first operation, as this bone was dense, hard, and firm when first exposed, and infection must have come from within, working outward after the sinus became involved.

When a septic thrombus is present we should expect a

[1] *New York Eye and Ear Infirmary Reports*, 1897.

chill and a sudden rise of temperature, with a spontaneous fall where septic material enters the sinus, but here the rise was gradual, and remained so until after the second operation. In this case, I believe that, primarily, the abscess of the cerebellum was the result of infection from the purulent inflammation existing in the middle ear, and was transmitted to the cerebellum through the medium of the pneumatic mastoid spaces and their venous communications previous to the mastoid becoming sclerosed, and that this focus of pus in the cerebellum was slow in its advancement, taking, in all probability, months or years (as would be safe to infer from the history of the case) to reach the state in which it was found.

CASE 2.—**Abscess of Cerebellum, Complicating Chronic Purulent Otitis Media with Thrombosis of Lateral Sinus—Death from Chronic Nephritis.**

W. J., aged twenty-five years, a native of the United States, by trade an electrician, was admitted to my service at the New York Eye and Ear Infirmary, June 12, 1897, giving the following history :

He had been in poor health, though able to work, for the past two years. For several years past (no definite time could be remembered) he had been troubled with a discharge from both ears, with occasional attacks of pain. When the pain was most severe the discharge would be scanty or cease altogether, only to appear again when the ear broke and began running.

Two weeks before his admission, he said, there was a severe pain at night, in the right ear, which lessened the next day when the ear began to discharge a thin white-colored fluid. For the next week he had pain in this ear occasionally at night. On the twelfth day after the pain began the discharge stopped, and was followed by a severe pain in the ear, and two days later the pain was felt behind the ear and had continued steady up to the time he was seen. He said for the past eight days he had had no sleep, not so much on account of the earache, because he was accustomed to that, but on account of a severe pain low down in the back of his head on the right side. This pain, he said, had continued uninterrupted for eight days, and seemed to be getting worse each day.

Upon examination he was found markedly anæmic and emaci-

ated, having lost, he said, some twenty pounds in weight during the past four months. The skin appeared pallid, and he was very weak, being scarcely able to walk without assistance.

Upon inspection, a scanty discharge of gray pus, with a pronounced odor, was seen coming from the right external auditory canal. The superior and anterior walls of the canal were protruding into the lumen of the tube, shutting off a view of the parts beyond. Over the right mastoid was a boggy, œdematous swelling, extending well down toward the tip. Upon the left side a profuse discharge of greenish pus was coming from the external auditory meatus. This was cleansed away. An inspection of the deeper structures showed absence of the drum membrane, and a probe, passed directly along the posterior and inner walls of the tympanum, encountered dead bone in several places. There was no mastoid tenderness on this side. The temperature was taken and found to be only 98.2° F.

The patient was informed of his serious condition and advised to have an operation at once. He readily consented, saying the pain was unbearable, and nothing could be worse than that. He was sent to the ward to be prepared for the operation, an order being given to have a specimen of the urine examined before he was taken to the operating-room. This was done by the house surgeon, who reported, in a short time, that the specific gravity of the urine was 1010 and contained one third of albumen by bulk. The patient was told of this kidney condition and the probable gravity of it, but he still insisted that something must be done to relieve the pain of the head.

He was taken to the operating-room, chloroform was administered, and the usual mastoid incision made, extending from the tip below, half an inch posterior to the attachment of the auricle, to a point corresponding to the upper border of the zygoma above. This incision extended through the soft part and periosteum down to the bone. The periosteum was easily separated from the bone, and this with the soft part was retracted, exposing a dark, mottled mastoid cortex. The bone was soft and necrosed throughout its entire external table. The antrum was easily entered and freed of a thick creamy pus. The mastoid cells were all broken down, and pus passed freely from one to the other. This formed a large cavity, filled with pus, decaying bone substance, and granulation tissue. All of this was thoroughly removed by the curette.

The necrotic bone extended well backward over the sigmoid

sinus and down to the tip. All of this was thoroughly removed by the rongeur and curette, and in doing so one and a quarter inches of the lower portion of the sigmoid sinus was uncovered from the bend downward. A portion of the dural wall covering this part of the sinus was covered with granulation tissue. This was gently removed with the curette and thumb forceps. The uncovered portion of the sinus did not appear over-prominent, and no pulsation of the dural wall covering it was discovered when the finger was laid upon it. The sinus was aspirated and fluid blood drawn into the syringe, showing that the lumen of the vessel was free from any clot. A small tampon of iodoform gauze was placed over the point of aspiration, the surface cleansed, and the wound packed and dressed in the usual manner. The patient was returned to the ward, the time of the operation consuming forty-seven minutes. During the operation he was stimulated twice hypodermatically, $\frac{1}{20}$ of a grain of the sulphate of strychnine being given each time. He rallied well from the operation, his pulse stronger now than before, but as soon as he became conscious, which was in half an hour after leaving the operating-room, he began complaining of pain at the base of the skull on the right side of the head.

At eleven o'clock that night he slept for twenty minutes, and upon awakening was very restless and complained of nausea, but did not vomit. His temperature was now 102° F. Eight ounces of urine were drawn, and upon examination found to contain about the same quantity of albumen as the specimen previously examined. The microscopical examination showed it to contain abundance of hyaline and granular casts, with plenty of pus cells and epithelium. Hot packs and poultices were applied over the kidneys in the lumbar region, and rectal enemas of a warm, normal salt solution were used every three or four hours, and internally was given the infusion of digitalis, half an ounce every three hours.

The kidneys responded to this treatment, and he passed urine twice during the night and three times the following day, the smallest quantity passed at one time being three ounces and the largest nine ounces. These specimens all contained a large percentage of albumen.

The noon temperature, the day following the operation, registered 102.8° F., pulse 124. During the afternoon he was exceedingly restless, nauseated, and kept complaining of pain in the

wound region and low down on the right side of the occiput. At five o'clock his temperature rose to 103.4° F., pulse 138 and weak, respirations down to 16 per minute and shallow. He seemed drowsy and no longer complained of pain. The eyes were examined, with negative result. The dressing over the wound was now removed, and that portion of the dural wall covering the exposed sinus was found bulging into the mastoid wound. The patient was stimulated with strychnine and whiskey, and taken to the operating-room and chloroform again administered. The sinus was rapidly uncovered to the jugular bulb below, and above as far back as the torcular, and opened from end to end of this area, evacuating a quantity of pus, clotted blood, and granulation tissue. Free hemorrhage was established below, and was easily controlled by packing iodoform gauze into the bulb.

After persistent use of the curette and probe, the blood stream was established above, and let flow for a few seconds to wash away any septic material that might remain in the vessel. The hemorrhage here was controlled as below, by packing with iodoform gauze against, but not into, the lumen of the vessel.

After controlling the hemorrhage above and below from the sinus, it was noticed that the dura of the posterior sinal wall, corresponding to the lower half of the sinus, was bulging outward, similar to that of the sinus before it was opened. A slit in the dura, with a knife, at its most prominent part, was made, and a grooved director passed downward, backward, and inward into the right lobe of the cerebellum for about two inches, and upon being withdrawn was followed by a little oozing of foul-smelling pus. This opening was now enlarged with the finger, and was at once followed by a flow of about two ounces of pus, grayish in color, and with an exceedingly foul odor. This pus was quickly mopped out with strips of gauze soaked in a normal saline solution, and the cerebellar cavity loosely packed with iodoform gauze; a dressing was applied over the whole surface, and the patient quickly taken to the ward, placed in bed, and the foot of the bed elevated; active hypodermatic stimulation of whiskey and strychnine, and a warm saline enema in the rectum, were given, and the body surrounded by hot-water bags and hot bottles.

Under this treatment he regained consciousness, said he felt better, and had no pain. His temperature was now, one hour after the second operation, 101.4° F., pulse 140, character weak. The time of the second operation was thirty-eight minutes.

At ten o'clock that evening he said he felt fairly comfortable, except a pain in his back and legs. His temperature was 102.3° F., pulse 148, still weak. The hot applications over the kidneys were renewed and kept up, and at 2 A.M. three ounces of urine were drawn, containing a still larger quantity of albumen by bulk than any of the previous specimens. During the morning hours of this day he took a small quantity of liquid nourishment, asked for water, was rational, and did not complain of any pain.

In the afternoon he became restless, somewhat irritable, and tried to get out of bed and go home. Later he became stupid, passed into a state of coma, and died at six o'clock that evening. Just a moment previous to the death, the nurse records that he had a slight convulsion.

I will not trespass upon your time by giving the full *autopsy* notes, except to say that no further evidence of any intracranial involvement was found. The kidneys were both in an advanced state of parenchymatous nephritis.

The features of particular interest to the writer in this case are:

1. The fact that the severe occipital pain was in no way relieved by the first operation, showing, as later events proved, that the cause of this pain had not been removed, for after the second operation and the evacuation of the pus from the sinus and cerebellar cavity, when he regained consciousness, which he did in half an hour, he said all pain had disappeared, and while consciousness lasted he did not again complain of this pain, although asked repeatedly if it were present. This shows, I believe, that in the cases which are not relieved of pain by the opening of the mastoid we should go still farther, without too much delay, and explore the cranial cavity thoroughly in order to determine the cause, if possible, of the pain. In doing this, it can be accomplished with less injury to the cerebral substance, if, instead of using the aspirator, we use a grooved director; for, if pus be present and thick, it will not pass through the ordinary aspirating needle used for this work. The director can be passed into the brain in several directions if necessary, and the slight hemorrhage resulting will do no harm, and if a pus sac be found, even though thick, the pus will follow the director to the surface.

2. We expect in septic sinus thrombosis a rigor and a sudden rise of temperature, with a remission. This did not occur here, as the temperature taken every two hours only showed an increase of scarcely one degree F., and this gradual in its rise. Also attention is to be drawn to the absence of any pulsation in the sinus when it was exposed at the first operation, as many writers have said when pulsation is not present the vessel contains a clot. I think this is of little or no value in determining the condition of the blood current, as the pulsation when present, I believe, is due to the impulse transmitted to the sinus from the brain substance lying adjacent to it.

We are told by Starr,[1] that the symptoms of brain abscess can be quite distinctly divided into three stages. This may be true, but in brain abscess caused by a purulent otitis we may have complications, such as sinus thrombosis, meningeal inflammation, epidural abscess, etc., causing an increase in symptoms that are misleading; as, for instance, we look for a low temperature in abscess, but where pyæmic sinus thrombosis exists we usually get a high temperature with a sudden remission, these being usually preceded by one or more rigors, so that the symptom of temperature cannot be relied upon. Again, it is much easier to diagnose an abscess of the brain, the result of traumatism, than middle-ear trouble. The indications justifying or calling for an exploration of the cranial cavity where an abscess is suspected in relation to ear diseases are, I believe, as follows:

1. That a chronic otorrhœa is, or has been, present.
2. Persistent headache, general and localized.
3. Restlessness and irritability of temper.
4. Tenderness of the affected side to percussion.
5. Nausea, vomiting, and vertigo.
6. An almost persistently low temperature.
7. A slow pulse, later stupor. Optic neuritis may or may not be present; when present, it may aid us very materially in arriving at a diagnosis, as may also aphasia and motor disturbances. In my own cases these were absent.

Of these symptoms, I believe the one to which the most

[1] *N. Y. Eye and Ear Infirmary Reports*, 1897.

importance should be attached is severe and persistent head pain.

In 1895, Koerner reported ninety-two cases of brain abscess operated upon, with fifty-one recoveries. Since that time there have been a number of successful cases, both in this country and abroad, operated upon. He also says it occurs oftener on the right side than the left. The cases here reported would seem to bear this out, as all were on the right side.

The use of the chisel, gouge, and rongeur seems to me to be a more rapid method of entering the skull than the use of the trephine.

CASE 3.—**Acute Mastoiditis, with Subdural Abscess Following an Attack of Acute Otitis Media—Operation—Recovery.**

P. S., an Italian, aged thirty years, was admitted to my service at the New York Eye and Ear Infirmary, March 4, 1898, with history as follows:

Had always been in good health except an attack of the grip six years before, when he was sick for one week, but stated distinctly he had no aural trouble at that time, or at any time previously.

Five weeks before, he contracted a severe cold and suffered from sore throat for two days. On the third day he experienced pain in the right ear, which lasted continuously for five days. During this period he was unable to sleep night or day, and the night of the fifth day, after a severe paroxysm of pain, the ear began to discharge and the pain was relieved. He said the discharge was thick, did not have any odor, and was very profuse.

Four days later the pain commenced again in the right ear, and two days after this, was followed by pain and tenderness over the mastoid of the right side. Pain was also very pronounced over the right temple and radiated backward over the side of the head to the occiput.

During this entire period he was under the care of a physician who pursued the usual treatment in these cases, namely, syringing the ear, and later, leeching the mastoid, etc.

Upon physical examination there was a marked anæmic condition present, with a characteristic septic pallor of the skin. The tongue was heavily furred and pulse about 100 per minute. A physician who accompanied him to the clinic said his temperature that morning was nearly 102° F.

Inspection of the ears showed a profuse purulent discharge yellow in color, coming from the external auditory meatus of the

right side. Upon placing a speculum in the meatus, the superior and posterior walls were seen collapsed and bulging into the canal. At the lower and anterior part of the drum membrane could be seen a mass looking like granulation tissue. The mastoid over its whole area was exquisitely tender upon pressure. This tenderness to pressure extended above the zygoma and also in front of the superior attachment of the auricle.

An operation was advised and accepted. The patient was prepared, ether administered, and the usual mastoid incision made, extending through the soft parts and periosteum to the bone. The periosteum and soft parts were retracted, showing the cortex dark in color and mottled in its appearance. The first stroke of the chisel over the antrum caused pus to well up in the opening. This pus was of a dark gray color, with but little odor. The antrum was curetted, and the whole outer table, which was necrotic, was removed. The whole of the posterior canal wall was removed as well as the tip. In fact, the whole apophysis was easily separated from the inner table, leaving nothing below except the muscular tissue beneath the tip. The necrosed bone extended back beyond the sinus for nearly an inch and the sinus was exposed for one and a half inches downward toward the bulb from its bend. Granulation tissue was removed from this area over the sinus. The whole of the cavity was cleansed and communication established with the middle ear through the aditus.

In using the probe to palpate for softened bone, it entered readily that portion of the bony wall separating the antrum from the middle cerebral fossa. This softened bone was removed with the curette over an area of nearly an inch, exposing the dura, which looked very much darker than normal.

The dura was opened at this point, a grooved director was passed upward and forward between the dura and brain in the middle fossa. Upon being withdrawn it was followed by a discharge of pus from beneath the dura. The opening was enlarged sufficiently to admit of the passage of the finger, and the cavity emptied of about four drachms of gray-colored pus, with but little odor.

The probe was passed in various directions, but encountered adhesions all around the abscess cavity, showing that nature had walled off the pus and prevented its spread.

There was still some softened bone found near the junction of the superior and posterior canal walls, and in removing this, upward and forward, an opening was found through the vault of the

tympanum, showing where perforation had taken place. A bent probe was easily passed from here directly into the subdural abscess cavity of the middle fossa.

The cavity was syringed with a solution of bichloride 1:10,000 and packed loosely with iodoform gauze. A separate piece of gauze was passed into the tympanum at the point of perforation and the other end carried against the dural opening of the middle fossa.

As the dura over the sinus was dark in color and covered with granulation tissue, it was thought best to aspirate it, even though distinct pulsation was present. The needle drew fluid blood from the sinus twice, showing the current was normal within. There was quite an active hemorrhage where the second puncture of the needle was made, but it was controlled by packing gauze against it.

The usual dressing was applied and the patient taken to the ward. The operation lasted fifty-one minutes and he required stimulation three times. $\frac{1}{20}$th of a grain of strychnia was given hypodermatically twice and later a drachm of whiskey in the same manner. The patient rallied nicely from the operation, and at eight P.M. his temperature was 99°, pulse 104. Six hours later his temperature was 102°, but he said he felt comfortable and free from pain.

At eleven o'clock in the morning of the day following the operation he had a sudden chill and complained of severe headache, sore throat, and pain in the back of the neck and throughout the body, and his temperature rose to 103.2° F. The throat was examined, and he was found to be suffering from an acute follicular amygdalitis. This, under treatment, subsided in a few hours and the temperature gradually became lower each day until, on the eighth day after the operation, it touched normal.

The first dressing was removed seven days after the operation and the parts found healthy, save a stitch-hole abscess in the upper angle of the wound.

From this time on he was allowed to sit up each day. The wound was dressed every other day, and he was discharged from the ward service sixteen days from the date of the operation, returning to the clinic three times a week for treatment.

The one principal point for emphasis in this case is,—that here we have a very extensive mastoid involvement, together with a subdural accumulation of pus, the result of acute otitis media of only five weeks' standing.

ON THE RETRO-AURICULAR OPENING AFTER THE RADICAL OPERATION FOR CHRONIC MIDDLE-EAR SUPPURATION.

By Prof. PASSOW, of Heidelberg.

(*With five sketches in the text and nine figures on Plates I. and II. of Vol. XXXII., German Edition.*)

Translated by Dr. J. A. Spalding, Portland, Me.

We are all united in the opinion that the radical operation for the cure of chronic middle-ear suppuration is very valuable, but we differ concerning its indications and the method of performing it. The purpose of this essay is to discuss the retro-auricular opening, and the plastic operations by which it is closed.

Before reaching the latter I will speak briefly about the operation itself, so far as it is connected with the immediate topic of my paper.

In regard to the indications for the radical operation I agree with Trautmann and Stacke,[1] making the attempt to cure a case by preliminary extraction of the hammer and anvil only when the chances are favorable, or when the operation can be easily done without narcosis. We must not forget that many who depend for their living on manual labor lose valuable time if we operate unsuccessfully on the ossicles, and are later compelled to resort to the radical operation.

The method of operating seems to me unimportant. Our aim should be to make a large cavity embracing the middle-

[1] Stacke, *Die Operative Freilegung der Mittelohrräume*, 1897, p. 29.

ear spaces, removing diseased and suspicious bone, and cleansing all niches and pockets. My first aim is to reach the antrum, and from there on, one method is as difficult as the other. I use a straight chisel, strong forceps, a sharp spoon, and a gouge. The hole should be large, and I take sound bone rather than run the risk of leaving diseased bone behind. Facial paralysis I have seen but once from the operation, and its permanency was not proved, as the patient died from tuberculosis.

Siebenmann's suggestion to spare the matrix in cholesteatoma I am unable to accept. It should be freely removed.

A large number of authorities[1] close the retro-auricular opening by primary suture independent of the nature of the disease, others[2] leave it open; some only in cases of cholesteatoma, and others only with extensive disturbances in the mastoid. Of those who leave the opening patent, some close it later, either during recovery, or long after the cavity has become covered with skin.

Starting from the functional results, the ideal aim of the operation should be to cure the suppuration by covering the entire region with skin, and without any disfiguring scar. The method which most surely and most rapidly reaches this goal is to be preferred.

When we use a primary suture all traces of the operation disappear. The same happens after secondary closure. A persistent opening behind the ear is a disfigurement indeed. Nevertheless we must abandon primary closure if by following it we sacrifice safety. We must make the opening permanent if thus alone we can guard against relapses and danger. If we agree with Schwartze's views of cholesteatoma we must, in cases of this sort, maintain a permanent fistula even though covered with skin.

The cicatrization of the hole in the bone and the time required for recovery depend on various circumstances. The more carefully the operation is done, and the more gentle

[1] Panse, *Klin. Vort. a. d. Gebiet. d. Ohrenhlkde*, Band ii., Heft 4; Hartmann, *Die Krankheiten d. Ohres*, 1897; Noltenius, *Deutsch. Ot. Ges.*, 1897, p. 146; Zaufal, *ib.*, p. 159; Grünwald, *Deutsch. med. Wochensch.*, 1895, No. 47.

[2] Trautmann, Jansen, Siebenmann.

the after-treatment is, the better the results. There are cases which last for months, and a few in which a cure is never attained. No operator escapes occasional ill-fortune.

We cannot predict the course which any case will take, no matter whether cholesteatoma or other disease. The patient's constitution makes a difference, whilst the anatomical relations, the nature of the disease, and its extent are to be considered. A certain case seems most favorable, and we give a good prognosis, but luxuriant granulations, proliferation of bone, and secretion from the tube shatter our hopes. Again, recovery follows where least expected. We lay aside our instruments dissatisfied, we have left an unwelcome niche; but for all that, the opening heals smoothly. I have often been amazed at the results in phthisical patients on whom I had operated most reluctantly. I now recall a young man who died from intestinal tuberculosis, but despite his rapid decline the opening in the bone healed without disturbance.

The after-treatment is important. Every day is a critical one, says Stacke. We must keep the wound under absolute control up to the day of recovery. The earlier we discover adhesions, granulations, or caries, the better we can get rid of them.

Granting that the retro-auricular opening is only a makeshift, its opponents must acknowledge that it simplifies the after-treatment. Every spot is open to tamponage, niches large or small are easy to see, secondary operations are easy to do; so free a view into the cavity cannot be obtained by any operations with the primary suture, and in Koerner's operation we need a speculum whenever the dressings are changed. Such a saving of time in a large clinique is important where we wish to give time enough for a careful dressing, yet be sure that all is going on well. If in case of a primary suture the introitus is not enlarged and the meatus only split backward, and later tamponed upward and downward, we finally get a pocket which hides the condition more or less.

Panse's operation permits us to see the promontory and facial ridge and in most cases the posterior portion of the

bone cavity, but how the latter is possible in extensive destruction of the mastoid I cannot understand. He remarks that the region about the tube is often hidden, but that this is not important, an assertion with which I cannot agree.[1] Koerner's operation, which he does not recommend with a narrow meatus and a large cholesteatoma, gives us a far better view of the operative field.

I have never seen patients operated by Koerner himself, but in others operated by his method a permanent deformity resulted. Some patients also complained that the dressing either fell completely out of the ear, or slipped into the bony cavity. Inasmuch as a portion of the surface of the cavity is covered with a flap from the meatus and the concha, the disadvantage, clinging to all methods with primary sutures, of requiring skin-grafts or pedunculated flaps, is by this method partly obviated. It has also found many supporters, but it keeps up the danger attendant on all radical operations, that the recovery may not be smooth. Even luxuriant granulations are not easily dealt with in a closed retro-auricular opening, and if at a later date the hidden bone becomes affected the cicatrix must unavoidably be reopened.

It is not my experience that patients complain more by changing the dressing from the meatus than from a retro-auricular opening. It is only so in sensitive patients or unruly children. Genuine pain indicates a disturbance in the course of the recovery. If pain is complained of in the wound, or darting in various directions, orthoform may be beneficially dusted on the bandage.

A large bandage is needed in the early days after the operation, and if the cavity remains open such a one has to be used a long time. If my transplantation method is employed, a very simple covering can be substituted at the end of a week, and after that only plaster.

One obstacle to early closure of the opening is the fact that otology is a dead letter to many physicians. In making the radical operation, I insist that the patients shall remain under my care, or, if they live at a great distance,

[1] This operation is described in *Archiv f. Ohrenhlkde.*, 3 and 34.

under that of some other specialist. Despite this understanding, patients, especially the very poor, go home too early and never return. They have an idea that their physician can bandage the ear as well as anybody else. But most physicians have no idea (though it is not their fault, but that of their education) of the purpose of the radical operation, and cannot understand the difficulties in the way of changing the dressings. Many think it is a specialist's conceit, if the latter hesitates to recommend a patient to them. If the cavity is open, they can at least get some idea of the case, and if the patient reports occasionally, recovery is fairly sure. It is, however, in cases of treatment through the meatus that physicians fail, for ultimately the patients return with profuse granulations, and a second operation, hardly less dangerous than the original, has to be performed.

If we wish to let the wound close we must not resort to pedunculated flaps, but we may try Thiersch's transplantation, to which I will soon return. If we tampon from the meatus only, the wound will close rapidly. Sometimes it tends to do so, though not desirable, and therein lies the failure of the whole operation. *We do not have it completely in our power to choose the exact time at which we can abandon the retro-auricular opening and its advantages.*

The middle ear is not always covered with epidermis when closure occurs, so that we are deceived about the course of the case. Often where the epidermis has begun to form rapidly, it as suddenly stops, and unforeseen difficulties ensue. If at that time the opening is cicatrized, we have the same troubles as after the primary suture, and they are especially great if the entrance of the meatus has not been enlarged.

Having so far chiefly discussed *the certainty of the recovery*, we turn to *the time taken for obtaining it.* It is hard to say by which method cicatrization occurs most quickly. In the first place, the date of actual recovery is not sure, because many patients at the time when cicatrization is nearly completed disappear. Furthermore, the time depends on the plastic method employed. In tuberculous processes, in inaccessible caries, and in disease of the inner ear, it is no matter,

so far as the rapidity of the epidermic process is concerned, whether we close the cavity by the primary suture or not. There are also cases in which the cicatrization is complete in a few weeks, only a minute spot still leaks; we hope it will close in a few days, but, instead, weeks and months are needed.

Assuming that the operated region will cover with skin the more rapidly, the more healthy the skin we insert, several plastic methods have been suggested to shorten the cure. This happens actually so in those cases in which, all that is morbid being removed, the tendency to recovery is rapid, but in those obstinate cases which we should be most glad to relieve, recovery is tardy despite the plastic operation. The flaps heal well, but we wait in vain for proliferation from the edges. Some claim that flaps are dangerous because pus may form beneath them, or that they may cover diseased bone, but I have never met with such instances.

Every operator gradually gets more sure in the performance of the radical operation, more accurate in placing the bandages, and from time to time he alters his plastic method. If he then gets better results, it is hard to say whether this is due to his greater skill or to the method employed. With private patients, too, the results are more favorable than with those in hospital who are badly nourished; in the case of children this is more noticeable still.

We must study statistics of the after-treatment, in order to determine the longer or shorter process of healing in various methods of operating. We must assume, in their absence, that the formation of epidermis progresses more rapidly in cases going on normally with the primary suture, than with the retro-auricular opening without the plastic operation, and slower still than the latter with pedicled flaps from behind the ear or with transplantation of skin. So far as my observations go, this is the actual state of affairs. The same is the case when the cavity is very large, either because the destruction was extensive, or because cells far to the rear had to be opened. Then again when recovery is retarded an energetic secondary operation or insertion of bits of skin will hasten recovery. In such conditions the retro-auricular orifice is an advantage.

I regret to deny Panse's assertion, that the good results from transplantation of epithelium are due to the previous removal of granulations. With a healthy substratum for insertion of Thiersch skin-flaps epidermization takes place with a rapidity impossible without transplantation. I have seen openings which showed no signs of epidermis, covered in a fortnight after transplantation.

In order to discover the average time needed for complete recovery, I have studied all accessible literary sources,[1] and I find that taking all in all we can say that the average duration of time needed for recovery from the radical operation, as performed by some twenty separate operators, is from three to four months.

I have before remarked that the opening behind the auricle is a deformity, the larger the opening the greater the deformity. Gaping orifices of this sort are not only disfiguring, but dangerous, because they may give occasion for relapses. Therefore, so far as safety permits, we should make an opening as small and as little disfiguring as we can. The size will depend more on the anatomical relations of the parts, and the condition of the middle ear, than on the operator. Bezold leaves as much bony tissue as he can on the posterior wall, and only chisels away enough so that the posterior wall shall leave no recesses. This is only in very favorable cases so far as I can judge. Moreover, we should not use pedicled flaps, as they contract the canal and prevent the formation of epidermis at the margins.

Primary closure has its advantages, but the formation of epidermis is more certain and rapid if we leave the opening chiefly to its own recovery. For that reason I shall not, or rather I should say I shall not yet, abandon the retro-auricular opening in the radical operation.

The condition of affairs is different when recovery is complete. With simple caries, or chronic affection of the mucosa, there is no reason to keep the opening persistent. But we ought not to close it until the epidermis is everywhere firm,

[1] The original paper here devotes three entire pages to various papers, which I compress into a single paragraph. Those desirous of exact information can consult the German original in the Editor's hands.—THE TRANSLATOR.

and not inclined to proliferate or to become eczematous. This essay has nothing to do with cholesteatoma, and from our present knowledge we cannot answer precisely when the opening is to be closed in that disease. Hence I limit myself to reasons for opening or closing the opening in cases not cholesteatomatous.

The hope that relapses would be a thing of the past after introduction of the radical operation have not been fulfilled, but they are rarer, because those causes which brought them about have ceased with increased space and freer access of air. The entrance of air by the widened meatus is indeed enough. If it is objected that sufficient time has not yet elapsed since the introduction of the operation to decide regarding relapses, we can reply that cases have now been free from relapse for some years, and amongst them cases of cholesteatoma in which formerly (after the antrum operation) relapses were confidently expected. If a cholesteatoma relapses and is not soon discovered, it can be just as dangerous with an open orifice as with one that is closed, for which reason long observation of patients is essential. Occasional relapses can be discovered without a retro-auricular fistula, provided that there are no pockets. If the original cholesteatoma were small, and occupied but little space in the attic, there is but little fear of relapses into the mastoid.

I close the fistula from a cholesteatoma if the skin has remained smooth and free from irritation for six months or possibly a year, and especially if I have sensible patients on whom I can rely to return occasionally for proper examination. I let the opening remain persistent if during the course of the observation eczema forms on the cicatrix, or if superficial layers of epidermis exfoliate, or if the case be one of a tumor extending into the antrum, or filling the entire mastoid. At this point I would remark, that I have not often seen abundant formation of crusts after recovery from cholesteatoma has once set in. My reason for getting rid of the matrix in these cases is because Morf says that cases operated by Siebenmann's method show in the early stages symptoms of proliferation.

The radical operation is now done at my clinique in the

following way (compare at this point Plates I. and II.). The primary incision begins below, a little above the tip of the mastoid, about two *cm* behind the insertion of the auricle and extends upward to about one *cm* above the linea temporalis, at which point it comes nearly in contact with the auricle. We thus get a slightly convex incision, as shown in Fig. 1, Plate I. The skin is dissected up to the auricle. Only now is the periosteum incised, parallel with and close to the insertion of the auricle. Then it is stripped off the bone backward and to the tip of the mastoid, and cut away as far as it lies bare. The upper and posterior walls of the meatus are loosened and pulled forward with a long hook. If possible the anterior wall remains *in situ*. In this way the entire field is so widely exposed that we can enter the middle ear by Schwartze's, Stacke's, or Zaufal's methods.

After completing the operation on the bone the external meatus is split open as far as the cartilage of the auricle (*b c*, Fig. 3, Plates I., II.) and by a second incision perpendicular to the first (as far as *d*), thus forming from the meatus a large upper flap, the soft parts of which are removed with scissors. After the flap is tilted upward, its anterior margin (*d c*, Fig. 4, Plates I., II.) is united with the anterior edge of the bony wound by two sutures (from *h* to *i*). The auricle is then hemmed with two sutures, of which Siebenmann complains that it takes time, but by omitting a needle-holder and using straight needles it takes about two minutes. The lower flap of the meatus is sutured to the lower portion of the anterior margin of the bony wound, at the concha (Fig. 4), with a needle-holder and small curved needles. The flap being small and not projecting as in the sketch, which is exaggerated for the purpose of demonstration, considerable skin is dragged into the cavity. Next we form a quadrilateral flap by elongating the original incision in the skin (*e*, Fig. 4) forward and downward to *f*, about one and a half *cm*, and then going up to *g*. The breadth varies according to the need of covering a larger or smaller portion of the bony cavity, the length upon how far we carry the incision upward (as suggested, even to $g\,g^1$). In order to avoid

FIG. 1.

a visible scar in the neck, it is important that the incision *c f* should not go beyond the lower margin of the auricle. After preparing this flap, the skin defect is easily closed by sutures (Figs. 5 and 6, Plates I. and II.), the anterior margin (*g f*) being fastened to the posterior margin of the bony wound. In tamponing through the meatus the upper flap is pressed against the bone, and the quadrilateral flap is held in position by a probe (Fig. 1 in the text) and also by the tampon.

To judge from the sketch, one would think that the formation of the flap as suggested was complicated in comparison with that of other otologists, but it can be easily learned, and takes about fifteen minutes to form. I first took a flap from the neck, now I take it from behind the auricle, so that the scar is very small. Before, a view of the parts was difficult, now it is easy. I generally use thirteen needles, with catgut or silk, as the case may be. The retro-auricular opening which results is slit-shaped (Fig. 7, Plates I., II.), can be easily covered with plaster, and is hardly noticeable, but it can be easily enlarged by pulling the auricle forward, and so give a full view of the interior of the cavity. During the after-treatment it contracts about one half (Figs. 7 and 8).

When the cavity is small the quadrilateral flap is made smaller, or larger with a large opening. In this way I can alter the opening as I happen to think best. In the same way large and disfiguring openings can be spared the patient. By imagining the flap in Fig. 6 drawn upward, one can see how the opening can be altered in size. The same plan can be employed in sinus thrombosis or other operations, except when a previous scar prevents the formation of the quadrilateral flap. So, too, the risk of covering in dead bone can be avoided. If the tip of the mastoid is suspicious, it can be removed before rotating the lower flap, whilst on the upper wall of the cavity to which the meatus flap is transplanted, everything suspicious can be got rid of, if necessary, by exposure of the dura.

With reasonable recovery the cicatrization is rapid, because most of the cavity is covered with healthy skin. If the formation of epidermis is slow, I encourage it with skin-

grafting, but only when the secretion is slight, and there is no inclination to granulations. I generally transplant on the fourteenth day, and flat granulations are scraped off after preliminary cocainization. Pain during this manœuvre means that the granulations have been let too long alone, or that diseased bone is present. Grafts can be taken from the arm by Schleich's anæsthetic method and the whole cavity covered in; generally every graft attaches itself.

The radical operation has been done in my clinique the past year 54 times, including 15 for cholesteatoma. The complications included 6 periosteal, 5 perisinuous abscesses, 5 sinus thromboses, and 1 meningitis. No fatal cases occurred from the operation. Two died from thrombosis, and one from meningitis. The latter case was only attempted at the urgent wish of relatives. One case of thrombosis showed at the autopsy a cerebellar abscess, and the other metastatic pulmonary abscess. Two of the patients died six weeks afterwards from pulmonary tuberculosis, and another six months later from laryngeal tuberculosis.

This leaves 49 cases, 2 of which coming at intervals for change of bandage are still uncured; 3 left, of whom we only know with certainty that 1 was uncured, and 1 had to be operated again.

Of the 44 traceable, the after-treatment averaged 15 weeks. We call it cured when the whole channel is cicatrized. There was 1 case of relapse, 3 of occasional eczema. The average treatment of 18 patients treated in various ways, with and without skin-grafts and flaps, lasted twenty weeks.

Twenty-six patients operated as herein described had an average treatment of 11 weeks. If we leave out two patients who took 22 and 28 weeks to recover, my average time of recovery would be better even than 11 weeks. One of these was treated at home after operation, and the other was not skin-grafted until many weeks after the operation. The shortest time was 3½ weeks. The longest 44 weeks, in a boy with weak heart, extensive mastoid caries, and perisinuous abscess. The radical operation was done for this boy in twenty minutes, and in my haste I probably overlooked

some caries. But we could not keep him too long anæsthetized.

Relapses may still occur in this list, but my fears of this accident are small judging from the appearances of the cicatrix. The average time of cure for cholesteatoma was about 13 weeks.

It is difficult to decide when the secondary closure of the retro-auricular opening should be attempted. We must in every case weigh the *pros* and *cons*, and must rather let the fistula exist too long than too brief a time. In cholesteatoma I only decide on this point at a late date. Generally I am influenced by the width of the meatus.

I *perform secondary closure* by first producing Schleich's anæsthesia, and then making at the outer margin of the orifice an oval incision, which must not lie inside the cavity. The skin is then loosened freely away, together with the periosteum, and so made very movable. This results in leaving four margins, as shown in Schema 1, Fig. 2, adjoining;

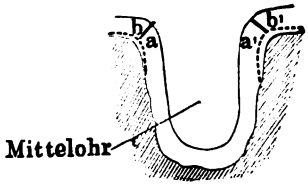

FIG. 2.—Schema 1.

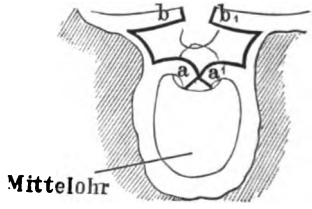

FIG. 3.—Schema 2.

that is to say, two inner margins (a, a') and two outer (b, b'). The two inner ones are turned over towards the inner ear and so sutured that fresh surface lies next to fresh surface. This is accomplished with bent eye-forceps and a modified Bowman needle (compare Fig. 5 in the text). Then with three sutures the two external freshened surfaces are likewise sutured and drawn together as in Fig. 3. In this way we cover the retro-auricular orifice with a bridge which is cuticular in both directions. By this method we can cover in defects both large and small, and save osteo-plastic operations. Additionally we can thus correct any misplacement

of the auricle produced by the original operation. Recovery by first intention follows, and no disfiguring scar results.

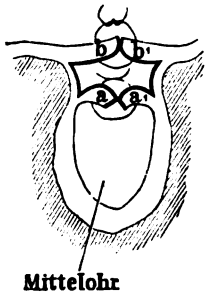

FIG. 4.—Schema 3.

FIG. 5.

To sum up, we can truly say, from experience, that this method has served us well in Heidelberg, can be easily performed, the plastic operation enables us to cover a large portion of the bony cavity with healthy skin, we can make the retro-auricular opening large or small, skin transplantation hastens the recovery, the after-treatment is simple, after-operations can be easily performed, the orifice can be temporarily covered with plaster, is small and not disfiguring, the time for cure is brief, when the epidermis has formed the opening can be rapidly closed without narcosis, and the time at which this has to be done, considering the condition of the cicatrix, depends wholly on the operator's opinion.

BIBLIOGRAPHY OF PAPERS ON THE RADICAL OPERATION FOR MIDDLE-EAR SUPPURATION.

STACKE, *Die operative Freilegung der Mittelohrräume*, 1897.

GRUNERT, *Beitrag zur operativen Freilegung der Mittelohrräume*, 1896.

SIEBENMANN, "Cholesteatoma," *Berl. klin. Wochensch.*, 1893, No. 1.

KOERNER, *Arch. f. Ohrenhlkde.*, Band 37, p. 130.

KRETSCHMANN, *Klin. Vorträge*, Band ii., Heft 1; *Arch. f. Ohrenhlkde.*, Band 37, p. 25.

PANSE, *Arch. f. Ohrenhlkde.*, Band 34.

JANSEN, *Vortrag*, Dresden, 1897.

GRUNERT, *Arch. f. Ohrenhlkde.*, Band 35.
SCHMIEGELOW, *Zeitsch. f. Ohrhk.*, Band 25.
HOLMES, *ibidem*, Band 25.
BARNIK, *Arch. f. Ohrenhlkde.*, Band 42, p. 96.
REINHARD, these ARCHIVES, vol. xxiv., p. 156.
MÜLLER, *Charité Annalen*, Band 21.
MORF, *Mitheil. a. d. Kliniken. d. Schweiz*, iii. Reihe, Heft 7.
ZAUFAL, *Arch. f. Ohrenhlkde.*, Band 37, p. 76.

THREE CASES OF BRAIN ABSCESS FOLLOWING OTITIS MEDIA.

By ARTHUR H. COE, M.D., Spokane, Wash.

THE following cases of brain abscess are reported with the thought that each possesses points of interest and unusual symptoms that may be of value to the profession. I was fortunate in securing an autopsy in each case, so that the records are complete.

Case I.—**Acute purulent otitis media. Mastoid and intracranial complication. Death from double abscess in the frontal lobe and meningitis.**

W. W., age twenty-eight, a wood-chopper from Heron, Mont., presented himself for treatment, with the following history. Some months previous he had severe pain in the left ear for a week or ten days, followed by a free discharge of pus which continued for some days, then chills and high fever, with vomiting, and great pain over the left side of the head. This condition gradually got better, and there was marked improvement in hearing, though the discharge still continued.

On examination there was found to be quite a free purulent discharge from the middle ear, with granulations arising from the upper wall, and evidences that attic suppuration had continued for some time, and that pus had burrowed above the drum and broken into the canal. No history of any nervous disorder, or of any specific disease.

Under treatment he began to improve as to diminution of discharge and increased hearing distance. About two weeks later, however, his appearance was not so good; he had daily elevation of temperature from one to two degrees, with more or less pain in the ear and side of the head, appetite poor, and tongue coated. The discharge from the ear was still quite free.

He was taken into our private hospital, the canal was irrigated with hot water, and three leeches were applied to the base of the tragus, bleeding being encouraged. Following this he felt much better, pain and fulness in the head decidedly improved. Two days later, however, the temperature rose to 102.5°, with increase of pain in the ear, and the discharge became less free. There was some tenderness over the mastoid, and some slight redness running down the sterno-cleido-mastoid muscle. While the signs of mastoid involvement were not very marked, it was thought that pus must be present, and that his condition warranted an operation.

Under ether, I opened the mastoid antrum by the usual incision and Buck's trephine. The probe passed freely into all the cells, but no pus was found. The cavity was irrigated and packed with iodoform gauze. The next morning there was a free discharge of pus from the mastoid; the condition of the patient, however, was better, the temperature declined to 100°, and the facial expression improved.

The progress of the case for four or five days was uneventful, but on the fifth day the temperature went up to 103.5° and the pain in the head and ear became severe. The discharge from the ear was still quite free. Next day the patient had a chill, the temperature rose to 105°, but there were no signs to indicate where the pus was retained.

Some days later there was noticed a swelling of the neck along the sterno-cleido-mastoid muscle, with some tenderness. During all this time the patient had many severe chills, with a temperature often reaching 105 to 105.5°, accompanied by severe pain in the side of the head.

Our opinion was that pus had broken through the bone just inside of the insertion of the muscle to the mastoid process and had burrowed down the sheath of the muscle, or, possibly, had found an exit with the jugular vein, and was contained within the sheath of that vessel. Under cocaine, I made an incision along the anterior border of the sterno-cleido-mastoid muscle, and carefully separated and turned it back; but outside of a swelling and indurated condition of the body of the muscle, nothing was found.

Patient took nourishment and stimulants well, and continued in about the same condition for some five days, when the swelling in the neck was decidedly more apparent and tender to the

touch, and on several occasions it was thought fluctuation could be detected, so I introduced an aspirating needle through the body of the muscle, and pus was found, being contained between the inner border of the muscle and its sheath, and directly over the jugular vein. The pus cavity was opened by the Hilton-Roser method, *i. e.*, retaining the needle in place as a guide, a grooved director was insinuated along this, and, later, a pair of delicate dressing forceps, which, being widely opened, gave vent to about two ounces of thick greenish-yellow pus. The opening was enlarged, irrigated, and a drainage tube inserted. Improvement was manifest at once by a fall of temperature and pulse, and relief from pain and tension.

The discharge of pus was very free for some days, when it gradually ceased and the cavity filled up. All the time this process was going on the discharge still continued from the external meatus.

A fair condition of the patient continued for a week or ten days, when it was noticed that the right leg was not moved as freely as the left, and this became more apparent from day to day. There then came on intense headache, confined to the left temporal and frontal regions, causing the patient to groan and cry aloud for hours at a time. No medication had any effect on this pain, the depression and vomiting caused by morphine being worse than its slight and transient anodyne effect. The temperature most of the time was normal, pulse 60 to 70 and full ; there was a tendency to constipation ; no delirium, and none at any time during the progress of the case, and no symptoms referable to the eyes.

The *paralysis of the leg was now decided, and gradually involved the right arm and hand. At this time there was also hesitancy in speech and loss of memory for words.* Patient lay in a semi-stupor ; at last paralysis of the facial muscles of the right side supervened. During the last few days of this period there was no complaint of pain, but soreness was present on striking the head over parietal bone.

The symptoms and course of the case for the succeeding ten days presented a classical picture of cerebral abscess, with the exception that, assuming the pus to have originated from the diseased condition in the temporal bone, the motor areas were involved in just a reverse order of the usual. For, if you will remember, the centres for face, arm, and leg are situated on each side of

the Rolando fissure, with the face centre the lowest and nearest to the seat of trouble in this case, while the leg centre, which first showed involvement, is the highest and at the upper curve of the cerebrum. Notwithstanding this contradiction, the majority of symptoms pointed so strongly to pus within the cranial cavity that it was thought best to operate, with the hope of discovering and evacuating the pus. The point selected for the application of the trephine was in the so-called dangerous area of Barker, where eight out of ten abscesses originating from middle-ear suppuration are located. This area is a circle with a radius of one and a quarter inches, situated one and a half inches above and behind the external meatus. Notwithstanding the fact that this point was somewhat posterior to the motor centres involved, their region could be easily reached by a probe, and the fact of the contradictory symptoms in the motor involvement led us to think best not to go directly down on them.

The head having been shaved and rendered aseptic, the patient was anæsthetized with chloroform, but, the heart not acting kindly, ether was substituted, which was entirely satisfactory. I made a horseshoe-shaped incision down the skull, which was perforated with a three-quarter-inch trephine, and a button of bone was removed. The dura, which was slightly congested, being exposed and opened by a crucial incision, a probe was passed between the dura and brain in all directions for some two and a half inches. Later a thorough exploration was made inside the dura, but without result. The opening was carefully washed out with boric-acid solution, and, on account of slight venous oozing, was packed with iodoform gauze, and the incision closed and dressed.

He recovered from the anæsthetic nicely, there being, however, a slight internal strabismus during the rest of the day. The gauze was removed on the following morning, and union of the wound was primary, without an untoward symptom.

The condition of the patient on the succeeding days was not encouraging; there was involuntary evacuation of the bowels, semi-stupor, great difficulty in talking, but no complaint of pain. He remained about the same for ten days or two weeks, there being complete loss of control of sphincters, and the patient was in a pitiable state.

About the eleventh or twelfth day after the operation his face was brighter, he had improved appetite, and his general condition

was somewhat better; and in the succeeding three days his strides toward recovery were wonderful; the paralysis disappeared, the control of the bowels and bladder was regained, his appetite became ravenous, and he was soon up and walking about; since when he has gained in weight and strength, until now he is in his usual state of health, except a slight amount of facial paralysis, which still remains.

Examination shows the ear to be perfectly dry, with hearing power very fair. At no time during the case was there vomiting which could be attributed to the disease; several times it was present, but always followed the exhibition of morphine.

Such is a brief outline of a case which is remarkable, for, notwithstanding the very grave period of septic intoxication and the absolute cessation of the motor functions of the entire right side of the body and the sphincters, the patient was transferred in some three days from a condition of the most pitiable helplessness to one of comparative health.

The most interesting point for discussion is: What caused the pressure in the cranial cavity on the motor centres, and why were they involved in reverse order? The probabilities were against its being an abscess, for so thorough an exploration as was made would have detected pus if present; and, again, the improvement could not have been so marked and rapid unless the abscess was evacuated; and, lastly, the pus could not readily have formed so high up as to involve the leg centre first, and then work downward. My opinion is, that the constant irritation of the diseased process on that side of the head set up a localized meningitis with congestion and transient thickening of the membranes sufficient to cause pressure on the motor centres, and that the subsidence of this relieved pressure, and the centres not being seriously involved, they rapidly recovered their natural condition.

The patient left the hospital and resumed his occupation as wood-chopper, but in about two months returned, and examination showed the following condition: The facial paralysis had nearly disappeared, the ear perfectly dry, and hearing very good, no interference with motility of arm or leg. He complained of intense pain, loss of appetite and

strength. His condition grew rapidly worse, stupor deepening into coma, and finally death with all the symptoms of brain compression. At the **autopsy** on the following day, I confined my examination to the cranial contents.

The dura was normal except over the motor areas on the left side, where it was closely adherent, being detached with difficulty; it was greatly thickened and there was considerable inflammatory deposit of a fibrinous nature on the cortex.

The area of the adhesion and thickening corresponded exactly to the motor areas of face, arm, and leg.

On section of the *left* hemisphere, an abscess was found occupying the *lower and central portion of the frontal lobe.* It consisted of two distinct sacs, the larger the size of a hen's egg, having walls of considerable thickness. The smaller sac gave evidence of more recent formation, by its thinner and less organized walls. The cerebral tissues were softened even for some distance from the sac and broke down readily.

On account of the depth of the abscess from the surface, it was not strange that I failed to locate the pus, at the time of the operation.

It is my opinion that the conjecture made in the first place as to the paralysis being caused by the local thickening of the meningitis was correct and that the abscess had nothing to do with the paralysis, for on his return there were no symptoms of paralysis, and the abscess was not only there, but probably larger and in a more active state. I do not mean to imply that there was no connection between the meningitis and the abscess, but that the pressure causing the involvement of the motor centres was occasioned by the meningitis.

CASE 2.—**Acute relapse of old purulent otitis. Death from abscess in temporal lobe.**

J. C., æt. forty-six, painter, had been suffering for some three weeks with an *acute otitis* when I first saw him. There was intense pain, at times so severe as to produce symptoms of mania, when he would get up and escape from the house and wander about the yard in his night-clothes. There was a fairly free discharge of muco-pus from the left auditory canal. There is a history of previous attacks of otitis, and scars showing a double

mastoid operation had been done,—patient says when a child. Temperature ranged from 99° to 100°, pulse from 80 to 90 of good quality. No specific history obtainable. He was removed to the hospital and for some days his condition remained unchanged. The only symptoms at this time were the intense pain and slight hesitancy in speech, but as the patient has been very deaf for years, this was attributed largely to the deficient hearing. There was considerable tenderness over the left side of the head, not decided over the mastoid, however; nevertheless I thought it advisable to open the mastoid, which I did, finding almost complete obliteration of the antrum and mastoid cells. I thoroughly cleaned out the middle ear and tympanum, but only a small amount of ichorous pus was evacuated. There was no improvement in his condition. There was more marked dulness and the patient took little or no nourishment. The eye grounds were examined repeatedly with negative results. Absolutely no symptoms of compression, and normal motility over the whole body. The temperature was normal, pulse 60 to 70. While I felt certain that there was intracranial involvement, the absence of any compression symptoms, and with nothing but the intense pain and slight mental dulness to guide me, I made a diagnosis of subdural abscess. The location presumed to be over the roof of the left tympanum.

The case was watched for a few days, but there being no change the patient was anæsthetized, and the scalp having been shaved and rendered aseptic, I made a horseshoe-shaped incision down to the bone, the centre point of which was about an inch above and slightly backward from the meatus. A button of bone about an inch in diameter was removed, disclosing a normal dura. A probe was passed in all directions as far as possible between the skull and dura, with negative results. I then incised the dura and repeated the exploration with a like result. The condition of the patient at this time was bad, pulse was very poor and face cyanotic. He was given a hypodermatic injection of $\frac{1}{25}$ of a grain of sulphate of strychnia, and the anæsthetic suspended. I intended to explore the cerebrum proper with trocar, even though the symptoms did not warrant the belief that an abscess existed within the brain tissue. I made one or two punctures forward and downward, but the condition of the patient was so poor that my confrères advised against continuing the operation. The wound was rapidly closed and dressed, and patient removed to bed, sur-

rounded with hot-water bottles, and stimulated. His return to consciousness was much delayed, and thereafter, until the time of his death four days later, there was extreme stupor deepening into absolute coma.

The following day I did an **autopsy,** limiting my examination to the cranial contents. The meninges and cortex were found normal. On making sections of the left cerebral hemisphere a small abscess cavity was discovered in the temporo-sphenoidal lobe, about one inch below the surface, directly under the point where I had made the trephine opening. The pus cavity was traced downward to the upper surface of the petrous portion of the temporal bone, and a minute sinus was found extending into the tympanic roof through the superior plate of the bone, thus determining a point of direct infection. There was some pus bathing the upper surface of the petrous portion of the bone. The total amount of pus was not over one ounce. It was very unfortunate that the exploration in this case was not continued farther, as, in all probability, the pus would have been discovered, and the patient given a chance for recovery.

CASE 3.—**Acute purulent otitis media and mastoiditis. Death from cerebellar abscess propagated through the inner ear.**

Mrs. H., aged twenty-eight, housewife, presented herself for treatment with the following history: Some weeks ago she had severe pain in the right ear, which finally culminated in a discharge of pus and some relief from the pain. The ear had discharged freely for some weeks, but finally the pain began again, and the discharge became less free. She had considerable headache and some dizziness; a physician whom she consulted gave her drops to put in the ear for the pain, and a powder to be blown into the canal. This only added to the trouble, as it hardened and retarded the outflow of pus. The pain became more decided, and there gradually developed a facial paralysis on the right side. Her condition at the time of my first examination was as follows: Canal of right ear swollen and tender, the bottom completely filled with several polypi, leaving only a minute opening for exit of the discharge; the temperature was $100\frac{2}{5}°$, pulse 108; mastoid region somewhat tender. Decided right-face paralysis, probably from erosion of the nerve within the canal. With curette and

forceps the polypi and granulations were thoroughly cleaned out from the bottom of canal, showing a drum partially destroyed and bare bone in all directions. Instructions were given for irrigation of the canal with hot water, and a mixture of potass. bromide and chloral hydrate was ordered for its sedative effect.

Her condition was somewhat better for a few days, but it was evident, from the continuance of temperature and pain, that the mischief was done, and the trouble was deeper than the middle ear. She was removed to the hospital, and I did a thorough mastoid operation, liberating pus freely and much granular tissue from the antrum. I also removed a portion of the wall between antrum and canal. Her condition did not improve as it should have done after the operation, which, together with the increasing stupor and the intense head pain, referred to the vertex, made it clear to me that there was infection within the cranium. The symptoms were so vague that to locate the abscess was an impossibility, as she had no compression symptoms, only occasional vomiting and dizziness; the temperature was now normal, and pulse from 60 to 80, only fair in quality. The fundus of both eyes was carefully examined, but there was no optic neuritis found. The pupils were both moderately dilated, and responded rather tardily to light. She took nutriment very poorly, and her condition was rapidly failing. Without definite points to guide me, I located the abscess above the petrous portion of the temporal bone, because that was the point of infection, and the majority of abscesses from otitis media are found in that region, so I decided to make the trephine opening just above and behind the external canal. The operation was set for 8.30 on the following morning, but when we reached the hospital she had failed so much during the night, that the physicians who saw her in consultation advised against operating, as her chances of surviving the shock of operation were few. The stupor increased, she gradually sank, and died early the next morning.

An exceedingly remarkable state of affairs was found. At the **autopsy,** on removal of the calvarium, the meninges and cerebrum were found congested, but otherwise normal. When the tentorium was divided along the *upper border of the petrous portion of the right temple bone, pus exuded from the internal auditory canal.* The outer surface of the petrous portion of the bone had a normal appearance, but when the

outer casing was removed, the entire inner structure of the bone was honeycombed. The inner wall of the middle ear was destroyed, as were also the semicircular canals; there was a large opening between the middle ear and the mastoid antrum. The cell walls of the mastoid were destroyed, forming one large cavity. Following the pus backward there was found an *abscess* cavity which was moderately well defined in the *right cerebellum* near the median line, with pus diffused in the surrounding tissues; we estimated that the cavity contained about two ounces of pus.

Unfortunately, the position of the abscess was such that it produced no symptom to direct us to its location, and even had I known absolutely where it was, an operation to evacuate it would have been exceedingly hazardous, and in all probability unsuccessful.

It is a trite saying that we often learn more from an unsuccessful case than from those that have a more fortunate termination, and the hope that some points have been brought out which may be of value to others, has led me to report these my unsuccessful cases of brain abscess.

A CASE OF CHRONIC SUPPURATIVE OTITIS MEDIA, FOLLOWED BY CEREBRAL ABSCESS AND SUPPURATIVE MENINGITIS—OPERATION—DEATH—AUTOPSY.

By EDWARD B. DENCH, M.D.

The patient, a Cuban, about thirty-six years of age, came under my observation at the New York Eye and Ear Infirmary, with a history of having suffered from intense pain in the left side of the head for about two and a half weeks. During a part of this time, according to the statement of his friends, he was delirious. For a number of years the patient had been subject to repeated attacks of severe headache, confined to the left side of the head; the present attack, however, had been more distressing than any of the preceding.

Upon otoscopic examination both drum-membranes were found to be destroyed, and there was a small amount of fetid pus in either tympanum. Pressure over the left mastoid elicited no tenderness, and palpation of the neck gave no evidence of jugular or lymphatic involvement. There was slight tenderness upon percussion over the left temporo-sphenoidal region. The patient was greatly emaciated, and presented all the signs of severe constitutional infection. The temperature upon admission to the hospital was 102°.

Under the ordinary aseptic precautions, I **operated** upon the left mastoid, having made the necessary preparations to enter the cranial cavity, in case this seemed desirable. The mastoid was sclerotic throughout. The antrum was situated at a depth of about seven eighths of an inch below the surface, and was exceedingly small. After reaching the antrum considerable *cholesteatomatous* material was removed both from this cavity and from the tympanic vault by means of the curette. The antrum and tym-

panic vault were then made continuous with the external auditory meatus by the well-known Stacke-Schwartze procedure. The posterior wall of the membranous external auditory canal was split longitudinally, thus making two flaps which could be pushed into the bony cavity. Owing to the short time which the case had been under observation, and to the possible necessity of future operative procedure, the wound in the soft parts was not sutured. The external auditory canal and the cavity in the bone were packed with iodoform gauze, and the ordinary antiseptic dressing applied. The headache was somewhat relieved by this operation, but the temperature steadily rose until, on the following afternoon, it reached 103.8°. The temperature then fell spontaneously, but again rose in the course of a few hours to its former height. A little over twenty-four hours after the first operation the patient developed distinct symptoms of *amnesic aphasia*. As an intracranial lesion had been suspected from the first, I did not hesitate, after the development of this symptom, to enter the cranial cavity. The original incision was extended forward to the external angular process of the frontal bone, and the cranial cavity entered about an inch above the external auditory canal. The meninges were found intensely congested and somewhat thickened. A meningeal flap was reflected, and the brain substance was explored by means of a large aspirating needle. At first nothing but broken-down brain tissue was obtained upon aspiration. At the next insertion of the needle, however, a little turbid fluid was withdrawn. A knife was then plunged into the temporo-sphenoidal lobe and a free incision made. A large amount of broken-down brain tissue was immediately discharged from this opening. The index-finger was introduced into the opening, and entered a large abscess cavity in the temporo-sphenoidal lobe. Little or no pus was present, the contents of the cavity consisting almost entirely of broken-down brain tissue. By the cautious use of the finger this softened tissue was removed as completely as possible, until the firm limiting walls of the abscess cavity could be made out. A strip of sterilized gauze was next passed into the opening in the temporo-sphenoidal lobe for the purpose of drainage. The surrounding region was protected by iodoform gauze, the soft parts replaced, and the usual antiseptic dressing applied over the entire wound. Immediately upon recovering from the anæsthesia, the aphasia disappeared. The temperature also fell about a degree and a half. A few hours later, however, the patient had a

chill, and the temperature began to rise slowly. Owing to a necessary absence from town, I at that time placed the case in the hands of one of my colleagues. Twenty-four hours after the second operation the dressing was removed, for the reason that the temperature still remained high; upon the application of a fresh dressing the condition of the patient seemed to be improved, the temperature falling to 102°. This improvement was only temporary, however; the temperature steadily rose, and finally reached 106°. Death followed on the fourth day after the opening of the temporo-sphenoidal abscess.

The **autopsy** revealed a purulent leptomeningitis, involving the entire left side of the cerebrum. The abscess cavity in the temporo-sphenoidal lobe corresponded exactly to the condition made out at the time of the operation. No other abscesses were found in any portion of the brain. The left lateral sinus contained a moderately firm clot which did not extend below the sigmoid portion. This clot was evidently several days old, and, without doubt, explained the sudden and excessive elevations of temperature from which the patient suffered. There was also a recent clot in the torcular, and in the lateral sinus of the opposite side. The roof of the tympanum was carefully examined, but no perforation was found. From the condition of the bone in this region, however, and from the thickening of the overlying dura, it seemed probable that infection had taken place through the communicating veins. It is impossible to say how long the abscess had existed in the temporo-sphenoidal lobe. Not infrequently these purulent foci remain latent for a long time, and only become active as the result of some exciting cause. It is probable that the meningitis remained localized for a considerable period, and became diffuse only a short time before the patient came under observation. Had the patient applied for relief when the symptoms first appeared, there seems to be no question as to the fact that recovery might have followed operative interference.

A CASE OF PERISINUOUS EPIDURAL ABSCESS, WITH FACIAL PARALYSIS.—OPERATION.—RECOVERY.

By FRED. WHITING, M.D.,
AURAL SURGEON TO THE NEW YORK EYE AND EAR INFIRMARY.

THE rapidity with which, under circumstances favorable to the attack, purulent processes of the middle ear invade and infect adjacent structures, has been the occasion of frequent remark and a fertile source of discussion, the bacteriological features of which afford a theme of engrossing interest.

The observation was long ago recorded that certain micro-organisms, uniformly present in greater or less abundance in suppurative ear diseases, develop, when operating in the presence of other pathogenic germs, greatly increased activity and intensified virulence, as, for example, during the systemic disturbance incident upon measles, scarlet fever, or grippe. Under such circumstances extensive destructive changes take place in the bony walls and investing membranes of the cavities of the temporal bone, and extend thence with dismaying rapidity to the meninges and other intracranial structures. Whether the resistance of the tissues thus involved is greatly reduced by nutritive changes in the blood, attendant upon general infection, or whether the complementary action of the systemic germ so exaggerates the destructive force of the local infection that ordinary resistance does not avail, is most interesting speculation, and neither theory is lacking in supporters.

Upon one point, however, the experience of all honest

observers is in accord, namely, that while a large proportion of the cases of suppurative ear diseases, if recognized early, are amenable to successful clinical treatment, there is a certain proportion of cases which, no matter how early they are seen, or what measures—antiseptic, prophylactic, or antiphlogistic—may be instituted for their arrest, progress unfavorably, and the course of the disease is in no wise retarded nor its virulence in any degree abated. These cases do badly from the beginning, and the patient is simply beguiled by the futile efforts of his medical adviser.

It is impossible to doubt but that in two varieties of cases essentially similar in many of their manifestations, but dissimilar in termination, the one progressing uniformly favorably, the other with equal uniformity unfavorably, the nature and quality of the infecting germs must radically differ, and the self-complacency of that enviable practitioner whose cases always do well and never experience serious complications is liable to rude and sudden shock in encountering just such a malady, and the patient will be lucky indeed if, while serving to disillusion the fatuous physician, good fortune so far attend upon him that his life is spared, in spite of misdirected professional ministrations.

My own practice has afforded several embarrassing demonstrations of the futility, under certain circumstances, of all recognized forms of treatment, and so strong has become my conviction in this regard that it can be formulated in the following proposition: the course and termination of otitic affections are, in certain instances, dependent upon the virulence of the *initial infection alone*, and are absolutely *uninfluenced by any clinical measures* for its relief.

The history of a case which forcibly illustrates the unfavorable course pursued by an otitis, in which, in spite of early recognition and intelligent and unremitting care, the disease progressed, resulting in a grave and well-nigh fatal complication, is here appended:

A few weeks since, I was requested by Dr. Noyes to see with him in consultation a patient, a girl of fifteen years, who had been under observation for nine days. The illness began with a severe

coryza, upon which acute catarrhal otitis media supervened, accompanied by moderate pain and slight pyrexia.

When called to the case, Dr. Noyes found, upon physical examination, a membrana tympani, red in color and bulging forward and downward in the superior posterior quadrant; there was no sagging of the membranous canal; the mastoid aspect presented a normal appearance, and very firm pressure in this region was required to elicit signs of tenderness. Myringotomy was immediately performed, which resulted in the evacuation of a small quantity of sero-sanguinous fluid, in which the presence of pus could not be with certainty determined.

Hot douching every two hours was employed, without, however, marked alleviation of the symptoms, the pain in the ear, with scanty discharge, persisting during the following five days.

Upon the sixth day patient had almost entire relief from pain, and the discharge was no longer noticeable. She said that for the first time since the earache began, she felt quite comfortable. Upon the afternoon of this same day, when awakened from "a nap," she became conscious that her right eyelids did not close properly, and that she could not whistle; at the same time the distortion of the features was noticed by members of her family.

Conditions remained unchanged during the seventh and eighth days; there was but slight discomfort from the ear and practical cessation of discharge. The facial paresis was a little more pronounced. The temperature, which had been recorded three times daily, averaged 99.5° F., the highest point registered being 100.5° F.

When called to see her, the following appearances presented themselves upon physical examination:

The membrana tympani and membrana flaccida were bulging downward and forward sufficiently far to conceal the short process of the malleus. There was also a slight sagging of the superoposterior segment of the membranous canal. A minute perforation in the inferior posterior quadrant of the membrana tympani could be recognized as the site of the paracentesis performed several days previously, and from this opening there protruded a small thread of sticky, firmly adhering plastic lymph acting as a most effective obstacle to drainage. The mastoid aspect was negative upon inspection, but firm pressure over the site of antrum, and tip as well, elicited an immediate response from the patient which effectually dispelled all doubts regarding mastoid tenderness.

Immediate operation was advised, and was performed upon the afternoon of the same day at the New York Eye and Ear Infirmary.

A curvilinear incision was made one quarter of an inch behind the post-auricular fold, extending from one half inch below the mastoid tip upward about one half inch above the temporal ridge. Flaps retracted, periosteum normal in appearance and easily elevated as far downward as the lower third of the process, where the tendinous attachment of the sterno-mastoid and other muscles required to be divided with the scissors, that the exposure of the tip might be satisfactory.

A round and narrow apophysis was exposed with small, almost rudimentary supra-meatal spine and foramen; cortex appeared quite normal and exhibited several small cribriform areas for the transmission of nutrient periosteal vessels. The cortex was first removed in a narrow groove, with a gouge, close to the posterior canal wall from the supra-meatal spine to the tip. As soon as the cells were encountered they were found to contain firm granulation bodies, and a probe introduced under the overlying cortex could be passed in several directions for varying distances, not with the unimpeded sweep with which a sound traverses a spacious cavity, but following along separate radiating channels. Upon removing the remaining cortex these sinuses were found running through the cellular structure of the process and apparently coalescing just below and externally to the antrum. They were filled with firm granulations, the osteitis presenting all the characteristics of osteo-porosis, the granulations being osteoclasts under whose action the basement substance of the bone was rapidly absorbing. Upon all sides of these inflammatory tracts were irregular, small indentations, also filled with granular cells, the so-called Howship's lacunæ.

As soon as the antrum was opened there escaped a gush of gas and a few drops of pus, and upon exploring the roof of the tympanum with a probe, a small opening was encountered which communicated with the middle fossa and from which simultaneously with the introduction of the probe some bubbles of gas escaped, but no recognizable pus. The posterior bony canal wall was now cut away, the aditus opened, and the ossicles (malleus and incus) removed, also the tubercle of the zygoma and the tegmen tympani and antri. This procedure resulted in exposing a mass of plastic lymph investing all that portion of the temporo sphenoidal lobe

resting upon the superior surface of the petrous bone and extending downward and backward into the cerebellar fossa along the course of the descending portion of the sinus sigmoideus and apparently as far backward on the posterior surface of the petrous pyramid as the internal auditory meatus. The lymph at the periphery of the opening in the skull was firmly adherent, and tightly sealed off the abscess cavity from the surrounding meninges, but the central portion was soft and bulging, and that a view of the sinus might be had for its critical inspection, was subjected to careful traction, when it readily came off in long sticky strips, discovering the sinus wall to be reddened and lacking its usual shiny lustre, but not apparently thickened, and inasmuch as it readily dimpled beneath the finger, and pulsated as well, aspiration was not resorted to, but the sigmoid groove was more extensively cut away in order that should symptoms subsequently arise indicating a septic phlebitis, the necessary operative procedures for the relief of such a condition would be greatly facilitated.

The entire mastoid process was removed, and in the large pneumatic space at the tip and in several of the smaller adjacent spaces a dark semi-turbid fluid was found almost of the color and consistency of coffee dregs; this was free from odor. In cutting away the bony canal wall and aditus, the tympanic course of the facial canal was carefully scrutinized and found to be free of all caries. The bone was not even roughened anywhere in the vicinity, so that I assume the wall to have been inviolate.

After thorough cleansing and packing of the deeper portions of the wound with iodoform gauze, the flaps were stitched at the upper angle, and the remainder of the wound dressed open.

During the days immediately following the operation, the patient was cheerful and exhibited no symptoms indicative of sinus or other intracranial involvement. She had for some time an afternoon elevation of temperature averaging 100.4° F., for which the healthy appearance of the wound and the comfortable condition of the patient failed to account. However, upon orders being given that all visitors should be excluded, the temperature speedily subsided and all elevations were thereafter insignificant.

The rapidity with which the facial palsy disappeared subsequent to operation was most gratifying. Twenty-four hours after operation there was noticeable a distinct improvement in the actions of the affected muscles, and with each succeeding day the disability diminished, until on the tenth there was, so far as the

patient knew or close observation could discover, complete restitution of function.

So brief had been the duration of the inflammatory stage in this case that the vitality of the patient had not suffered great impairment, and the subsidence of her surgical fever marked the beginning of a speedy and uninterrupted convalescence.

Physical examination at the present date shows slight narrowing and drooping of the membranous canal at middle third, complete reconstruction of the membrana tympani, which was looking rather thin and atrophic. Mastoid aspect exhibits a few cutaneous granulations at the site of the original incision, in the healing of which no deformity or displacement of auricle has resulted.

The features of especial interest in this case are: *first*, the remarkable rapidity with which the purulent process invaded the skull and attacked the meninges. Whether this was due to the presence of a dehiscence or fissure in the roof of the tympanum, having only a membranous wall which speedily succumbed to the inroads of ulceration and opened an avenue for the entrance of pathogenic germs—or whether the suppuration spread along the course of a small vein perforating the tympanic roof and thus gaining access to the adjacent dura, whence it extended itself along the petrous bone backward into the posterior fossa, and inward sufficiently far toward the apex of the petrous pyramid until pressure was made upon the trunk of the facial, at or before its entrance into the foramen—or whether, again, the initial virulence of the germs contained in the pus confined in the attic expended itself in eroding the tegmen tympani, will remain a matter for interesting but unproductive speculation. In any event there was a perforation in the tympanic roof and the progress of the inflammation from that point was by direct contiguity.

Second, the extraordinarily early appearance of facial paralysis in the course of an acute otitis, in a patient otherwise in perfect health and who had never before suffered from ear disease. Had such a complication manifested itself early in the progress of an acute exacerbation of chronic suppurative otitis, it would not have occasioned special remark, or, in the absence of other symptoms, excited grave appre-

hension; but under the foregoing circumstances it was regarded as indicating at least a strong probability of intracranial involvement, which the subsequent findings of operation amply verified.

The rapid restoration of function of the facial was quite to be expected after the removal of the lymph and granulations which made pressure upon the nerve trunk at its entrance to the petrous bone. In this connection it is of interest to note that the audition of the patient, which was markedly embarrassed before operation, still shows very great impairment, as might be anticipated in view of the extensive traumatism to which the conducting apparatus was subjected. That the disability lies mainly in the middle ear is easily recognized by a glance at the appended functional examination made upon patient ten days ago:

FUNCTIONAL EXAMINATION—RIGHT EAR.

Watch = 0.
Acoumeter = 1 ft. Bc. > Ac.
Forced whisper = 4 ft.
Weber { Vertex, Brow, Incisor teeth } Strongly lateralized to the right (operated ear).
Upper tone-limit = Galton (Dench) 1.^{5}.
Lower tone-limit = C^1 (256 V. S.).

	R.	C.	$C.^1$	$C.^2$	$C.^3$	$C.^4$
Rinné:		Bc	Bc	Ac	=	Ac
Schwabach:	A.C.	0	5″	12″	8″	5″
	B.C.	21″	8″	25″	8″	7″

Had the test shown reduction of the upper tone-limit, without elevation of the lower tone-limit and increased bone conduction, associated with tinnitus and vertigo, the inference would be quite justifiable that the nerve as well as the conducting apparatus was implicated.

Third, the importance to be attributed to facial paralysis as a symptom of gravity and an urgent indication for immediate operation.

Could it be with certainty determined from any group of symptoms that the paralysis was due to pressure upon the nerve trunk from plastic exudation surrounding the internal

auditory meatus, there would be no hesitation in recognizing the manifestation as an imperative demand for opening the skull, but, unfortunately for differential diagnosis, practically the same line of clinical symptoms will appear whether the lesion occurs in the course of the nerve through the canal of Fallopius, or before its entrance into the temporal bone. Should it be possible simultaneously with complete facial paralysis to demonstrate a similar involvement of the auditory nerve, very forcible contributory evidence would be adduced in support of the diagnosis of pressure at the base, but such a convincing array of symptoms is seldom present. The physiology of the facial nerve in its course after the chorda tympani is given off is thoroughly well understood, and the manifestations of loss of function, even where the impairment is slight, are so pronounced and distressing as to preclude the possibility of the lesion passing unrecognized either by patient or medical attendant; but with the recognition of the distorted visage and the staring eye, the doctor rests content for diagnostic purposes and does not interrogate the patient for symptoms of other muscular disabilities, which a searching inquiry would disclose, but which, to the victim of the infirmity, are, by comparison with his glaring deformity, quite too insignificant to attract attention. With a person of adult age and moderate intelligence it ought to be possible, by painstaking examination, to elicit responses indicating the presence of symptoms which are commonly entirely disregarded, and which depend for their expression upon disordered function in those communicating filaments of the seventh which are given off at the geniculate ganglion to other cranial nerves, whose motor source they thus constitute.

The only muscles, other than those of facial expression and those supplied by the chorda tympani, whose action would be paralyzed by pressure upon the facial nerve in or about the internal auditory meatus, and whose function could be interrogated with some reasonable hope of detecting their disability, are the tensor palati, levator palati, and azygos uvulæ.

The tensor palati derives its motor supply from a fila-

ment of the facial, originating at the geniculate ganglion, communicating with the small superficial petrosal nerve, and thence through the otic ganglion contributed to the muscle.

The levator palati and azygos uvulæ derive their motor supply also from filaments originating in the geniculate ganglion and communicated to the large superficial petrosal nerve, thence through the Vidian contributed to the muscles.

The combined action of this group of muscles in its association with the act of deglutition is not of paramount importance, and the embarrassment attendant upon loss of function would perhaps escape the attention of a not over fastidious patient, but like many another symptom, inquiry concerning the presence of which receives prompt confirmation, the infirmity in the absence of such interrogation by the physician passes unheeded or, at any rate, unmentioned; that a critical inspection of these muscles may, under favorable circumstances, contribute an illumining ray to facilitate the steps of a doubtful diagnosis does not seem an unwarrantable anticipation.

As regards the appearance of facial paralysis in the course of acute suppurative otitis, when mastoiditis is present there can be no diversity of opinion relative to its significance. As a symptom, it constitutes an imperative demand for immediate operation.

In the case just cited, notwithstanding the promptitude displayed in operating, the sigmoid sinus was already invested with lymph over a considerable area and a periphlebitis established, in relieving which condition any delay, even if of but a few hours' duration, would have been most hazardous.

REPORT OF THE MEETING OF THE NEW YORK OTOLOGICAL SOCIETY OF MAY 24, 1898.

By Dr. H. A. ALDERTON, Secretary.

President, Dr. Gorham Bacon, *in the Chair.*

On motion of Dr. McKernon, seconded by Dr. Fridenberg, Dr. Charles H. Burnett, of Philadelphia, was invited to take part in the proceedings of the Society.

Dr. McKernon : **Report of a Case of Bezold's Mastoiditis, with Double Perforation.**

A. W., aged twenty-three, native of the United States, applied at my service at the Infirmary for treatment on April 17, 1898, giving the following history :

Had always been in good health, no diseases of childhood, no ear trouble until four weeks ago, when he had a severe pain in left ear, continuing for three days, when the ear broke and a profuse purulent discharge began. He consulted a physician, who enlarged the opening in the drum membrane, and the discharge had continued steadily since, though less in quantity than at first. The week before he came to the clinic pain commenced again in the left ear, and the discharge increased in quantity. Ten days later he felt pain behind the ear and over the left temporal region.

Upon physical examination, a profuse purulent discharge was seen coming from the external auditory meatus of the left side. The posterior and superior canal walls were collapsed, and a large opening was present in the posterior-inferior quadrant of the drum membrane. The tissues over the mastoid were swollen and boggy, this swelling extending downward in the neck for about three inches below the tip of the mastoid. There was also a swelling in the neck, posterior to the mastoid, extending back-

ward to the occiput. There was marked induration along the border of the sterno-cleido-mastoid muscle, which was exceedingly tender on pressure. His temperature was 100.6° An operation was advised but refused. He, however, consented to remain in the hospital, and an ice-coil was applied, not with any idea of abating the disease, but to make him more comfortable. The next day all the symptoms increased, and he consented to have an operation.

Ether was given, and the usual mastoid incision made, the tissues being very thick over the mastoid. Upon retracting the soft tissues and exposing the bone, the cortex was seen to be white, and looked rather healthy. An opening was made in the antrum, and pus and granulation tissue removed. The whole mastoid area was involved and removed, and communication established with the middle ear through the aditus. A probe was passed downward through the tip into the digastric fossa, and pus welled up in the opening made by the probe. The tip was removed, exposing the digastric fossa and an abscess cavity found burrowing downward into the neck, along the sheath of the jugular and carotid vessels. This abscess cavity was evacuated and curetted. An opening was also found about ¾ of an inch above the tip, and posteriorily, leading into an accumulation of pus, corresponding to the external swelling and œdema in the occipital region. This was removed and the cavity curetted. The sinus was exposed over its centre for more than an inch, and was accidentally opened with the curette and a very free hemorrhage took place, which was controlled by packing gauze against it. Each abscess cavity, as well as the mastoid area, was packed with a separate piece of gauze, the posterior cavity being about four inches in depth.

An uninterrupted recovery followed, the temperature at no time rising above 99.4,° and he was discharged from the ward service eight days from the time he was operated upon.

Points.—Thick mastoid cortex, white color of cortex, and double Bezold perforation.

Discussion.—Dr. KNAPP had a similar case of abscess under the sterno-cleido-mastoid muscle, and extending also under the deep fascia of the neck. After second operation, fever again, and found another deep-seated abscess along and behind the posterior border of the sterno-mastoid muscle down to near the clavicle. The large opening above was supplemented by a

counter-opening at the lower end of the abscess. The cavity was drained and syringed out daily. There was a rapid recovery, which has proved permanent, without any disfigurement or loss of hearing power.

Dr. WILSON spoke of the extreme thickness of the outer table of the mastoid, as a factor in determining the direction of infection. Extreme thickness of the outer table is of course unusual, but happened to be present in Dr. McKernon's case.

Dr. WHITING asked as to the condition of the sinus.

Dr. MCKERNON, in answer to Dr. Whiting's question, the sinus was uncovered below to bend, the dura over sinus was darker than normal in color and was prominent, the sinus was partially covered with granulation tissue which was removed.

Dr. GRUENING thought that a free opening should be made in dissecting cervical abscesses and the cavity packed, rather than make small incisions and depend upon tubes for drainage, as the sinus serves as a field for infection.

Dr. KIPP thought curetting and packing the sinuses sufficed in many cases.

Dr. MCKERNON is in favor of freely opening up the abscesses. Still he has had good results from counter-opening.

Dr. BURNETT, taking advantage of the invitation extended to him to take part in the proceedings of the Society, stated, in regard to perforation of the medial plate of the mastoid process into the digastric fossa, that he had seen a case recently in consultation. Male, aged sixty-two years, had had otitis media for six months and was pyæmic. A counter-opening had been made behind the sterno-cleido-mastoid muscle and a spontaneous opening also existed in the canal. When seen by Burnett a post-pharyngeal abscess was detected in process of formation. The mastoid was opened and found free from disease; abscess from mastoid tip extending towards the pharynx and nucha. These pus cavities were opened up thoroughly, curetted, and packed. Recovered in a month. Hearing much better.

Dr. ALDERTON presented a case of **Cholesteatoma of the Attic and Antrum** in which healing had been brought about, after ineffectual treatment by ossiculectomy, by the use of syringing through his modification of Hartmann's canula. This modification consists in a prolongation of the upright tip in the segment of a circle, about one third of an inch in length, so that when introduced into the attic the opening of the canula points toward

the aditus and lies in its tympanic mouth. The cleansing solution is thus thrown through the aditus into the antrum, washing out this cavity thoroughly. Medicated solutions may also be introduced in the same manner, after cleansing and drying out the antrum.

Dr. Kipp referred briefly to a case in which he had **Accidentally Opened a Semicircular Canal** in an effort to reach the mastoid antrum from the external ear canal. He had performed an operation on the same man ten years previously for intense pain in the mastoid. He found a sclerosed mastoid and did not reach the antrum. Patient recovered. Recently patient returned with great pain in the same region ; found cholesteatoma in the tympanic cavity. Operation: suddenly while chiselling the posterior wall a stream of clear watery fluid issued from the region of the semicircular canal. The operation was discontinued. The clear watery fluid continued to flow for four days uninterruptedly. Facial paralysis was noticed when patient came out of the ether. Pulse fell to fifty a minute after the operation and for some days the temperature was about 104°. The patient suffered greatly from vertigo whenever he raised his head. He gradually improved and four weeks later, the operation was completed by removing lateral wall of antrum and aditus, together with the hammer and anvil. The antrum was found to be rudimentary in size and contained only granulations. The facial paralysis is still present, but otherwise patient is well. The ear was totally deaf before the operation.

Dr. Burnett spoke on the **Etiology of Acute Mastoiditis.** He has never seen a case of acute mastoiditis following acute otitis media in which he has had charge of the treatment from the outset. He thinks it is not a necessary result, but an artificial one. In every case of acute otitis media we have a certain amount of inflammation of the aditus and antrum. He thinks we should not be too anxious to secure a cessation of the discharge.

Between neglect and over-treatment he would take neglect, in acute otitis media.

Discussion.—Dr. Kipp said that in his opinion the treatment of the otitis media could not be held responsible for the development of the mastoiditis in all cases. He had seen several cases of acute purulent inflammation of the middle ear in which the most careful and appropriate treatment, by competent otologists, from the very beginning of the disease did not prevent the develop-

ment of mastoid abscess. In his own practice he had seen mastoiditis develop in many cases in which inflation of the middle ear was purposely omitted, and in cases in which it was practised. He had seen the mastoiditis developed mostly in cases which had received no treatment whatever. Only recently he had operated on a child two years of age, in whom a suppurative inflammation of the middle ear developed during an attack of measles. The ear received no treatment. Three weeks after the appearance of the measles, Dr Kipp saw the child for the first time. He found profuse otorrhœa, large perforation in posterior half of drum membrane, a large fluctuating swelling behind the auricle. Operation same day. The cortex was perforated. The mastoid contained a large pus cavity into which the sigmoid sinus protruded. The child recovered. Dr. Kipp has no doubt that in many cases the mastoiditis commences soon after the development of the inflammation in the tympanic cavity.

Dr. GRUENING reported a case, treated by himself from the beginning, of otitis media with complicating mastoiditis and sinus thrombosis, which resulted in death. He thinks that there are often such cases in which mastoid complications are unavoidable. We distinguish between tip and antrum tenderness. In streptococcus otitis, in spite of the best treatment, we may see the mastoid involved from the beginning.

Dr. FRIDENBERG said that mastoid disease is rare when the aural suppuration is due to simple coryza, more frequent after the exanthemata, and comparatively common after grippe; in other words the virulence of the original affection determines the probability of mastoid implication. In some cases the inflammation seems to attack the mastoid from the start, to the entire or partial exclusion of the middle ear. Hence the best treatment of the middle-ear trouble may not secure immunity to the mastoid. Pus in the mastoid does not always call for an external operation. A fair proportion of cases recover under ordinary treatment.

Dr. BURNETT, in conclusion, believes that there is a natural siphonic action which empties the suppurating antrum.

He related a **Case of Tetanus** in a boy of fifteen without any apparent causation. Had o.m.p.c. Mother had been for a year or two in the habit of syringing the ear with an old rusty syringe, which was probably the cause of the tetanus.

Dr. DENCH: History of a case of **Brain Abscess**; presentation of specimen.

Male, thirty-six years old. Double o.m.p.c. for many years. The patient gave the history of severe left-sided headache, of several weeks' duration. During the past week there had been some delirium. Upon examination, there was no tenderness over the left mastoid, but some tenderness on percussion over the left temporo-sphenoidal lobe. Temperature on admission 102°. Immediate operation by the Stacke-Schwartze method. Mastoid found sclerotic, tympanic vault filled with cholesteatomatous material. Twenty-four hours later, temperature 103⅘°, severe headache, and also the appearance of amnesic aphasia after first operation. Exploratory craniotomy performed at once; the cranial cavity entered just above the external auditory canal; dura exceedingly hyperæmic; dural flap reflected, brain substance explored by aspirating needle, and fluid withdrawn from temporo-sphenoidal lobe. Free incision in temporo-sphenoidal lobe, opening into large abscess cavity, which was thoroughly cleared out by means of the finger. Abscess cavity packed with sterilized gauze, ordinary antiseptic dressings applied to wound. Death four days later.

Autopsy.—Abscess in temporo-sphenoidal lobe, purulent leptomeningitis of left hemisphere, firm thrombus in left lateral sinus, and soft thrombi in torcular and right lateral sinus. The limiting walls of the abscess cavity in the temporo-sphenoidal lobe firm on all sides. (See full report, p. 247 of this number of the ARCHIVES OF OTOLOGY.

Discussion.—Dr. GRUENING has at present time under his care a case of brain abscess in a boy of seventeen years. Operation, cholesteatoma of tympanum and antrum. From a perisinuous abscess about four ounces of fœtid pus escaped. Much improved for nine days, then became again unconscious. Wound dressed and offensive pus evacuated from around sigmoid sinus. Opening made over ear in squama. Exploratory aspiration into temporo-sphenoidal lobe entered into pus cavity. Pus had escaped by spontaneous perforation below. Gauze dressing; on second dressing, ventricular fluid escaped (cerebro-spinal fluid). Is improving. Bacteriology: the proteus vulgaris was found; it seems to be a pathogenic germ and not only a bacterium of putrescence. The characteristic odor is due to it.

Dr. KNAPP thinks there may be large cerebral abscesses with-

out any surrounding zone of softening, that could be operated on with good prospects of preservation of life without conspicuous damage to the functions of the brain. Dr. Dench's case seems to be one of those in which the symptoms of sensory aphasia would be very helpful in localizing the abscess. Cases are on record, for instance one by Manasse in the March (1897) number of the ARCHIVES OF OTOLOGY, in which in an affection of the left ear the patient could see and recognize objects but not name them, though he could easily repeat the word when it was spoken to him. Such cases are now called optical aphasia, and referred to a lesion of the memory centre of visual impressions. The patient, unable to call the object by name if he sees it, can call it when he touches or hears it—that is, when he recognizes it with the help of another sense. Manasse's patient, when a bell was shown him, could not name it; but when it was rung, he instantly said "a bell." An abscess in the temporal lobe was diagnosticated, and by an operation found and permanently cured; also the optical aphasia disappeared. Freund, who first described such cases, refers them to a lesion in the connecting paths between the occipital and temporal lobes. They are cortical in mere optical aphasia, but subcortical, involving the optical radiation, if they show homonymous hemianopsia, as in a case of mine, which also was cured by an operation, but the hemianopsia has persisted. A very instructive paper has recently appeared in the *Lancet*, February 22, 1898 by James Hinshelwood entitled "A Case of 'Word' without 'Letter' Blindness," the cause of which was assumed to be a lesion in the visual word-memory centre situated in the angular and supramarginal gyri on the left side of the brain, and supplied by a branch of the Sylvian artery, supposed to be blocked up. Hinshelwood cites other cases and discusses the subject in a very clear and suggestive way.

Present:—Drs. Charles H. Burnett, of Philadelphia; A. E. Adams, of Newburgh; Gorham Bacon; E. B. Dench; J. E. Sheppard; N. J. Hepburn; W. B. Marple; F. M. Wilson, of Bridgeport; J. F. McKernon; F. Whiting; C. H. May; J. B. Clemens; M. Toeplitz; E. Gruening; J. B. Emerson: H. Knapp; J. L. Adams; C. J. Kipp, of Newark; E. Fridenberg; F. J. Quinlan; T. P. Berens; and H. A. Alderton.

REPORT ON THE PROGRESS IN OTOLOGY FOR THE FOURTH QUARTER OF THE YEAR 1897.

By Dr. A. HARTMANN.

Translated by Dr. Arnold H. Knapp.

ANATOMY OF THE EAR.

280. Czinner, H., and Hammerschlag. Contribution on the embryology of Corti's membrane. Sitzungsbericht der kais. Akademie der Wissenschaften zu Wien. *Math.-naturw. Classe*, vol. cvi., part iii.; also in *Arch. f. Ohrenheilk.*, vol. xliv., No. 1.

281. Held. On the peripheral distribution of the auditory nerve. *Arch. f. Anatomie*, etc., 1897, Nos. 5 and 6.

280. In the cochlea of the 3.6-*cm*-long embryo of the guinea-pig, the membrane of Corti appears as a spiral band, which is broad in the basal convolution and gradually grows smaller toward the apex. It arises from the free edge of the crista spiralis, and originates in the ectodermal cells lining the ductus cochlearis. Two regions may be recognized, the inner next to the epithelium, and the outer, free, separating into fibres, which are the further development of fibres composing the inner region. Later the membrane becomes attached to the reticular membrane by four rows of fibrous bundles. The bundles are the cilia which grow from the auditory cells and lift up Corti's membrane. The membrane is made up of fibres which are stained black with osmic acid.

A large survey of the literature is given, though no mention is made of Baginsky's article on the subject which appeared in the *Arch. f. mikroscop. Anatomie.* Krause.

281. In horizontal sections through the cochlea of the pig-embryo, Held found that the peripheral processes of the ganglion cells of the spiral ganglion show many diverging branches, which

cross many fibres coming from other parts of the ganglion, and partly with these surround the same area of hair-cells. At the same time these processes send off nerve-fibres which in the region of the spiral ganglion pursue a circular course, and are considered by Held to be collaterals of the peripheral processes of the cochlear cells. Thus a greater or smaller number of hair-cells situated at a distant portion of a cochlear turn are connected with a ganglion cell of the spiral ganglion. One and the same nerve-fibre can be irritated by varyingly high tones, which is contrary to the nervous distribution based on Helmholtz's theory of tone perception. The author assumes that a distribution of branching nerve-fibres takes place in the organ of hearing on the principle of various combinations to explain that small differences in tones can be perceived and composite sounds analyzed.

HAENEL.

GENERAL.

a—REPORTS AND GENERAL COMMUNICATIONS.

282. New York Ophthalmic and Aural Institute. *Twenty-eighth Annual Report*, 1897. Drs. Knapp, Toeplitz, and Coburn.

283. New Amsterdam Eye and Ear Hospital. *Ninth Annual Report*, 1897. Drs. Pooley and Myles.

284. GUYE. The acoustic signals of railways and the auditory acuity of laborers.

285. LAUFFS, F., Heilbronn. Clinical reports. *Württ. med. Corr.-Bl.*, No. 44, 1897.

282. Number of new ear patients, 1412; opening of mastoid, 19; ossiculectomy, 3; paracentesis of mem. tympani, 31; removal of polypi and granulations, 53; removal of adenoid vegetations, 147; 1373 new nose and throat patients. GORHAM BACON.

283. Number of new patients, 330: removal of fibrous tumor, 1; paracentesis membrana tympani, 3; polypi removed, 3; mastoid operation, 2. GORHAM BACON.

284. GUYE has tested the four more usual signals on ten moderately deaf laborers, and concludes that the continuous tone series is the best method for testing, but as it usually is inaccessible, testing with whispering voice is sufficient. Hearing of whispering voice in 1 *m* should be required for railway employees, and it should be carefully inquired into that no otorrhœa or interference with nasal respiration is present.

G. ZIMMERMANN.

285. LAUFFS reports a number of unusual cases. Four cases of rhinoliths; one case of adhesion between the septum and the lower and middle turbinates on one side caused by inexperienced galvano-cauterization; one case of spasm in the lip and cheek branches of the r. facial nerve cured by treatment of the nose: one case of two symmetrical congenital perforations in both ant. palatal pillars; removal of a piece of egg-shell imbedded in the larynx; and finally a case of aural polyp of the size of a pigeon's egg which protruded from the auricle. E. MÜLLER.

b.—GENERAL PATHOLOGY AND SYMPTOMATOLOGY.

286. PONFICK, E., Breslau. On the general pathology of middle-ear disease in early childhood. *Berliner klin. Wochenschr.*, Nos. 38–41, 1897.

287. ETIÉVANT. On monauricular diplacousis. *Ann. des malad. de l'otol.*, etc., No. 11, 1897.

288. GRADENIGO. On a form of physiological diplacousis in Rinne's test. *Ibid.*, No. 12, 1897.

286. Among 100 post-mortem examinations, at the Breslau Children's Clinic, of children, the majority under one year and the remainder not over four years, only 9 cases were found where the middle ear was normal; in 13 the otitis was single, in 78 the otitis was double. The cause of death was cardiac lesion, dermatitis diphtheria, pneumonia, gastro-enteritis, tuberculosis, etc. Indefinite local symptoms were present in 10 cases, together with more or less well-marked general symptoms. The autopsies showed, aside from moderate splenic tumors, that the middle ear alone was the seat of marked changes and exudative inflammation. These cases show that otitis media may occur as an independent infectious disease, and may cause death. PONFICK observed the clinical course of this form of otitis without fatal issue on his own children. In the first year, or the first half of the second year, an apparently primary enteritis sets in, without known cause, until a fresh otitis appears, which seems to be the primary lesion, as after the establishment of the discharge the intestinal symptoms cease abruptly. In these cases the staphylococcus albus and aureus are frequently found. In one of the cases the bacterium was even found in the blood. The exudate was usually purulent, rarely mucous, sero-fibrinous, or hemorrhagic; it frequently contained cholesterin. In only five per cent. of diseased middle ears, did perforation take place. When toxic

products are absorbed, general infection occurs with swelling of the spleen, degeneration in liver and kidneys, and especially intestinal symptoms. MÜLLER.

287. ETIÉVANT has published two additional cases of that rare affection, one-sided diplacousis. The two patients were women, and were completely deaf on one side. The one heard for two months the various voices in the deeper scale when a single person conversed with her; the other was especially annoyed in hearing singing, instead of one tone she would hear three or four in varying pitch, and when a number of persons sang she heard an inharmonious mixture. In both cases prolonged treatment with catheterization was beneficial. Etiévant is inclined to consider the affection to be due to disturbances in the transmission of tones rather than a lesion of certain nerve-fibres in the labyrinth. A single air insufflation sufficed in many cases to cure the complaint. ZIMMERMANN.

288. GRADENIGO has observed with his clamped tuning-forks in the lower octaves that they permit the perception of the fundamental tone by air-conduction, but that the first over-tone is alone heard when they are placed on the bone; this is not the case in the higher octaves. He also observed that when the fork C with 64 vibrations was placed on the mastoid process and the next higher c-fork was held before that ear or the one on the opposite side, the c with 128 vibrations only is heard, and that as soon as the tuning-fork heard by air-conduction was removed did the fork on the mastoid emit its fundamental tone of 64 vibrations. The latter phenomenon, according to Gradenigo, may be regarded as an example of exhaustion, but the former must be physiological, which enters into account in many pathological cases, especially in the forms of diplacousis.

ZIMMERMANN.

c.—METHODS OF EXAMINATION AND TREATMENT.

289. LUZATTI. On bone-perception of the watch in the diagnosis of aural affections. *Ann. des mal. de l'or., du lar.*, No. 10, 1897.

290. PANSE. An objective tone-measure. *Arch. f. Ohrenheilk.*, vol. xliii., p. 251.

291. DENNERT, H. On the examination of hearing with tuning-forks. *Arch. f. Ohrenheilk.*, vol. xliii., p. 276.

292. BIEHL, C. The recognition of one-sided and double-sided deafness. *Arch. f. Ohrenheilk.*, vol. xliii., p. 256.

293. LAVRAND. On air-insufflation through the Eustachian tube, a modification of Politzer's method. *Rev. hebdom. de lar., d'otol.*, No. 49, 1897.

294. BREITUNG, M., Coburg Pneumatic massage of the drum-membrane with the aid of an electro-motor air-pump in the treatment of progressive deafness. *Deutsche Medicinal-Zeitung*, No. 77, 1897.

289. LUZATTI passes in review the usual methods for testing the hearing, and recommends his own method, which consists of the comparison of the bone-conduction of a watch placed on the tragus and then on the mastoid process. Normally the watch is heard better on the tragus; if the reverse is present, an affection of the sound-conducting apparatus is probable; if the perception at the tragus is diminished and absent over the mastoid, a disturbance in the sound-perceiving apparatus is indicated. The author thinks that this method is especially of value in low degrees of deafness. ZIMMERMANN.

290. This is a series of experiments with tuning-forks to determine an objective tone-measure from the amplitude of vibration, which should be read in the original article.

BLOCH.

291. DENNERT pursues the following course to test the relative hearing power of tones of varying pitch with the aid of tuning-forks. Two resounding forks of a different pitch are allowed to exhaust themselves intermittently before a normal ear until they are no longer perceived in this manner. If at that moment they are placed before the ear, both will again be heard (period of rest) and at equal distances. This holds true in cases where the hearing is uniformly decreased for these various forks. If the hearing is not uniformly decreased, a healthy ear will likewise hear the various forks at various distances. The difference of distance is a measure for the relative hearing. Dennert tests bone-conduction in a similar manner. His method is practically a combination of the Rinne and the Schwabach test.

BLOCH.

292. To discover simulated one-sided deafness, BIEHL introduces a piece of rubber tubing (previously advocated by Voltolini) in the sound ear. If the patient does not repeat when the tube is patent, simulation exists. In bilateral hardness of hearing

or total deafness the possibility of a traumatic neurosis should be thought of. BLOCH.

293. The patient is to blow out his cheeks, while no air escapes by mouth or nose. LAVRAND thinks that thereby many inconveniences in the swallowing of water and phonation are avoided. ZIMMERMANN.

294. BREITUNG has devised this apparatus to shorten the intervals between the movements of the pendulum. The air-pump is connected with an electro-motor, and the amplitude and rapidity of the movements can be easily regulated. H.

d.—DEAF-MUTISM.

295. HEIDSICK, J., Instructor of Deaf-Mutes, Breslau. Deaf-mutes with hearing power. A contribution to the methods of instruction. Breslau, 1897.

295. In the first part of the monograph HEIDSICK criticises the hearing exercises for deaf-mutes. The results obtained are not due to the improvement of the hearing but to the influence on the remnants of hearing by the systematic drill in articulation and speech. The author wants to exclude the excessively deaf children, the improperly-called deaf-mutes, from the totally deaf children during the instruction. The former should be instructed with the aid of suitable hearing instruments by teachers with strong voices.

In the second part Heidsick opposes the tendency to instruct deaf-mutes only with articulate speech and to forbid gesticulation. He agrees entirely with the opinion recently expressed at a deaf-mute convention (Hannover) in favor of the combined system of instruction, the combination of articulate and gesticulate speech. The teacher should employ the gesture speech during the instruction, and the deaf-mutes should be permitted to use gestures among themselves. H.

EXTERNAL EAR.

296. GRUBER, Prof. JOSEPH. Cystomata of the ear. *New York Polyclinic*, Nov. 15, 1897.

297. BURNETT, CHAS. H. Foreign body in the ear. *Philadelphia Polyclinic*, Dec. 11, 1897.

298. HACKLEMAN, F. G. Foreign bodies in the external auditory canal, with report of a case. *Laryngoscope*, Dec., 1897.

299. MILLER, G. VICTOR. A foreign body (tooth) in the ear requiring reflection of the auricle, etc., for its removal. *British Med. Jour.*, Sept. 25, 1897.

300. LEUTERT, E. Periauricular abscess in furuncles of the auditory canal. *Arch. f. Ohrenheilk.*, vol. xliii., p. 267.

301. BIEHL, C. Idiopathic perichondritis of the auricle and the spontaneous othæmatoma. *Arch. f. Ohrenheilk.*, vol. xliii., p. 245.

302. SCHWIDOP. A case of burns of the auditory canal and the drum-membrane. *Arch. f. Ohrenheilk.*, vol. xliii., p. 241.

303. BAR. On otomycosis. *Ann. des mal. de l'or., du lar.*, No. 12, 1897.

296. According to GRUBER, cystomata are generally benign in character and emanate as a rule from the parotid gland or the mastoid portion of the temporal bone. The cystic growths are usually atheromata, and in most instances develop primarily on the pinna or in the ext. auditory canal. Cysts with serous contents are very rare; they are found on the auricle, seldom in the auditory canal and cartilaginous Eustachian tube. Gruber gives the history of a single case of cyst of the ext. audit. canal which he has observed and a cyst in the neighborhood of the Eustachian tube which encroached upon the latter, thereby causing deafness and buzzing in the ear. The first patient was cured by operation; the second died of tuberculosis, and no operation was performed. GORHAM BACON.

297. BURNETT reports a case of foreign body (cherry-stone) resting against the drum-membrane in a child's ear. It was removed by syringing. He draws attention to the dangers of unskilful attempts at removing foreign bodies, especially the use of instruments, and says, "Use the syringe, or let the foreign substance in the ear alone." GORHAM BACON.

298. The case reported was that of a boy, aged twelve, who had suffered from deafness since he was three years of age. Three beans were removed from each ear. The hearing was almost restored to normal. GORHAM BACON.

299. A boy of ten years complained of feeling something hard in his ear. Syringing and ordinary means failed to extract it. On detaching the auricle and chiselling slightly the post. meatal wall, an upper incisor tooth with a broken fang having a sharp edge was removed. On examination later, a slit-like perforation was seen at the upper and back part of the membrane. The

boy denied having put the tooth in the ear, but stated that three weeks previously he had pulled out a tooth in the night.

ARTHUR CHEATLE.

300. The previous history pointed to a furuncle. The mastoid region was swollen, temperature of 40°, and disease of the sinus was thought of. All symptoms, however disappeared in a few days. In another case an abscess appears in the region of the right tonsil. From the condition of the ear a mastoid empyema was suspected, and the operation was made. The diagnosis may often be difficult to make. The position of the abscess, the tenderness of the ear canal, the persistent fever, and evacuation of necrotic masses spoke for a furuncle. BLOCH.

301. Two cases in soldiers, occurring without trauma. In the perichondritis with serous exudate, suppuration began after incision. Both healed without disfigurement. BLOCH.

303. BAR gives a full description of our present knowledge of otomycosis, and two personal observations. Attempts at inoculating two doves with aspergillus were unsuccessful. The author accepts the general opinion that a particular inflammatory condition in the ear-canal must precede, to permit a soil for the moulds. The treatment should consist in the removal of the mould-scales, irrigation with a solution of chloride of lime, and subsequent instillation of salicylic acid alcohol. In obstinate cases the canal should be swabbed with silver nitrate, ten per cent. solution.

ZIMMERMANN.

MIDDLE EAR.

a.—ACUTE OTITIS.

304. GRUBER, Prof. J., Vienna. Paracentesis of the drum-membrane. *Wien. klin. Rundschau*, No. 4, 1897.

305. MÜLLER, R. A case of acute tubercular otitis media during treatment with "new-tuberculin" (T. R.). *Deutsche med. Wochenschr.*, No. 34, 1897.

306. LATRILLE. Acute suppurative otitis media during broncho-pneumonia. *Rev. hebdom.*, No. 48, 1897.

307. STEIN, V. S., Copenhagen. A case of Bezold's mastoiditis cured during an attack of erysipelas with functional examination. *Monatschr. f. Ohrenheilk.*, No. 11, 1897.

308. PERROT. On Bezold's mastoiditis. Bordeaux, 1897.

304. For two years GRUBER has operated for collection of

exudate in the middle ear in the following manner. The incision begins at the upper and posterior quadrant of the drum-membrane and is carried around the posterior convexity 1 to 1½ *mm* from the margin, and terminates in front of the lower and posterior quadrant. The membrana is thus incised for some distance, the wound edges gape, and the exudate escapes easily.

POLLAK.

305. A patient with pulmonary consumption was undergoing treatment with new-tuberculin at the Charité Hospital. An offensive left-sided otorrhœa had existed for a number of years. After treatment for several weeks with the new-tuberculin the condition of the affected ear had not changed, and the right ear suddenly began to discharge. Tubercle bacilli could be found in the pus from both ears. Several small spots appeared on the drum-membrane which were regarded as miliary nodules, only one of which, however, broke down and caused a perforation. It seems likely that the treatment with the new-tuberculin caused the sound ear to become affected, or that the infection took place through the Eustachian canal in coughing.

NOLTENIUS.

306. A child, four years old, who had been ill with broncho-pneumonia for three months, developed an otitis a week ago. The discharge contained tubercle bacilli. According to the author, the infection took place through the Eustachian tube by the sputum. ZIMMERMANN.

307. The diagnosis of the mastoid complication during the acute otitis was made from the tenderness over the tip of the mastoid and a swelling beneath the origin of the sterno-mastoid muscle. After the erysipelas, these symptoms and the otorrhœa ceased. G. KILLIAN.

308. This article reproduces most of the hitherto published cases and a new case from Lichtwitz's practice. The operation lasted three hours; the tip of the mastoid was removed and the digastric fossa was tamponed. Healing after two months.

ZIMMERMANN.

b.—CHRONIC PURULENT OTITIS.

309. BURNETT, C. H. Intra-tympanic surgery, especially in chronic purulent otitis media. *International Medical Magazine*, Dec., 1897.

310. FENTON, HICKS C. Excision of membrana tympani and extraction of the malleus and incus for the cure of chronic puru-

lent inflammation of the middle ear. *Medical Sentinel*, Sept., 1897.

311. BRONNER, ADOLPH. A case of cholesteatoma of the attic of twenty years' duration simulating disease of the mastoid process. *Lancet*, Oct. 23, 1897.

312. LUCAE. The conservative and operative treatment of chronic purulent otitis. *Therapeutische Monatshefte*, No. 8, 1897.

313. WINCKLER, E., Bremen. The after-treatment of the middle-ear spaces after their exposure. *München. med. Wochenschr.*, No. 48, 1897.

314. KUHN, Strassburg. Cholesteatoma of the ear. Drasche's *Bibliothek der medic. Wissenschaften.* Teschen, 1897.

315. PANSE, R., Dresden. Cholesteatoma of the ear. *Klinische Vorträge aus dem Gebiete der Otologie und Pharyngo. Rhinologie*, vol. ii., No. 4. Jena, 1897.

309. In this paper BURNETT gives brief notes of thirty operations for the relief of chronic purulency of the middle ear. These cases remained under observation long enough for the writer to draw the following conclusions as a result of removal of necrotic ossicles:

1. Prompt lessening of the discharge in all cases.

2. Ultimate cessation of the discharge and cicatrization of the fundus in nearly one half of the cases, as observed so far.

3. Arrest of the advance of caries and necrosis in the drum cavity, aditus, antrum, and mastoid cells, thus lessening the liability of the occurrence of intracranial lesions of otitic origin.

4. Improvement in hearing in more than half the cases.

5. Marked amelioration in the general health, especially in those cases presenting symptoms of slight septicæmia from the chronic purulency. GORHAM BACON.

310. FENTON reports a case in which he removed the drumhead, malleus, and incus, which was followed by a cure of the discharge, relief from vertigo and tinnitus, and improvement in the hearing and general health. GORHAM BACON.

311. BRONNER'S patient, a man, aged thirty-one years, having had discharge from the right ear for twenty years, developed an abscess behind the auricle. On opening the abscess and exposing the bone no fistula was present, but on opening the antrum the attic was found distended to the size of a cherry by a cholesteatomatous mass. CHEATLE.

312. LUCAE believes that operative exposure of the middle-ear

spaces is at present too frequently performed from a prophylactic or purely therapeutic point of view, and thinks that the time has come when a halt must be called on this operative tendency. The author fails to prove his grave accusation. In the article, which is addressed to general practitioners, he proceeds to enumerate the symptoms which call for operative interference, and states the success which he claims to have had by the conservative treatment. The large number of operations which have been performed on chronic cases in Lucae's clinic does not accord with his plea against the operative fervor. KÖRNER.

313. WINCKLER employs almost all of the known methods of after-treatment either alone or in combination. SCHEIBE.

314. KUHN gives a short and complete description of the cholesteatoma of the ear, with illustrations of microscopical and macroscopical specimens.

315. PANSE gives a similar general description of the cholesteatoma.

c.—COMPLICATIONS OF PURULENT OTITIS.

316. GREEN, J. ORNE. Three cases of extradural abscesses; operations and recoveries. *Boston Med. and Surg. Jour.*, Nov. 25, 1897.

317. MILBURY, FRANK S. A case of otitic brain abscess [epidural] (from chronic otorrhœa); optic neuritis; opening of the mastoid and skull; recovery. *Laryngoscope*, Dec., 1897.

318. CULBERTSON, L. R. Report of a case of bilateral and another of monolateral mastoid disease; recovery of both. *Cincinnati Lancet-Clinic*, Oct. 23, 1897.

319. BARCK, C. Two cases of opening of the lateral sinus for infective thrombus, with a table of operations performed previous to 1897. *Annals of Otol. and Rhinol.*, Nov., 1897.

320. OPPENHEIM, Prof. H. The insuccesses in cerebral surgery due to errors in diagnosis. *Berl. klin. Wochenschrift.*, Nos. 49 and 50, 1897.

321. GRUNERT, C. Extradural otogenous abscesses and suppurations. *Arch. f. Ohrenheilk.*, vol. xliii., p. 81.

322. GRUNERT. Anatomical and clinical contributions to the study of intracranial complications to otitis. *Münch. med. Wochenschr.*, Nos. 49 and 50, 1897.

323. On the value of lumbar puncture for the diagnosis of intracranial complications to ear disease. Supplement to LEUTERT'S article. (See review in these ARCHIVES, vol. xxvi., p. 434.)

324. MOURE. Three cases of intracranial complication in ear disease. *Rev. hebdom. de lar., d'ot.*, No. 43, 1897.

325. STEINBRÜGGE, Prof. A case of otitic brain-abscess. *Deutsche medic. Wochenschr.*, No. 41, 1897.

326. KALMUS, E., Prag. An otitic brain-abscess in the right temporal lobe. *Prag. med. Wochenschr.*, Nos. 51 and 52, 1897.

327. WOLFF, F. On otitic brain-abscess. *Inaug. Dissert.*, Strassburg, 1897.

328. LERMOYEZ. A symptom of thrombosis of the sup. longit. sinus. *Ann. des mal. de l'or., du lar.*, No. 12, 1897.

316. GREEN reports three cases of extradural abscess, the first one being a case of fracture of the skull, with infection and extradural abscess. The patient, a strong and healthy man, twenty-seven years of age, in jumping from an electric car, received a scalp wound over the left parietal bone, and was unconscious for a short time. There was bleeding from the left meatus, followed by a serous discharge. There were two fractures of the temporal bone. Pus was evacuated from the middle cranial fossa.

The second case was that of a man, forty years of age, who had an acute otitis media. A paracentesis was performed a number of times. Finally it became necessary to open the antrum, when the tympanic roof was found carious with a collection of pus in the middle cranial fossa.

In the third case, there was caries of the antrum roof and an extradural abscess.

All three cases were operated upon, and all recovered.

GORHAM BACON.

317. The author reports a case of chronic otorrhœa (left) of many years' standing as a result of scarlet fever. The mastoid cells were involved. Operation performed and mastoid antrum opened. Cells filled with pus and lateral sinus exposed. An opening was formed into the middle cranial fossa, and considerable pus was evacuated. The patient, before the operation, suffered from severe headache, slight paralysis of left side of face and right arm and leg; also amnesic aphasia and optic neuritis (left eye). The patient recovered. Hearing very much impaired. GORHAM BACON.

318. The first case reported by CULBERTSON was that of a young lady, aged seventeen, in whom it was necessary to open the mastoid cells as a result of acute suppurative otitis media

(right side). The cells were found filled with pus. About three weeks later, the left mastoid process was affected. The patient recovered. Hearing normal on the right side; complete deafness on the left.

The second case was a boy, seven years of age, who had mastoid disease resulting from acute sup. otitis media. Several operations were performed on the mastoid cells, as necrosed tissue was found. Recovery followed. GORHAM BACON.

319. BARCK gives a table of cases of sinus thrombosis reported previous to 1897, of which there were one hundred and twenty-four, with eighty-three recoveries. He gives the histories of two cases of his own, as follows:

CASE 1. Patient, twenty-six years old, had left-sided otorrhœa of many years' standing. Ext. auditory canal filled with foul-smelling pus and granulations. Some tenderness over mastoid. A Stacke operation was first performed. The patient later had chills and high temperature. The sinus was opened and a thrombus evacuated. The flow of blood was established in the upper end but not in the lower one. Later, the int. jugular was ligated, but no thrombi were found. Patient died of septicæmia. At the autopsy, the cause of the blood poisoning was found to be a large abscess under the deep fascia of the neck, below the splenius capitis and levator scapulæ in the post-cervical triangle. Direct communication could be traced between the abscess, the lateral sinus, and the mastoid cavity.

CASE 2. Patient, male, twenty-six years of age, fell from a wagon and became unconscious for three days. He had hemorrhage from the right ear, and complained of dizziness. Later he had a chill, followed by a temperature of 106° F. There was a fœtid discharge from the ear. Under ether, a fracture line in the squamous portion of the temporal bone was visible after detachment of the periosteum. An abscess was found in the line of fracture below the outer lamella of bone. The antrum was free. Lateral sinus was found filled with a thrombus, which was softened and covered with pus. The patient recovered.

GORHAM BACON.

320. OPPENHEIM discusses the diagnosis between brain-tumor and serous meningitis which cannot be entirely cleared up by lumbar puncture. He fears lest the latter procedure become a dangerous experiment in the hands of those lacking in knowledge and experience. The confounding of brain-tumor and brain-

abscess is possible in the combination of tumor and a purulent otitis. In a similar case Oppenheim, notwithstanding the presence of aphasia characteristic for an otitic abscess of the left temporal lobe, was able to make diagnosis of brain-tumor from the condition of the pulse, the temperature, and the absence of any changes in the middle-ear spaces at operation; the diagnosis was subsequently verified at autopsy. The author recognizes the importance of lumbar puncture in the diagnosis of uncomplicated brain-abscess. Leutert goes so far as to conclude that a purulent cerebro-spinal meningitis does not exist in case the bacteriological examination of the puncture-fluid proves negative.

MÜLLER.

321. This is a monograph on extradural abscess based on twenty clear cases. Twelve of these followed acute inflammations; in the chronic forms cholesteatoma usually was present. The abscess is frequently situated in the posterior fossa. In acute cases the dura may be red, or covered with granulations, with fibrinous deposits, or with an abscess-membrane; it may even be unchanged. In chronic cases the dura may be in a sloughing condition. The symptoms are not characteristic; fever, pain, vertigo, may be absent, likewise changes in the eyes and the pulse. The local conditions in the ear are not striking, nor copious otorrhœa. We must always suspect an extradural abscess when an acute purulent otitis, in spite of appropriate remedy, persists for a long time, and gastric symptoms are present. The diagnosis is only assured at the operation if channels are found leading to the dura—fistulous tracts. These tracts are often not found. The treatment is only operative.

Extra-dural suppurations differ from the extra-dural abscess where the dura itself forms a part of the wall of the otitic pus cavity. The bone leading from the diseased middle ear is carious. Granulations spring up on the dura, and it becomes changed as in abscess. The posterior cranial fossa is the most frequent site. BLOCH.

322. A. *Three cases of so-called deep otitic extradural abscess.* CASE 1 has been published in *Arch. f. Ohrenheilk.*, vol. xliii. CASE 2. Acute otitis media. The abscess was likewise situated on the anterior surface of the pyramid near the apex, and death ensued from meningitis. Near the abscess in the tip of the petrous bone there was an ostitic focus. Carotid canal and labyrinth were free from infection. CASE 3. Chronic purulent

otitis. Vertigo, facial paresis, later paralysis, deafness, and polypi. The radical operation disclosed necrosis of the labyrinthine wall and an extrasinuous pus collection. Double optic neuritis. On the twenty-fifth day after the operation the temperature was 39.3°. Exuberant granulations in the middle ear and aditus. Two weeks later two sinuses in the labyrinth appeared and discharged freely. A second operation was undertaken, the labyrinth was opened and the sequestra removed. The probe at this point opened out an extradural abscess on the anterior petrous surface. Recovery. In this case, the unusual quantity of the discharge from the labyrinthine fistula had suggested the probabilities of an abscess. The author in conclusion speaks of the diagnosis of these deep-seated extra-abscesses and the uncertainty in the absence of fistulous tract.

B. *Three cases of healed otitic sinus-phlebitis. Operation on the sinus. Ligature of the int. jugular.*

In the first two cases the diagnosis of sinus-phlebitis was made according to Leutert. (See review in these ARCHIVES, vol. xxvi., p. 124.) In these cases where, according to Leutert, sinus-phlebitis is probable, and the sinus appears externally healthy, it is advised to incise the sinus after ligature of the jugular vein and to tampon especially down to the bulb and upwards to the junction with the sup. petrosal sinus. The circulation through this area is thus obliterated. Both cases recovered, though high fever persisted for some time after the operation. Of course it cannot be stated positively that this method of treatment was the cause of the recovery. In a third and fourth fatal case, the diagnosis was confirmed at the operation. The method employed was the same, except that in the fourth case the unusually long common facial vein was ligated in place of the jugular. SCHEIBE.

323. In two cases meningitis could be excluded; in a third it was diagnosticated. In the fourth case death ensued, possibly from the puncture or the narcosis. The autopsy showed, aside from anæmia and œdema of the brain, no intracranial lesion. A more extensive employment of lumbar puncture is hampered by the uncertainty whether the procedure is without danger or not. SCHEIBE.

324. CASE I. A boy, four years old, relapsing otitis with severe meningeal symptoms and swelling over the mastoid. The periosteal abscess was incised and carious bone found. The

operation nevertheless was not continued until one week later when the general condition was aggravated. The entire mastoid was filled with pus and granulations to the sinus. Recovery.

CASE 2. Headache, delirium, fever, right optic neuritis, suppuration, and carious bone in the right ear, tenderness over mastoid, and an abscess in front of the ear. At the operation a fistulous tract was found leading to an extradural abscess in the middle fossa. The dura did not pulsate; a puncture with a knife to a depth of 1½ *cm* gave no result. The autopsy showed a large abscess a *cm* still deeper, and a right-sided thrombosis.

CASE 3. A boy, two and a half years old, otitis after measles. The otorrhœa ceased and high fever and chills set in. Paracentesis and a simple mastoidectomy had no effect on the fever; the diagnosis of sinous thrombosis was then made, and verified at the operation. Death from sepsis. ZIMMERMANN.

325. A soldier, who had always suffered with otorrhœa, complained of one-sided headache for a number of years. At the time of the first attack of vomiting a moderate drooping of the left upper eyelid was noticed. The left mastoid is very tender and swollen, percussion on that side of the head is not tender; temperature normal, no slowing of pulse. The patient is slightly stuporous and incoherent, though no motor or optic aphasia. At operation the antrum was found to contain pus and granulations; no communication with the cranial cavity could be found and the search for the presumable abscess was postponed. On that night temperature and pulse rose rapidly, and death followed with the signs of pulmonary œdema. No autopsy, but the presence of the abscess was confirmed. The author believes that the perforation of the abscess was hastened by the concussion during the mastoid operation. He calls attention to the ptosis as an important symptom of abscess in the temporal lobe, and considers it to be due to pressure on the trunk of the third nerve.

NOLTENIUS.

326. The diagnosis was made from the following symptoms: right-sided suppurative otitis; left-sided facial and hypoglossal paralysis; weakness of the left upper extremity with occasional convulsive attempts at pronation and supination; paresis of the left leg; left-sided lateral homonymous hemianopia; conjugate deviation of the eyes and of the head to the right. The operation was not permitted, and the autopsy confirmed the diagnosis.

POLLAK.

327. The author gives an exhaustive review of the symptoms of brain-abscess from ear origin based on nine cases observed at Kuhn's clinic. H.

328. The peculiarity of this case was a pronounced congestion of the collateral veins in the scalp. A case where long-standing ear trouble had led to an extradural abscess and a sinus-thrombosis. Both lesions were exposed at the operation; death, however, ensued from purulent meningitis. In addition, the autopsy showed that the thrombus in the transverse sinus extended into the longitudinal sinus, causing, according to LERMOYEZ, the distension of the cutaneous veins. ZIMMERMANN.

OTHER MIDDLE-EAR AFFECTIONS.

329. BARR, THOMAS, and NICOLL, J. H. A case of malignant tumor of the brain originating in the middle ear. *British Med. Jour.*, Oct. 16, 1897.

330. SMITH, S. MACCUEN. Chronic non-suppurative otitis media. *Atlanta Med. and Surg. Jour.*, Dec., 1897.

331. GUYE. Deafness following cicatrization of the membrana tympani. *Rev. intern. de rhin., ot., et lar.*, iii., 1897.

332. EITELBERG, A., Vienna. Remarks on the symptoms and treatment of middle ear-catarrh. *Wien. med. Presse*, No. 50, 1897.

333. GRUNERT. A new operative procedure to prevent adhesion of malleus to the labyrinthine wall after synechotomy and tenotomy. *Arch. f. Ohrenheilk.*, vol. xliii., p. 135.

334. GARNAULT, P. Surgical treatment of aural catarrh and tinnitus. Paris. A. Maloine, 1897.

329. BARR and NICOLL give a full report with illustrations of a very interesting case of malignant disease, in all probability sarcomatous, originating in the right middle ear of a boy, aged twelve and a half years. Pain and slight discharge had been present for three months before he was seen by Barr, who discovered a firm, very sensitive, and freely bleeding polypus filling the meatus. Removal was thoroughly effected, but the growth returned in four months, when it was again removed through the meatus. As recurrence took place, the antrum was opened and cleared of growth; soon after this grave symptoms arose which pointed to an abscess in the temporo-sphenoidal lobe. On Nicoll exploring the head, a hardish mass was felt under the

cortex, on dividing which a firm, grayish mass was exposed. The groove for the lateral sinus was also found occupied by firm, grayish granulation-like tissue. Death occurred two and a half months later. At the post-mortem examination the growth was found to be attached chiefly to the floor of the middle fossa, and to consist of two portions, one external to the skull being extension through the operation openings above and behind the ear of the main growth within the cranium; the other, or main mass, situated within the skull, appeared to be closely attached to the upper surface of the dura mater, which seemed almost intact, and was no doubt an extension from the middle ear; the clinical history showing that the extension of the growth upwards into the middle fossa was probably a much later event and followed also by more rapid progress. Barr quotes Bürkner's statistics, which indicate that carcinoma of the ear occurs only in the proportion of one in three thousand cases of ear disease; with regard to sarcoma, the proportion is still less. Barr also notes that in recorded cases of sarcoma, a polypoid-looking growth in the external meatus was observed in most of them when first brought under notice. CHEATLE.

330. Besides attention to the nose and naso-pharynx, SMITH advises that in chronic non-suppurative otitis media, incisions should be made in the membrana tympani extending along its whole length. Liquid albolene or the camphor-menthol solution can then be injected into the middle ear. All adhesions should be divided with a knife and traction made on the handle of the malleus. Subsequently massage of the drumhead and ossicles should be performed with Siegle's pneumatic speculum. Pilocarpine is given in some cases, while in others nerve tonics are administered. The author believes that excision of any part of the conducting apparatus is only justifiable when relief from severe tinnitus and vertigo is the object of treatment and other measures have failed. GORHAM BACON.

331. GUYE thinks it more favorable for an otitis to heal with permanent perforation, because otherwise each attack of naso-pharyngitis would cause fresh disturbance in the ear. In a lady who had had an otitis after scarlet fever six years ago, with dry perforation in both ears, whispering voice was heard in 9 *m*.

Should the drum-membrane cicatrize, with disturbance in hearing, permeability of the Eustachian tube must be examined for. A patient with dry perforation heard whispering in 9 *m;*

the perforation healed, and the hearing was reduced to 0.20 *m*. On passing sounds in the Eustachian tube, a closure near the tympanal opening, presumably caused by cauterization with silver-nitrate, was opened, and the old hearing power was regained. ZIMMERMANN.

332. According to EITELBERG, the usual methods of treating aural catarrh—catheter, Politzer's method, and rarefaction—are of equal value, but their action in the various cases is not the same. POLLAK.

333. The manubrium mallei is pushed outward by a bent probe introduced from in front. The wound of the drum-membrane then closes behind the handle, and the latter remains outside of the middle ear. Three cases of partially favorable functional result. BLOCH.

334. GARNAULT describes his method of retro-auricular operation in sclerosing processes. He believes that even in strongly ankylosed stapes, a considerable degree of hearing may be obtained. H.

INTERNAL EAR.

335. WILLIAMS, J. H. A clinical record of two cases of Ménière's disease, with remarks thereon. *Charlotte Med. Jour.*, Dec., 1897.

336. HUTCHINSON, J. Deafness from inherited syphilis. *Archives of Surgery*, July, 1897.

337. ALT, F., Vienna. The etiology of diseases of sound-perceiving apparatus. *Wien. klin. Rundschau*, No. 40, 1897.

335. CASE 1. Patient, fifty years of age, was struck by a branch of a tree while riding, and a twig penetrated the right membrana tympani. The accident was followed by persistent nausea and loss of perception of the direction of sound. The handle of the malleus was pushed upward and inward. Traction on the handle of the malleus gave great relief from the vertigo. The hearing was much affected.

CASE 2. Patient, twenty-eight, a carpenter, was struck by a nail which flew from under the hammer of a fellow-workman. The end of the nail lacerated the canal and caused a rupture of the drumhead. This was immediately followed by nausea, vomiting, and intense vertigo. When standing erect, the patient would have an inclination to fall toward the affected side. Phe-

nacetine was given to both patients, as it gave great relief from the nausea and vomiting. GORHAM BACON.

336. HUTCHINSON and LAIDLAW PURVIS agree that of those who suffer from congenital syphilitic deafness two thirds are females. The former states: "It is difficult not to suspect that some unrecognized law as regards hereditary transmission underlies these remarkable facts." On looking over the notes of 541 aural patients at King's College Hospital I find that 11 suffered with this form of deafness; 9 were females, and 2 males.

CHEATLE.

337. Among 182,779 ear cases ALT found that the internal ear was affected in 5.42 per cent. The ratio of the sexes was 70 men to 30 women. Alt found the following etiological factors in 42,736 patients of Gruber's clinic. Unknown cause, 30 %; professional cause, 14.8 %; combined with non-suppurative middle-ear processes, 8.9 %; meningitis, 7.2 %; congenital, 6.89 %; acquired syphilis, 5.4 %; typhoid fever, 4.8 %; purulent otitis, 4.4 %; hereditary syphilis, 3.1 %; cretinism and hydrocephalus, 2.4 %; scarlet fever and trauma, 2.6 % each; diphtheria, 1.7 %; mumps combined with retino-choroiditis, 1.03 %; with retinitis pigmentosa, 0.58 %; alcohol, quinine, salicylic acid, nephritis, small-pox, erysipelas, multiple sclerosis, fracture of base of skull, lightning, each 0.34 %. POLLAK.

NOSE AND NASO-PHARYNX.

a.—ANATOMY OF THE NOSE.

338. GOERKE, M. The glands in the nasal mucous membrane. *Arch. f. mikroscop. Anatomie*, vol. l., No. 4.

339. BRÜHL, G. New method to show the cavities in the nose and ear. Preliminary communication. *Anatom. Anzeiger.*, vol. xiv., No. 9.

340. ONODI, Prof. A., Budapest. A rare anomaly. *Monatschr. f. Ohrenheilk.*, No. 12, 1897.

338. GOERKE examined the respiratory mucous membrane in the dog, and found that mucous glands are absent, but that goblet-cells are frequent in the epithelium except in the lateral walls between the turbinates. In the latter place there are serous glands which resemble the parotid in structure. The glandular cells contain tingible granules in the protoplasm and the epithelial cells in the excretory ducts show distinct striation.

KRAUSE.

339. The method consists of injecting the open spaces with the known method of mercury and photographs with Röntgen rays. KRAUSE.

340. A posterior ethmoid cell extended deep into the posterior part of the orbital roof. KILLIAN.

b.—GENERAL PATHOLOGY AND SYMPTOMATOLOGY.

341. LICHTWITZ. The abuse and dangers of the nasal douche. *Sem. medicale*, No. 51, 1897.

342. HECHT, H., Heidelberg. The therapeutic use of electrolysis in the nose and throat. *Arch. f. Laryngology*, vi., 2.

343. DELAVAN, D. BRYSON. Method for the relief of certain enlargements of the turbinated bodies. *New York Med. Jour.*, Dec. 11, 1897; Amer. Laryng. Assoc., 1897.

344. PYNCHON, EDWIN. Nasal bougies and drainage-tubes. *New York Med. Jour.*, Oct. 23, 1897.

341. LICHTWITZ has abandoned all forms of nasal irrigation; he has met with the well-known sequelæ, headache and otitis, but also loss of smell after the use of disinfecting solutions. As the irrigation may be a cause for diseases of the accessory sinuses it should be discontinued. ZIMMERMANN.

342. HECHT has employed electrolysis in the treatment of sixty-six cases of various nasal lesions at Juracz's clinic, and was very much pleased with the results. The lesions include deviations and spurs of the septum, synechia, tumors of the nose and the naso-pharynx, reflex neuroses, ozæna, and various external affections of the nose. Though, according to the reviewer, many of these lesions could be treated by other simpler methods as well, the article is well worth careful study. ZARNIKO.

343. In subacute or chronic cases of engorgement (not hypertrophy) of the turbinated corpora cavernosa, DELAVAN introduces a lancet-pointed needle or minute knife obliquely through the mucous membrane, carried backward and parallel with the surface as far as the swelling extends. Not more than two punctures are to be made at one sitting. M. TOEPLITZ.

344. The tubes of red vulcanite are made perforate, in pairs, for either nostril, three inches in length for the adult, slightly irregular in curve both vertically and horizontally, and with a large perforation at the anterior end for introduction of a hook for removal. The turbinal side of the tube is concave, the septal

slightly convex, the vertical cross-section crescentic with blunted and thickened point showing a ledge at the upper and lower margins.

The bougies, made of two sizes, are solid and without perforations, but otherwise of the same dimensions as the drainage-tubes.

M. TOEPLITZ.

c.—OZÆNA.

345. RICE, CLARENCE C. Treatment of atrophic rhinitis. *New York Med. Jour.*, Nov. 20, 1897 ; Amer. Laryng. Assoc., 1897.

346. CASSELBERRY, W. E. Atrophic rhinitis, its nature and symptoms. *New York Med. Jour.*, Nov. 20, 1897; Amer. Laryng, Assoc., 1897.

347. AUCHÉ et BRINDEL. Bacteriology of atrophic rhinitis. *Rev. hebdom. de lar., d'otol.*, No. 41, 1897.

348. GRADENIGO, Prof. The treatment of ozæna. *Monatschr. f. Ohrenheilk.*, No. 11, 1897.

345. RICE reviews all the methods which have heretofore been recommended, such as with antiseptics, antitoxine, electricity, cotton plugs, bougies, inhalations, massage, cauterizations, sprays, and douches.

The object of treatment is cleansing, healing of ulcerations, promotion of adequate nasal respiration, and restoration of moisture. Cleansing is effected through cups with saline solutions, obstructions from the middle turbinal are removed by scissors, ulcerations are treated by frictions with stimulating disinfectants, lubrication is accomplished with oils. In cases with tendency to subacute inflammations, insufflation of powders is used.

The treatment ought to be constitutional also by advising out-of-door exercise and work. M. TOEPLITZ.

346. Different phases of the disease are of diverse or multiple causation. The majority of the cases are fœtid, the minority non-fœtid. Simple dry rhinitis is more frequently found in adults; ozæna, commencing in young subjects, leads to recovery after middle age. These types often blend one into the other. The disease is bilateral, except in cases with markedly deviated septum. Ozæna may be due to tuberculosis. Simple dry rhinitis is also found in alcoholic and gouty persons. Hypertrophy may precede atrophy in some cases of simple dry rhinitis of later life.

M. TOEPLITZ.

347. Investigations whether the atrophic rhinitides with and without ozæna differed bacteriologically. No definite conclusion was reached. In 20 cases Löwenberg's capsule bacillus was always found; in addition, the pseudo-diphtheria bacillus 18 times, the Pes-Gradenigo 3 times, staphylococcus 12, and streptococcus 4 times. In the 6 cases without ozæna the Pes-Gradenigo bacillus was wanting. ZIMMERMANN.

348. GRADENIGO used diphtheria antitoxin in ozæna without result; the action of intra-muscular injections of iodine were very satisfactory, though painful.

d.—SEPTUM.

349. THEISSING, H. Perichondritis and serous cysts of the nasal septum. *Inaug. Dissert.*, Breslau, 1897.

349. In the first part THEISSING treats of the traumatic affections of the nasal septum: simple fractures, hæmatoma, traumatic serous cysts, and abscess; of the last lesion the histories of a double and a single case are fully recorded.

The second part treats of the non-traumatic lesions: abscess (of unknown origin), serous perichondritis of the nasal septum, serous cysts with history of a case with sudden appearance of a double serous cyst and evacuation of a clear fluid on puncture six days later. H.

e.—ACCESSORY CAVITIES.

350. POWER, D'ARCY. Empyema of the antrum (maxillary) in a child aged eight weeks. *British Med. Jour.*, Sept. 25, 1897.

351. BRYAN, J. H. Treatment of chronic frontal sinusitis. *New York Med. Jour.*, Oct. 2, 1897; Amer. Laryng. Assoc., 1897.

352. LOCKHARD, J. B. Transillumination; its fallacy as a diagnostic means. *New York Med. Jour.*, Nov. 27, 1897.

353. GAUDIER. A case of tubercular empyema of the maxillary sinus. *Revue hebdom. de lar., d'otol.*, No. 44, 1897.

354. BOENNINGHAUS, G., Breslau. Resection of the facial and nasal walls of the maxillary sinus with implantation of the nasal mucous membrane in obstinate cases of empyema. *Arch. f. Laryngol.*, vi., 2.

350. A wasting boy, aged eight weeks, came to D'ARCY POWER at the Victoria Hospital for Children with a discharging abscess at the lower part of the right lower eyelid. The right

side of the face was somewhat fuller than the left, and the skin of the lower eyelid and cheek was red and hot. A considerable quantity of pus could be squeezed out by pressure upon the cheek, and on looking into the mouth a small quantity of pus could be seen exuding from the alveolar border. A probe passed along the sinus in the cheek showed that the upper part of the superior maxilla was bare. Power enlarged the sinus, scraped away some granulation tissue, and made an opening through the floor of the antrum, so that a drainage tube could be passed from the eyelid into the mouth. About a drachm of pus came away at the operation. Forceps had been used at birth, producing bad bruising of both sides of the face, the right more than the left. At one month there was some difficulty in closing the mouth, and the bottle was refused; about the same time redness and swelling appeared below the right eye, an abscess subsequently forming. Death occurred ten days after the operation.

CHEATTLE.

351. The combined affections of the sinuses are brought about by extensions through the bony partitions, or directly through anomalous passages. The infundibulumis often continued as a half tube and terminates directly in the maxillary foramen. BRYAN advocates an operation from without according to Ogston and Luc with a small crowned trephine just outside the median line above the supraorbital ridge. The fronto-nasal duct is enlarged by passing a trocar into the nose and a self-retaining rubber drainage is introduced. A woman, aged fifty-eight, after the left antrum of Highmore was opened from second molar, and anterior ethmoid cells and loose spicula of bone contained therein were curetted, was thus operated. On eighth day after operation the drainage tube had slipped out, and an abscess in lower half of line of incision had to be opened. The patient made a good recovery. M. TOEPLITZ.

352. LOCKHARD outlines the most important anatomical conditions with their effect upon the transmission of light. Typical antral cavities are the exception. The variations are as follows: (a) the floor of the maxillary antrum lies lower on one side than that of the nose, while the opposite may be normal; (b) the facial wall may be thin on one and thick or diploic on the other side; (c) one sinus may be entirely absent; (d) the antrum of one side may be filled with fatty bone tissue or with compact bone; (e) both facial walls may be unusually thick; (f) protuberances into

the antrum from neighboring bone; (g) one antrum may be divided by horizontal bony septum into two distinct cells; (h) contraction of the sinus by sinking of the walls. In the frontal sinuses many irregularities are also observed. Besides a typical position of the septum an accessory septum is found at times; rarely one cell is absent, the walls thickened and at different planes. The two cavities communicate one with the other, or with that of the orbit and ethmoid sinus. A frontal cell may be occupied by a large anterior ethmoidal cell.

Transillumination will uphold a diagnosis which has been made, but alone it is not infallible. M. TOEPLITZ.

353. The tubercular nature was established with the microscope and inoculation. It presented the typical picture of empyema with swelling of the lower turbinate and polypi. Puncture through the alveolus was unsuccessful, and a broad opening through the canine fossa was made, and typically tubercular granulations were scraped away. General condition was much improved. A small fistula in the gum remained.

ZIMMERMANN.

354. BOENNINGHAUS comes to the following conclusions: 1. Many cases of antral empyema can be successfully treated from the natural opening, the alveolus, or the lower nasal passage. 2. A part of the cases which do not do well under this treatment can be cured by a broad opening in the ant. wall from the mouth and local curettage. These are cases where the mucous membrane is diseased in one region, usually from a carious tooth. 3. The remainder do not heal; the entire mucous membrane is diseased. A broad opening must be made, and all the mucous lining curetted. The bare bony wall can then only be brought to epidermatize by resecting the nasal wall and implanting the nasal mucous membrane. ZARNIKO.

f.—TUMORS.

355. SUTTON, J. BLAND. Notes on some unusual cases of tumors. *Practitioner*, Nov., 1897.

356. WRIGHT, JONATHAN. Papillary œdematous nasal polypi and their relation to adenomata. *New York Med. Jour.*, Nov. 13, 1897; Amer. Laryng. Assoc., 1897.

357. HOPKINS, F. E. Adeno-carcinoma of the nose. *New York Med. Jour.*, Nov. 13, 1897.

358. LELAND, G. A. Adeno-carcinoma of the nose. *New York Med. Jour.*, Nov. 13, 1897; Amer. Laryng. Assoc., 1897.

359. BARRETT, J. W. Sarcoma of the nose. *Intercolonial Medical Journal of Australasia*, Oct. 20, 1897.

360. KUHN, Prof., Strassburg. Angioma of the nose. *Biblioth. d. Gesammt. medic. Wissenschaften.* Teschen, 1897.

361. KUHN, Prof. Carcinoma of the nose. *Ibid.*

362. HELLMANN, L., Würzburg. Hard papilloma of the nasal and frontal sinus mucous membrane. Transition to carcinoma. *Arch. f. Laryng.*, vi., 2.

355. In describing dermoids arising in the internasal fissure, BLAND SUTTON points out that those which occur on the bridge of the nose differ in some particulars from those which are met with near the tip; the latter are always situated in the middle line, appearing most commonly only as a narrow recess lined with hair, which may be long enough to project beyond it; occasionally they assume the familiar tumor-like shape; these recesses are in all probability due to incomplete fusion of the globular processes; he states that they are very common, more frequent in men than in women, and rarely require treatment; their mode of origin and characteristics agreeing with the hair-lined recesses so common in the neighborhood of the coccyx, and known as post-anal dimples. The former, occurring on the bridge of the nose, arise in the same manner as those which occur on the scalp, more especially in the neighborhood of inion and bregma.

ARTHUR CHEATLE.

356. WRIGHT examined two growths taken from the nose, one consisting of papillary masses of long standing with tendency to recurrence, the other, of pinkish-gray cauliflower masses. External configuration shows numerous finger-like processes, which are microscopically explained. The proliferation goes on upon the surface as well as in the glands. Adeno-carcinoma of the nose, in many places, cannot be distinguished microscopically from papilloma. The gradations in development from mucous polypus through benign adenomatous growth into a malignant tumor can thus be well studied. M. TOEPLITZ.

357. HOPKINS' patient, aged eighty-three, suffered for twelve years from obstruction of left nostril, which, after six years' standing, became entirely occluded so as to push the septum over to the right. There were brownish masses in vestibule and a gray slough was hanging down from left choana. The micro-

scopical examination by Dr. Jonathan Wright revealed the masses to be made up of cylindrical epithelium, arranged in form of tubules and acini at some places, at others crowded in irregular masses, but with a general tendency to concentric arrangement. There follows a table of twenty-three recorded cases and general remarks upon statistics, symptoms, diagnosis, and treatment by Wright. M. TOEPLITZ.

358. LELAND's patient, female, aged fifty, exhibited obstruction of right nostril by a large tumor, which developed more rapidly after partial removal. Inner canthus of the right orbit was swollen and showed fistula discharging pus. Right eye was pushed to the right, and bulging. Nares and naso-pharynx were filled with the firm, grayish-white masses. A cellulitis developed under the right zygoma and extended to the roof of the mouth. Patient died and the autopsy was made by Dr. Councilman. On stripping the dura from the orbit a small amount of pus welled up. Cribriform process was eroded. Masses in the nose appeared to spring from all the processes of the ethmoid which was destroyed. Tumor grown into septum, through anterior wall of antrum into the cheek, connective tissue, and muscles of the latter; tissues back of right, and somewhat of left orbit infiltrated. Metastasis in pleura; general amyloid degeneration. General infection with streptococcus pyogenes. Tumor was adenoma with tendency to carcinoma. M. TOEPLITZ.

359. At a meeting of the Medical Society of Victoria, Australia, BARRETT related the case of a woman who suffered from "stuffy nose" for five years, and protruding polypi for three years; after removal with snare and cautery, headaches and a limpid discharge from the right side of the nose came on, later there was marked proptosis, œdema, and redness of eyelids, and conjunctival injection. A hard, not vascular, growth was then found on the right side, projecting into the naso-pharynx. Examination of snared portions showed it to be sarcomatous. After ligating the external carotid and performing tracheotomy, the growth was removed together with part of the superior maxilla, the palatal plate being preserved. CHEATLE.

360. KUHN thinks that the present practice of designating angiomata as "bleeding polyp of the nasal septum" does not agree with the anatomical description of the tumor. This term is unnecessary, as the tumor is a cavernous angioma. The structure of the tumor is described and illustrated. H.

361. Carcinoma of the nose is much rarer than sarcoma. According to Garth, in over 11,000 carcinomas of the various parts of the body, there were only 4 of the nose and the accessory cavities. In 28,000 nose and throat patients there were 10 sarcomas and 2 carcinomas of the nose. H.

362. HELLMANN gives a careful history and description of a case of hard papilloma of the septum. The patient, forty-six years old, had suffered for twelve years with recurring tumors of the right nasal passage, which were repeatedly removed and called hard papilloma. In 1895 he was referred to the author, as an empyema of the frontal sinus was suspected. After removal of large tumor-like masses the empyema was found to be present together with double choked disc. Both frontal cavities were opened. In the left, pus and numerous papillomas were found; in the right, mucous membrane fairly normal, inspissated mucus. After the operation, euphoria. Choked discs remain. Two weeks later renewed headache, weakness, and clonic spasm in the right-sided extremity. Cerebral symptoms aggravated. Right beginning optic neuritis. At a second operation, two weeks later, both frontal sinuses are freely exposed, the nasal wall is perforated, many tumor-masses are removed from the frontal and ethmoidal sinuses and the nasal meatus. The bony nasal septum is necrosed and perforated by the tumor. The microscopical examination showed that the tumor was partly hard papilloma and partly epithelial carcinoma. The tumor recurred, and death ensued in three weeks. The author believes that the tumor originally was papillomatous and later became carcinomatous. ZARNIKO.

g.—OTHER AFFECTIONS OF THE NOSE.

363. JANKELEVITSCH. On nasal hydrorrhœa. *Rev. hebdom. de lar., d'otol.*, No. 51, 1897.

364. GAREL. Uncommon fractures of the nose, with necrosis and extrusion of the inf. turbinate. *Ann. des mal. de l'or., du. lar.*, No. 10, 1897.

363. JANKELEVITSCH adds eight cases to the eighteen collected by Bosworth. Aside from the secondary form of nasal hydrorrhœa which accompanies polypi, diseases of the sinuses and central disturbance, there is a primary form not to be mistaken for hay-fever and other nervous coryzas. The author considers it to be a vaso-motor disturbance. The treatment consists in daily massage. ZIMMERMANN.

364. A similar case to the one published by Freytag in 1896. A girl, fourteen years old, was struck on the right side of the nose by a ball. Purulent discharge set in. Two years later a foreign body was discovered, which proved to be the necrotic lower turbinate. ZIMMERMANN.

h.—PHARYNGEAL TONSIL.

365. McBRIDE and LOGAN TURNER. Naso-pharyngeal adenoids. A clinical and pathological study. *Edinburgh Medical Journal*, vol. i., new series, pages 355, 471, 598.

366. KUHN, Prof., Strassburg. Adenoid vegetations. *Bibliothek. der Gesammt. med. Wissensch.* Teschen, 1897.

367. KAYSER, R., Breslau. Diseases of the lymphatic ring. *Handbuch der Laryngol. u. Rhinologie.* Wien, 1897.

368. BARTH, A., Leipzig. Pharyngeal tonsil and ear. *Monatschr. f. Ohrenheilk.*, No. 11, 1897.

369. CHOLEWA, Berlin. The operative removal of adenoid vegetations. *Monatschr. f. Ohrenheilk.*, No. 12, 1897.

370. LENZMANN, R., Duisburg. The operation for adenoids and the narcosis. *Therap. Monatsch.*, No. 9, 1897.

371. LEYSER, Darmstadt. The narcosis in operations on adenoids. Verein hessischer Aerzte. *Ibid.*, No. 12, 1897.

372. OLLENDORF, Barmen. The same. *Ibid.*, No. 12.

H. NAEGELI—AKERBLOM. Rütli. The same. *Ibid.*, No. 10.

365. McBRIDE and LOGAN TURNER have made an interesting and instructive analysis of 500 cases.

The following is a table of the number of patients at different ages:

0 to 5 years	57
6 " 10 "	141
11 " 15 "	115
16 " 20 "	86
21 " 25 "	38
26 " 30 "	24
31 " 35 "	18
36 " 40 "	4
41 " 45 "	1
46 " 50 "	4
Total	488

They have never met with adenoids growing from the margin of the choanæ or Eustachian tubes, but they may be met with in Rosenmüller's fossæ. The sessile, ridged form is invariable in their experience; in this all will agree with them who remove the mass with some form of Gottstein's curette, such as Delstanche's modification.

The following are their conclusions from histological examination:

1. That the ciliated epithelium may be converted into the stratified squamous variety, and the latter may become much thickened as the result of intermittent pressure to which the hypertrophy is subjected.

2. That this change tends to occur in the smaller naso-pharnyx of the young child.

3. That the cilia may become destroyed over large areas and the epithelium thinned to a varying degree; and, further, that emigration of leucocytes is not general.

4. That there is a tendency to an overgrowth of fibrous tissue, which commences in and around the blood-vessels, and gradually invading the lymphoid tissue leads to shrinking of the growth.

5. That this process is not confined to the period at or after puberty, but occurs also in very young children, and is therefore independent of the age of the patient.

366. A concise general treatment of adenoids.

367. An excellent and exhaustive treatment of the subject, giving the present position on all questions relating to adenoids.

368. BARTH does not practise digital examination. He prefers Beckmann's curette and the cold snare. Thirty per cent. of the patients with adenoids had ear troubles. KILLIAN.

369. CHOLEWA also prefers Beckmann's curette to Gottstein's, though the particles are liable to remain hanging to the post. pharyngeal wall. In children under one year he uses Hartmann's curette. KILLIAN.

370 to 372. This is a discussion as to the merits of narcosis in operations on adenoids. LENZMANN and OLLENDORF operate with narcosis, LEYSER and NAEGELI without. MANASSE.

SOFT PALATE, PHARYNX, AND BUCCAL CAVITY.

373. MYLES, ROBERT C. Basal and basi-lateral diseases of the faucial tonsils. Meeting of the Section of Laryngology of Academy of Medicine, New York, Dec. 23, 1897.

374. HARTMANN, J. H. Angioma of the tonsil. *New York Med. Jour.*, Dec. 25, 1897.

375. HUGUES. Chronic abscess of the tonsils. *Rev. hebdom. de lar., d'ot.*, No. 44, 1897.

373. MYLES denies the frequency of adhesions of the pillars to the faucial tonsils. He dwells particularly upon hypertrophy at the base or on the sides of the tonsils, basal or basi-lateral hypertrophies, which push out the tonsil, carrying with it the pillars and giving the appearance of adhesions. He uses for their dissection from the sheath delicate knives. Small hypertrophies are removed by means of Myles's lateral punch forceps. Three appended cases, one of which has especial bearing upon the formation of peritonsillar abscesses, are fully described, and they illustrate the conditions and the methods for their relief.

M. TOEPLITZ.

374. HARTMANN'S first case occurred in a woman, aged twenty-eight, in whom the growth occupied the lower two-thirds of the right tonsil. In the second case, that of a man, aged thirty-two, the entire surface of the left tonsil was occupied by a large mass of an angiomatous outgrowth, which was nodular and irregular in outline, of dark purplish color, and of about the size of a pecan nut. It was slowly removed with wire écraseur, but a profuse bleeding took place after twenty-four hours. The growth returned after three years at the lower third of the tonsil. Microscopically, it consisted of capillary blood-vessels with thin or thickened walls, which were imbedded in a stroma of connective tissue. M. TOEPLITZ.

375. HUGUES differentiates between the epithelial detritus and tonsillar stones occurring in the crypts and abscesses developing in closed follicles. These are sequelæ of inflammations in the tonsillar tissue and show fistulous tracts. The tracts are often difficult to find as they open in front and back toward the posterior palatal arch. If the fistula can be found, it should be opened up with galvano-cautery and painted with iodine on the following day; if no fistula can be found, the tonsil should be removed. Four cases are briefly described. ZIMMERMANN.

REPORT OF THE TRANSACTIONS OF THE SECTION ON OPHTHALMOLOGY AND OTOLOGY OF THE NEW YORK ACADEMY OF MEDICINE.

By Dr. W. B. MARPLE, Secretary.

OTOLOGICAL PART OF THE MEETING OF MAY 16, 1898.

The President, Dr. E. Gruening, in the chair.

The evening was devoted entirely to the presentation of clinical cases in otology.

Dr. E. B. Dench.—**A Case of Ossiculectomy, Wounding of Jugular Bulb, Septic Thrombosis of the Internal Jugular. Operation. Recovery.**

The patient was a young woman who had suffered from a purulent otitis from childhood. The right ear had undergone spontaneous cure, but the left ear had continued to discharge at intervals. An examination of the left ear showed distinct caries within the tympanic cavity, and I, therefore, advised the removal of the ossicles. This operation was performed, and the malleus and incus removed; both were carious. Areas of softened bone were also found both in the tympanic vault and on the internal tympanic wall. After the ossicles had been removed and the curette freely used, a *bluish mass was seen in the floor of the tympanum.* Upon touching the mass with the probe, it was found to yield to pressure, as if filled with fluid. It was immediately recognized as the *bulb of the internal jugular vein*, its exposure being due to a defect in the floor of the tympanum, either the result of caries, or an anomalous anatomical condition. Despite great care in using the curette, the bulb was punctured, and rather free hemorrhage followed. This hemorrhage was easily controlled by packing with strips of sterile gauze. When all carious bone

had been removed, the patient was returned to bed. Two days after the operation, the packing from the canal was removed. Although this was done very gently, considerable hemorrhage occurred, so that it was necessary to reapply the tampon. The temperature remained normal until the fourth day, when it began to rise steadily, and in the evening was 103.8°. The patient showed distinct evidences of severe constitutional infection. There was slight tenderness on pressure, just below the tip of the mastoid along the anterior border of the sterno-mastoid muscle. This sign had been carefully watched for, and only appeared on the fourth day after operation. The case was seen in consultation, by Dr. Abbe, who agreed with me, as to the probable presence of a septic thrombus in the internal jugular vein, and also concurred in the opinion that immediate operation was necessary.

With the assistance of Dr. Abbe, I operated the same evening. An incision was made along the anterior border of the sterno-mastoid muscle, extending from the level of the cricoid cartilage to the tip of the mastoid. From this point it was continued parallel to the line of the insertion of the auricle, to a point just above the superior wall of the meatus. The internal jugular was then exposed in the neck, and at the lowest point of the incision was found to be perfectly healthy. Just below the juncture of the facial with the internal jugular, a double ligature was passed about the latter vessel; the facial was divided between two ligatures, close to the point where it entered the jugular. I next entered the mastoid antrum in the usual way. The mastoid cortex was exceedingly dense, and the antrum small. The lateral sinus was then exposed at its sigmoid portion and followed downward toward the jugular bulb, and upward for a short distance along its horizontal portion. The sinus was found to be perfectly normal. The internal jugular was then followed upward towards the bulb. At a point about one-half an inch below the jugular fossa, the wall of the vein was thickened, and its lumen was occluded by a thrombus. A ligature was passed about the vein as high up as possible and securely tied. The vein was then divided low down in the neck between the two ligatures already mentioned, and the upper segment, about 2½ inches long, excised. In attempting to remove the jugular process of the occipital bone, the jugular bulb was accidentally wounded. Free hemorrhage took place, showing that there was no interference with the circulation at this point, and that the thrombus was localized. In order to

secure perfect drainage of the middle ear, the posterior wall of the meatus was broken down, thus converting the middle ear, the mastoid antrum and the external auditory canal into one large cavity. The lower portion of the wound was closed with a continuous catgut suture, the remainder being left open. The wound and external auditory canal were then packed with iodoform gauze, care being taken to isolate the exposed meningeal area as much as possible from the middle ear by means of iodoform gauze packing. The parts were then covered with several layers of sterile gauze and a bandage applied. The temperature immediately fell to 100°, and from this time never rose above 101°. The first dressing was removed on the fourth day, and the wound found to be in a perfectly satisfactory condition.

The patient made an uninterrupted recovery.

Dr. Robt. G. Lewis presented a case of **Cholesteatoma Complicating a Bezold's Mastoiditis**; operated upon by the Schwartze-Stacke method.

The patient twenty-five years of age, female, presented herself February 28, 1898. Otorrhœa, since early childhood. At times, the discharge would apparently cease for a few weeks or months, to be followed by severe pain and an active discharge.

When seven years of age, patient swallowed a pin. In her fourteenth year an abscess developed in the neck, which opened about an inch below the tip of the mastoid process. The discharge from the abscess was very profuse and in this discharge a "rusty pin was found." The abscess healed in a short time.

December last the patient caught cold and along with it developed an unusually severe pain in the mastoid. A week later, at the seat of the former "pin abscess," another abscess developed and opened spontaneously; the pus was very offensive and profuse.

On her first visit, Dr. Buck saw her; he found tenderness on pressure over the mastoid, but little œdema; a small pouting ulcer existed an inch below the tip of the mastoid process; on exploring with a probe it passed upwards for over two inches through the tip of the mastoid process; the external auditory canal was inflamed and stenosed; in its posterior wall was an opening which led into the mastoid cells.

On March 4th I operated. I found the mastoid process was composed of a single cavity, the bone being simply a shell, and lying in it like a kernel in a butternut was a cholesteatoma as

large as a large-sized olive. On removing this I found a perforation in the digastric groove of the mastoid process, which opened into a sinus leading to the ulcer on the neck ; another one, about two by three millimetres, opened into the midle cerebral fossa ; a third, about the same size, opened into the sigmoid sulcus ; a fourth, of considerable, size opened into the external auditory canal. I removed all suspicious bone, including the entire upper and posterior wall of the external auditory canal. The membrana tympani as well as the ossicles were destroyed. Before completing the operation, my patient's heart grew weak and I was compelled to dress the case and have her placed in bed. The facial nerve was not injured. March 14th I curetted all the tissues involved, but did not find it necessary to remove any further bone. I then divided the cartilaginous external auditory canal into a posterior and an anterior flap ; the posterior flap I turned inwards at right angles and sutured it to the posterior edge of the postauricular incision. I then united with sutures the two edges of this incision, inserted a strip of gauze through the opening of the external auditory canal into the large cavity which I had made, and which consisted of the external auditory canal, the tympanic cavity, and the mastoid cells. Facial nerve injured with marked facial paralysis.

At the first dressing I found I had obtained primary union with the exception of a quarter of an inch at the lower angle of the wound.

May 16.—Complete epidermitization of the cavity has not been obtained as yet, but will probably be in another few weeks. A slight discharge is still present. The facial paralysis is much improved, and when the patient's face is in repose can not be seen ; I think it will gradually disappear.

The CHAIRMAN said that we see cases where the process of disease caused a persistent opening in the canal ; cases which have been under observation for years, throwing off cholesteatomatous masses from time to time. It is preferable to have an opening in the canal.

Dr. F. WHITING presented a case of **Extradural Abscess with Extirpation of the Petrous Pyramid.**

A child of two years was brought to the New York Eye and Ear Infirmary in March. It had been operated upon two months previously at Hudson Street Hospital for mastoiditis of the left side.

Physical examination shows meatus of A. D. filled with pus and the posterior wall of the membranous canal collapsed, obscuring view of fundus.

Mastoid aspect presented a large, irregular wound, the granulations upon the edges of which were sloughing, and bathed in an ichorous discharge. There protruded through these granulations a considerable area of necrosed and blackened bone.

Facial paralysis was complete.

Upon enlarging the opening in the mastoid and retracting the flaps, the periosteum was found to be extraordinary thick and very firmly adherent; the cortex of the entire apophysis was necrosed. By employing gentle traction three large sequestra were removed, one of which was 1½ inches long by ½ inch in the other dimensions. This fragment in its normal state had constituted the major portion of the superior and posterior surfaces of the petrous pyramid, and extended upon its upper surface to the apex of the pyramid. The two remaining sequestra and the carious bone removed in addition by curetting, comprised practically all of the mastoid and petrous bones. The carotid artery was exposed by the removal of the bony walls of its canal, and the trunks of the auditory and facial nerves were uncovered at the internal auditory meatus.

The sigmoid sinus, from the knee to the jugular foramen, lay in the wound, and although its walls were thickened from periphlebitis, no exploratory puncture of them was made because of the absence of any symptoms of sinus involvement. The caries of the temporal bone was so extensive that it was necessary to remove a large part of the squama forward and downward to the temporo-sphenoidal suture.

The exposure of the base of the brain after the operation was very extensive.

There was no reaction from the operation, and healing was undisturbed and complete. The tissues submitted to the pathologist were examined by Dr. Dixon, who reported them as not tubercular.

Discussion.—Dr. GRUENING asked the opinion of the Section as to the advisability of removing granulations from the sinus. He thinks these granulations are oftentimes a barrier to the invasion of the sinus by micro-organisms. He has, in his recent cases, refrained from interfering with them except when they are on the dura mater.

Dr. H. KNAPP said that he had presented to the Society a case in point a year ago. There had been extensive caries of the bony parts, and the wall of the sigmoid sinus had been covered with blackish-red granulations which were necrosing. These he had scraped away, and the case had done well.

Dr. MCKERNON said that he had always removed granulations from the sinus with a dull curette. One case he had seen where they had not been removed. The case subsequently came under his care, and did better after the removal of the granulations.

Dr. WHITING said it had been his custom to remove the granulations after having cleaned the wound thoroughly. He believes that where he had removed these partly necrotic granulations from the sinus walls his results had been better.

The CHAIRMAN said that it was a question sometimes whether the granulations were necrotic (and consequently to be removed) or healthy.

Dr. J. F. MCKERNON presented a case of **Operation for Subdural Abscess.** Patient, aged thirty, with history of O. M. P. A. following severe cold and sore throat, five weeks previously. Profuse purulent discharge from right meatus, with supero-posterior wall of canal collapsed and bulging. Mastoid exquisitely tender. Pain was also pronounced over the right temple, and radiated backward over the side of head and occiput. Operation. Apophysis necrotic, removed. Necrosis extended an inch beyond sinus, which was exposed one inch and a half downward from its bend toward the bulb. Sinus aspirated twice, contents normal. Roof of antrum carious, and removed over an area of an inch. Dura dark, incised, and a grooved director passed upward and forward into middle fossa, followed by discharge of pus, about four drachms. Tegmen tympani subsequently found to be soft, and probe passed into abscess cavity. Cavity syringed with 1 : 10,000 sublimate, and dressing applied. Patient made a good recovery. A chill and rise of temperature on day following operation was found to be due to attack of acute tonsillitis.

Dr. H. KNAPP presented a case of **Perichondritis of the Auricle.** The patient, when first seen, showed a doughy swelling on the anterior edge of the antihelix. No pain, no injury. Incised, with escape of viscid liquid. Pressure bandage applied. In a few days swelling larger than before. Again freely incised and packing with sterilized gauze; pressure bandage. In the

following days the whole auricle, except lobula, swollen, red, and painful. On removing dressing pus escaped. Auricle now transfixed with a scalpel; gauze wick passed through opening. Swelling and discharge soon diminished, and recovery without deformity now seems assured. Was well six weeks later; no deformity.

Dr. COBURN presented a similar case, incised and packed, then pinna pierced and wick passed through. Probably due to traumatism. Good recovery without deformity.

Dr. WHITING presented a case of perichondritis of three months' standing. No history of any traumatism, nor exposure to great cold or heat. He sterilized the parts, and drew off (by means of a hypodermic needle) the contents, consisting of straw-colored fluid, and then, through the same needle puncture, he *injected Lugol's solution* until the walls of the cavity bulged. The result was extremely satisfactory. There was quite sharp pain in the auricle for an hour, but otherwise not the slightest reaction. Six weeks afterwards the cure was complete without discoloration or deformity.

He presented this case because it had been stated in some text-books that this mode of treatment was *not* to be pursued.

Dr. TYSON said he had had good results from swabbing with tinct. iodine and then pressure.

Dr. MCKERNON had treated these cases at first in a manner similar to that of Dr. Knapp. Then he had aspirated and injected 5 % formaline. Then covered with white precipitate ointment and applied pressure. One of his assistants had informed him that the white precipitate alone was used successfully in Vienna.

Dr. FELIX COHN had treated a case first by incising and packing. No result after five weeks. Then he inserted a drain (tube or gauze), and case did well.

Dr. KNAPP said these cases were not uniform. Some came from middle-ear suppuration, others were idiopathic; many, especially the hemorrhagic form, were traumatic. They were well known to the boxing fraternity. He had recently seen a case which quickly recovered with pressure only. He had of late followed the treatment first advised by Dr. Gruening, that of transfixing the auricle and draining from both sides. He was glad to learn that aspiration and injection of Lugol's solution also gave good results.

The CHAIRMAN said that Dr. Knapp was right in stating that

these cases are not all alike. Some are not serous but purulent, and these latter cases do better by transfixion (even multiple transfixion), but with this must be associated drainage.

Dr. DENCH said he had recently seen a case with considerable swelling. He arranged for operation, but case got well. Spontaneous absorption in these cases is rare, according to his experience.

Dr. M. TOEPLITZ showed some cases of **Otorrhœa Cured by Radical Operation and Other Measures.**

CASE 1. Patient, aged thirty-five, with chronic otorrhœa, left ear. Had an exacerbation associated with mastoid tenderness. He removed carious bone from attic, mastoid, and inner wall of tympanum, and split external meatus horizontally. Four and a half months subsequently, patient was cured with a persistent post-auricular opening.

CASE 2. Patient, aged twenty-four, O. M. P. C., left, since childhood. Here caries of ossicles and aditus was found, the external meatus was split horizontally into two flaps (Panse modified). Complete facial paralysis, lasting ten weeks. Perfect cure of case in three months and a half.

CASE 3. Aged eighteen, O. M. P. C., exenteration of tympanic cavity from external meatus. Complete recovery in six weeks.

CASE 4. Patient with acute otitis with mastoid involvement. Operation on mastoid, repeated in two weeks; a third operation in two weeks; and finally, a week later a fourth, as radical as possible, into aditus ad antrum. After-treatment lasted more than two years. Tubercular ostitis of mastoid.

Dr. E. GRUENING presented a case of *a*, **Streptococcus Mastoiditis Followed by Erysipelas.** The patient, a young man, had an intra-nasal operation performed on the left side and began to suffer from pain in the right ear a few days later. The right drum was pierced and the ear discharged freely, but continued to ache. On admission to the ear wards of the Mt. Sinai Hospital the man appeared to be very much prostrated and complained of intense headache. The right external auditory canal was filled with fluid pus, and both sides of the nose contained muco-pus. The mastoid was very tender both over the apex and antrum. Cultures of the nasal and aural pus showed pure streptococcus, the cocci presenting themselves in short and long chains. The mastoid cells were opened and found to contain pus of the same nature. The destruction of bone tissue in the mastoid was very extensive, reaching far backward over the sigmoid sinus, one inch

of which was exposed, after the removal of the diseased bone tissue. After the operation the temperature was 99.6°, pulse 70. The next morning the temperature rose to 102°, and in the course of the day to 103.4°, and in the evening to 104.2°, with a pulse of 92. The wound looked well, the sinus was soft and the high temperature could not be accounted for. The following day the temperature was still 104.4°, and on removing the dressing it was found that the auricle and adjacent part of scalp and cheek were red and œdematous. In the course of the following four or five days the temperature remained high and the redness and swelling of the skin extended over the nose, to the left side of the cheek, and down the nape of the neck. The patient was treated in the isolation house of the Hospital with 60 % ichthyol and made a good recovery from the attack of erysipelas in about ten days. There was no case of erysipelas in the Hospital at the time of admission, and we must assume in the case an auto-infection. It is quite possible that the cases of erysipelas on record in connection with ear disease occurred in streptococcus otitis.

b. **Mastoiditis with Cholesteatoma in a Child.** This boy is eight years of age. He has had a discharge from his right ear as long as he can remember. Four weeks ago a large swelling appeared behind the ear. In one of our dispensaries an incision was made, and pus evacuated. Inasmuch as the wound showed no tendency to heal, he applied to the *Mt. Sinai Hospital* for admission. Here the regular mastoid operation was performed. The cortex was found to be much diseased and perforated at various points. The antrum cavity was very large and reached to the apex, and this whole space was filled with cholesteatomatous material. The table covering the sigmoid sinus formed a sequestrum measuring 20 *mm* in length. The sinus was covered with villous tough granulations. These were not removed. The presence of an extensive cholesteatoma filling the whole mastoid cavity of the child is of considerable interest.

The CHAIRMAN asked for expressions of opinion from members of the Section: (1) as to whether it is legitimate, where no indication of sinus trouble is present, to expose the sinus during the mastoid operation, so that, if subsequently the sinus becomes involved, the trouble can be reached more easily and promptly. (2) In post-aural abscesses in children it has been held that simple incision is adequate. In his experience, such treatment had rarely been sufficient, such cases requiring an operation on the mastoid process.

Discussion—Dr. WHITING said he had had a case where there was external otitis ; he had incised the furuncles in the canal and afterwards had done a mastoid operation where the flaps became subsequently widely infiltrated. In this case he had felt sure that the infection had come from the furuncles.

Dr. DENCH said that one cannot lay down any general rule in reference to opening of sinus. In a general way, he would answer Dr. Gruening's question in the negative, but if the technique is correct, exposure of the sinus can do no harm. He insists that the packing of the mastoid area over the seat of infection should be entirely separate from that of the portion of the wound where the dura is exposed. Nature does this when the soldering of the membranes takes place, limiting a meningitis, for example ; one should follow the same rule as much as possible in opening the brain. I limit the risk of infecting the dura. But it is not difficult to open the sinus at a subsequent operation. Personally he would prefer to do this only when symptoms arose indicating sinus involvement.

Dr. H. KNAPP said that he was guided by the aspect of the inner table. In recent cases, where this latter is white and eburnated, he lets it alone, and his results have been good. If the bone is brittle, it is oftentimes of benefit to open the posterior fossa, even the middle. In a case of influenza otitis with symptoms of acute meningitis, he opened both cavities and the dura appeared healthy. But two days later the dressings were soaked with abundant foul-smelling pus. His prophylactic opening had probably saved the patient's life, making a channel for the evacuation of a collection of pus which the operation had failed to reach.

Dr. WHITING said that his cases of cholesteatoma had always been in adults, and either in the tympanic cavity or antrum.

Dr. FELIX COHN said he had had a case of cholesteatoma in a boy seven years old.

Dr. MCKERNON said his experience with cholesteatoma had been limited to adults.

Dr. DENCH had had one case, æt. eighteen, where the antrum and mastoid were filled with cholesteatomatous masses.

Dr. WENDELL PHILLIPS had recently operated on a boy æt. fourteen. He had removed the mastoid cortex, and then found a cavity filled with cholesteatamatous masses which could be pulled out like ribbons. There was pus only at the tip. He established complete drainage from the antrum into the canal.

Dr. TŒPLITZ said that many more cases of cholesteatoma were reported in Germany than in America, probably because we don't call all these cases cholesteatoma.

Dr. COHN referred to the classification of cholesteatoma.

Dr. Dench agrees with Dr. Gruening about the insufficiency of simple incision in post-aural abscess in children. In all such cases coming under his care, the child is anæsthetized and a typical mastoid operation done. Always finds the bone soft.

Dr. WHITING has recently had two cases illustrating the point of Dr. Gruening about post-aural abscesses in children. A recent case, over the mastoid, was almost like a suppurating gland—it was so circumscribed. An incision revealed an abscess under periosteum, and two minute openings in the cortex which, under the curette, led through softened bone into the antrum. In a second case looking like a suppurating gland, he found a mass of pus under the periosteum, and held in position by sterno-cleido-mastoid and splenius capitis muscles at the tip.

Dr. KNAPP is in entire accord with Dr. Gruening in regard to these cases. One ought to go into the antrum in most of them. In two cases he found no pus in the antrum. The suppuration may originate in the cells of the posterior wall of the ear canal or the squamous portion, leaving the antrum free. As a rule, it is safe in these cases to go into the mastoid, and in the majority of cases we will find sufficient reason for having done so.

Dr. THOS. J. HARRIS reported a case showing **Marked Improvement in Hearing as the Result of the Use of the Bougie.** Had treated patient for chronic deafness first by catheter, and then with bougie. Six months ago, on using bougie, there was a distinct snap heard both by patient and by himself, followed by deafness and tinnitus lasting three days. Hearing then gradually improved, until now he hears conversation at several feet. Possibly bougie had caused rupture of some adhesive bands binding down one of the ossicles.

edies, and instruments, and to discuss in a progressive, yet conservative spirit all questions of present importance.

The ARCHIVES contain exclusively original papers on all branches of Ophthalmic and Aural Surgery, and original reports on the progress of Ophthalmology and Otology throughout the world. The original papers occupy about three-fourths of the space, and their scope embraces all subjects of scientific and practical interest in the departments of Ophthalmology and Otology.

Special attention is paid to the preparation of the Reports on the Progress of Ophthalmology and Otology. These Reports are intended to furnish *complete, systematic, and early reviews* of the current Ophthalmological and Otological literature of the world, and the work of preparing them is divided among a specially selected number of collaborators.

Under the heading of "Miscellaneous Notes" there will be published all kinds of professional news that concerns the Oculist and Aurist, *e.g.*, appointments, honors, resignations and vacancies, new ophthalmic and aural hospitals, prize questions and essays, announcements of Society meetings, etc.

Each volume contains besides a specified table of contents, an index of subjects and authors, both of the original papers and the reports, and a general index of the preceding seven years is added to every seventh volume.

Original papers of value from any source are solicited.

Communications for the English edition of the ARCHIVES OF OPHTHALMOLOGY should be addressed to DR. H. KNAPP, 26 West 40th Street, New York, those for the ARCHIVES OF OTOLOGY either to DR. H. KNAPP, or to DR. U. PRITCHARD, 26 Wimpole Street, W., London, England.

G. P. PUTNAM'S SONS, Publishers

NEW YORK
27 & 29 WEST 23D STREET.

LONDON
24 BEDFORD ST., STRAND.

PUBLISHER OF THE GERMAN EDITION
I. F. BERGMANN
20 Schwalbacher Strasse, Wiesbaden.

EDITORIAL NOTE.

In asking for continued support of the ARCHIVES from subscribers and contributors, the Editors offer no new program, but point to the record of the work that has been accomplished during the past twenty-eight years. At the first appearance of the ARCHIVES in 1869, they constituted the only periodical of their class in America, and had only a few predecessors in Europe. The international character of the ARCHIVES was a novel and distinctive feature.

The original program of the ARCHIVES to publish only original papers in semi-annual independent numbers has, in the course of years, been extended by the addition of reviews of the current ophthalmological and otological literature.

With the eighth volume, in 1879, the combined ARCHIVES, issued semi-annually, were divided into two separate journals, issued quarterly, and each of about the same size as the combined journal, and the reviews were converted into quarterly reports, systematic and comprehensive, though concise, on the progress of ophthalmology and otology.

Since that date, the ARCHIVES have developed into an extensive and conveniently arranged storehouse of knowledge for the instruction of the student and for reference by the practitioner and the investigator.

For more than ten years, the valuable material offered to the ARCHIVES has been so abundant that it has not been practicable to utilize for the English edition the full series of papers from the German, or the converse. Many articles had to be abridged, while of others abstracts only could be printed. Any one of our readers could, however, have secured, and can secure in future, from the American editor, or the German publisher, the loan of the original papers presenting the complete text.

It is the purpose of the editors to arrange, in the department of Reports, for the review of every publication which in their opinion contains material that can be called distinctive and important. It is, of course, impossible, within the limits of the ARCHIVES or of any similar journal, to give attention to every publication in their department of science. We may state further that it is not a part of our program to furnish a complete report on the *bibliography*, but only on the **progress** of ophthalmology and otology.

Though the systematic arrangement of the reviews is of importance for reference and comprehensive information, we shall publish, as early after the meetings as practicable, reports of the proceedings of societies, always bearing in mind that the ARCHIVES are not intended to be only a repertory of knowledge, but also a journal of news.

It is natural that the English edition of the ARCHIVES should give the advantage of time and space to Anglo-American contributors over the German, and *vice versa*. It is evident, however, that the association of the two editions lends strength to each, furnishing to the authors a wider circulation for their papers, and to the readers a larger and more diversified field of information.

NOTICE TO CONTRIBUTORS.

The editors and publishers of the ARCHIVES beg to offer some suggestions to authors who propose to favor them with their contributions.

1 As original communications the ARCHIVES can accept only such papers as have never been printed nor are intended to be printed in other journals. If a preliminary communication on the subject of a paper has been published, the author is requested to state this in the letter accompanying his manuscript. It is understood that contributors to these ARCHIVES and editors of other periodicals will make no abstracts of the original papers published in this journal without giving it due credit for the same.

2. Authors will receive gratuitously twenty-five reprints of their articles. If a greater number is desired,—notice of which should be given at the head of the manuscript,—only the additional cost of presswork and paper will be charged to the author.

3. In preparing manuscript for the compositor it is requested that the following rules be adhered to:

a. Write on one side of the paper only.

b. Write without breaks, *i. e.* do not begin a new sentence on a new line. When you want to begin a new line or paragraph at a given word, place before it in your MS. the sign ¶.

c. Draw a line along the margin of such paragraphs as should be printed in smaller type—for instance, all that is clinical history in reports of cases, etc.

d. Words to be printed in *italics*, should be underscored once, in SMALL CAPITALS twice, in LARGE CAPITALS three times.

4. Authors may receive proofs for revision if they will kindly return them without delay. We beg however to remind our contributors that changes in the copy are equivalent to resetting, causing so much additional expense. We therefore request them, to make, if possible, no alterations at all in their MSS., or, at least, to limit these to what is of essential importance.

CONTENTS OF VOLUME XXVII., NUMBER 4.

PAGE

1. Statistical Report of the Ear Patients Treated during the Years 1893–1896 Inclusive. By Prof. **Bezold**, of Munich. Abridged and Translated by Dr. JULIUS WOLFF, New York 309

2. On the Functional Examination of the Ear. With an Exhibition of Bezold's Continuous-Tone Series. By **Herman Knapp**, M.D., New York 325

3. Hemorrhage Following Tonsillotomy. By **C. Zimmermann**, M.D., Milwaukee, Wisconsin 335

4. Sinus Disease of Otitic and Rhinitic Origin and General Infection; Central Deafness in Suppurative Affections of the Cranial Cavity. By Dr. **H. Preysing**. Translated by Dr. ARNOLD H. KNAPP, New York 341

5. Report of the Transactions of the American Otological Society at its Meeting July 19, 1898. By **Herman Knapp**, M.D. . . . 355

   I.—A Case of Double Mastoid Disease, Presenting Symptoms of an Intracranial Complication; Operation; Recovery. By Dr. Gorham Bacon, New York, 355.

   II.—A Case of Sinus-Thrombosis; Operation; Recovery. By Dr. J. E. Shephard, of Brooklyn, 357.

   III.—Three Specimens of Suppuration of the Labyrinth, Two of them Producing Abscesses of the Cerebellum; Operations. By Dr. J. Orne Green, of Boston, 357.

   IV.—Blood-Clot in Mastoid Operations. By Dr. C. J. Blake, of Boston, 358.

   V.—Case of Abscess in Temporo-Sphenoidal Lobe; Autopsy. By Dr. E. Grüning, New York, 358.

   VI.—How the Intracranial Pressure can be Utilized to Stop Hemorrhages in Accidental Wounding of a Sinus or an Artery. By Dr. C. J. Blake, 358.

   VII.—The Functional Examination of the Ear; with Demonstration of Bezold's Continuous-Tone Series. By Dr. H. Knapp, 359.

   VIII.—Tuning-Fork Reactions in Affections of the Sound-Conducting Apparatus. By Dr. H. A. Alderton, Brooklyn, 360.

   IX.—Trephining of the Stapedial Footplate for Otitis Media Sclerosa. By Dr. H. A. Alderton, 361.

   X.—Remarks upon the Treatment of Otomycosis by the Insufflation of Boracic Acid and Oxide of Zinc. By Dr. Theobald, of Baltimore, 361.

   XI.—Extradural Abscess; Operation; Death. By Dr. Robert Lewis, Jr., of New York, 362.

6. Systematic Report on the Progress of Otology during the First Quarter of the Year 1898. Arranged by Dr. **A. Hartmann**. Translated by Dr. ARNOLD H. KNAPP 363

7. Book Notice 395

   The Year-Book of Treatment for 1898.

ARCHIVES OF OTOLOGY.

STATISTICAL REPORT OF THE EAR PATIENTS TREATED DURING THE YEARS 1893–1896 INCLUSIVE.

By Prof. BEZOLD, Munich.

Abridged and Translated by Dr. Julius Wolff, New York.

DURING the years 1893 to 1896 inclusive 5327 ear patients were treated, representing 6056 ear diseases These were divided among the two sexes as follows:

Male, 56.2 %; female, 43.8 %; whereas Bürkner found that among the ear patients the proportion of men to women was as 6 to 4.

The various parts of the ear were affected as follows:

External ear with tympanic membrane, 22.8 %; middle ear, 63.2 %; inner ear, 14 %.

The distribution of the diseases among the two sexes was:

	Male.	Female.
External ear (including tympanic membrane)	55.6 %	44.4 %
Middle ear	55.7 %	44.3 %
Inner ear	59.7 %	40.3 %

In Table I. the author classifies the above patients, 2135 (40 %) of whom were seen in private and 3192 (60 %) in public practice.

In Table II., which is here omitted, the results of Table I. are compared with those for the years 1890–1892 and with the data contained in the *Klinische Jahrbücher*, i.–v. (according to Kruschewsky).

The statistics of the author's practice from the year 1872 to 1892, as well as a detailed report of the years 1890–92, with remarks, are to be found in his highly valuable and

widely known monograph, *Rundschau über den gegenwärtigen Stand der Ohrenheilkunde* (*Review of the Present Position of Otology*), Wiesbaden, 1895. It contains 196 large octavo pages, with extensive critical, historical, pathological, and therapeutic comments, to which the present report is a supplement.

TABLE I.

CLASSIFICATION OF EAR PATIENTS FOR 1893–1896.

External Ear and Surroundings.

Parotitis	5	
Affections of inferior maxillary articulation	13	
Glandular swelling in the retro-maxillary fossa	2	
Tumor in the retro-maxillary fossa	4	
Gumma of mastoid process	1	
Gravitation abscess after furuncle of the meatus	2	
Syphilitic caries of the parietal bone	1	
Emphysema of the temporal region	1	
Erysipelas of the auricle and surroundings	8	
Congenital fistula of the ear	1	
Injury of the auricle	3	
Freezing of the auricle	3	
Abscess of the auricle	1	
Othæmatoma	3	
Perichondritis of the auricle	1	
Arthritic deposits in the helix	1	
Ulcer of the auricle	1	
Herpes zoster of the auricle	1	
Erectile tumor of the auricle	1	
Scar on the auricle	1	
Eczema of the auricle and of the meatus	68	1.3 % of all ear patients.

Congenital atresia of the meatus and rudimentary auricle.....	1	0.02 %	of all ear patients.
Foreign body in meatus.....	69	1.4 %	" " "
Supposed foreign body in meatus.	4		
Cerumen closing the meatus....	711	13.3 %	" " "
Traumatism of the meatus.....	15		
Fracture of the bony meatus...	2		
Pruritus of the meatus.....	23	0.4 %	" " "
Furuncle of the cartilaginous meatus.....	185	3.5 %	" " "
Otomycosis of meatus.....	24	2.1 %	" " "
Otitis externa crouposa.....	13		
Other forms of otitis externa diffusa	74		
Abscess of the meatus.....	1		
Necrosis of the wall of the meatus.....	2		
Condylomata lata of the meatus	2		
Verruca of the cartilaginous meatus.....	3		
Polyp of the meatus.....	3		
Exostoses and hyperostoses of the meatus.....	54	1.0 %	" " "
Tumor of the wall of the meatus	1		
Cicatricial stenosis of the meatus	3	Sum of the diseases of the tympanic membrane, 1.3 % of all ear patients, of which 0.5 % belong to traumatic rupture.	
Cicatricial atresia of the meatus.	3		
Traumatic rupture of the tympanic membrane.....	24		
Burns of the membrane with hot water.....	2		
Burns of the membrane with caustics.....	1		
Extravasation of blood into the membrane	6		
Hyperæmia of the membrane....	1		
Myringitis chronica.....	9		
Chalky deposits in the membrane, with normal hearing....	7		
Atrophy of the membrane, with normal hearing.....	17		

Total number of the diseases of the external ear	1384	22.9 % of the 6056 ear diseases,
of which	180 (13.0 %)	were children (up to 15 years),
"	1204 (87.0 %)	" adults,
"	55.6 %	" men,
"	44.4 %	" women.

Middle Ear.

Injury of the sound-conducting apparatus	6	
Simple obstruction of the tube	221	6.8 % of all ear patients.
Obstruction of the tube with accumulation of serum	71	
Obstruction of the tube with atrophy of the drum-membrane	62	
Undue patency of the tube	6	
Otitis media simplex acuta	459	12.2 % " " "
Otitis media simplex subacuta	189	
Otitis media simplex chronica with retraction of the drum-membrane	107	10.1 % " " "
Otitis media simplex chronica without retraction of the drum-membrane	258	
Dysacousis of uncertain cause	172	
Otitis media purulenta acuta	391	8.4 % " " "
Otitis media purulenta acuta with empyema and phlegmon of mastoid process	55	
Otitis media purulenta chronica without complications	484	18.7 % " " "
Otitis media purulenta chronica with hypertrophy and polyps	210	
Otitis media purulenta phthisica	44	
Otitis media purulenta chronica with perforation, or hypertrophy in the region of Shrapnell's membrane	54	
Proliferation of epidermis in the cavity of the middle ear (cholesteatoma)	167	
Caries and necrosis of the middle ear	37	

Sequelæ of otitis media purulenta with remaining perforation	236	11.1 % of all ear patients.
Sequelæ of otitis media purulenta with healed perforation	333	
Sarcoma of the middle ear	1	
Otalgia with normal hearing	242	4.5 % " " "

Total number of the diseases of the middle ear.....3825 } 63.2 % of the 6056 ear diseases.

of which 944 (24.7 %) were children (up to 15 years),
" 2881 (75.3 %) " adults,
" 55.7 % " men,
" 44.3 % " women.

Inner Ear.

Congenital (?) defective hearing with defective speech	28	0.5 % of all ear patients.
Deaf-mutes, congenital (?)	17	0.3 % " " "
Deaf-mutism after injury	1	
Deafness and deaf-mutism after meningitis	21	0.4 % " " "
Hardness of hearing after meningitis	2	
Deaf-mutism after convulsions	3	
Deafness and deaf-mutism after scarlet fever	5	0.09 % " " "
Deafness and deaf-mutism after mumps	5	0.09 % " " "
Deaf-mutism with congenital syphilis	2	
Deaf-mutism with perforation of the tympanic membrane	1	
Subjective noises without visible cause and with normal hearing	207	3.9 % " " "
Ménière's symptoms with normal hearing	7	0.1 % " " "
Acquired nervous hardness of hearing	402	7.5 % " " "
Acquired deafness with normal		

appearance of membrana tympani, in part combined with hardness of hearing on the other side	135	2.5 % of all ear patients.
Necrosis of the labyrinth	3	0.06 % " " "
Central hardness of hearing	3	0.06 % " " "
Hallucinations (hearing of voices)	2	0.04 % " " "
Hysterical hardness of hearing	3	0.06 % " " "

Total number of diseases of the inner ear ..... 847 } 14 % of the 6056 ear diseases,

of which 87 (10.3 %) were children (up to 15 years),
" 760 (89.7 %) " adults,
" 59.7 % " men,
" 40.3 % " women.

Total number of diagnosticated ear diseases 6056

of which 1211 (20.0 %) were children (up to 15 years),
" 4845 (80.0 %) " adults,
" 56.2 % " men,
" 43.8 % " women.

Total number of ear patients ... 5327

of which 1031 were children (up to 15 years),
" 4296 " adults.

The following additional cases were recorded:

No diagnosis	19
Normal	89
Simulation and aggravation	12
Facial paralysis with normal hearing	7
Aphasia with normal condition of the ear	1
Disease of the nose and naso-pharynx without affection of the ear	101

The preference which the scleroses have for attacking the female sex has for years been accentuated by the author and has been looked upon by him as a characteristic peculiarity of this disease, being clearly shown by all of his previous statistics. During these last seven years again, two thirds of all scleroses (66 ⅔ %) affected the female sex.

A similar relation is shown by otalgia, which in 64.0 % of the cases was found in women, in 1890–92 there being 62.2 %,

and in 1893–96 65.0%. *These figures warrant us to class otalgia also among the diseases which with marked preference attack the female sex.*

[Whereas the other remarks of the author on the affections of the outer and the middle ear are clearly enough presented by the statistical report, his remarks on the affections of the inner ear deserve to be translated in full.]

The increase in the "acquired nervous hardness of hearing" in this report is explained by the fact that the author has extended the boundaries for the diagnosis of this condition beyond those in the previous reports.

Whereas formerly, in making the differential diagnosis between nervous hardness of hearing and sclerosis, he relied upon the well-known group of the functional symptoms, viz., shorter duration of bone-conduction, a positive Rinne test, and preservation of the lower boundary of tone-perception through the air, he has been able, in the course of time, to observe a number of otherwise characteristic affections of the inner ear which showed a more or less extensive *defect in the lower boundary of hearing.*

These defects are, however, less frequent than those at the upper end of the tone-scale, nor can they be localized in the inner ear with as much certainty as when perception is missing for a considerable range at the upper end; for it is difficult to determine with certainty whether at the same time the bone-conduction for these lowest tones is lost, on account of the strong concussion of the head which accompanies them. When, however, besides this gap in the hearing of low tones by air-conduction, there is shortening of the bone-conduction for the middle parts of the scale (A to a'), and in addition the Rinne test is clearly positive, the author, after having become more closely acquainted with this form of disease, no longer hesitates to consider it as a pure affection of the inner ear.

The occurrence of such defects was made *a priori* probable by the Helmholtz theory; for there is no reason why an isolated focus of disease should not occasionally develop in the cupola of the cochlea as well as in the beginning of its lowest turn. Experience has proved to the author in no in-

considerable number of cases the correctness of this assumption. Even as late as the years 1890–92, all such cases were classed by him under the indefinite diagnosis "Dysacousis," whereas they were counted in the last period among the cases of "nervous hardness of hearing."

Not only the upper and lower ends but also the *middle portions* of the tone-scale can, as one would expect, be lost to hearing. But when defects exist in these portions the power of hearing speech is at the same time more or less completely lost, and therefore these cases were classed under "deafness."

Among "uni- and bilateral deafness" were classed those cases in which the conversation voice could not be heard with either ear, or when the affection was unilateral, in which the voice whispered into the bad ear, was heard equally poorly when this ear was left open as when it was closed (Dennert-Lucae test). The actual existence of unilateral deafness was further verified by testing with the unclamped tuning-fork a′ with air-conduction. As has been shown by the author's studies on "Necrosis of the Labyrinth,"[1] this tuning-fork is heard on the affected side in unilateral deafness, either for a very short time only, even when most strongly sounded, or else it is not perceived at all.

The higher we go in the scale above this a′, the less can we localize the tone-perception in the afflicted ear if the other ear is more or less intact. In determining whether there is any hearing at all left for the upper parts of the scale, the only criterion in one-sided deafness is the *length of time* required for the high tuning-forks to die out *in air-conduction* when held next to the ear to be tested. The value of this tone a′, which lies in the middle of the tone-scale, for the determination of unilateral deafness, does not consist merely in its enabling us to isolate tone-perception to the ear tested, but also in the fact that it forms the lower boundary of that portion of the range within the once-marked and the twice-marked octaves, the presence of which has shown itself, in the course of the author's investigations

[1] These ARCHIVES, vol. xxvii., No. 2, and *Zeitsch. f. Ohren.*, vol. xxx.

on deaf-mutism,[1] to be indispensable for the understanding of speech.

Deafness to speech, even when slight remnants of hearing exist for one or another series of tones, still forms the most serviceable boundary line between the diagnosis of "nervous hardness of hearing" and "deafness," because in unilateral deafness the only way to exclude the good ear from participating in the hearing of the upper portion of the tone-scale is by the laborious process of testing the duration of hearing.

The number of cases of "deafness with normal appearance of the drum-membrane," limited in the above manner, amounted to 2.5 % during the last period.

The Influence of Age.—Whereas a number of diseases of the inner ear are either congenital or acquired in childhood through infectious diseases, at least in the vast majority of cases the "subjective noises with normal hearing" (2.3 % children, 97.7 % adults), as well as the "acquired nervous hardness of hearing" (2.6 % children, 97.4 % adults), are conditions found almost exclusively in adults.

Subjective noises are, as is well known, rarely mentioned by children, even when manifest changes in the ear exist.

The almost exclusive occurrence of "acquired nervous hardness of hearing," etc., among adults will readily be understood when it is considered what are the causes of its occurrence, namely, detonations, noisy occupations, syphilis, traumatism, and senile degeneration.

"Acquired deafness" is found somewhat more frequently in early life, 7.9 % of the cases being children and 92.1 % adults. This disease, if occurring in childhood, is usually unilateral, and probably is caused, in most cases, by overlooked infectious diseases, especially mumps, injuries to the skull, and even hereditary syphilis; the last form, however, as a rule, is bilateral.

One-Sidedness and Double-Sidedness.—The "subjective noises" were noticed in two thirds of the cases on one side only, and in one third of them on both sides; but it is difficult for many patients to say definitely whether the sounds

[1] *On the Hearing of Deaf-Mutes*, p. 121, Wiesbaden, J. F. Bergmann, and *Zeitsch. f. Ohrenheilk.*, vol. xxx., p. 217.

are confined to one ear, or whether they are heard in both.

The cases of "hardness of hearing, deafness, or deaf-mutism after meningitis" were in 95 % of the patients bilateral, whereas when following "mumps" 77.8 % were unilateral.

"Acquired nervous hardness of hearing not following meningitis and mumps" was in almost four fifths of the cases (79.1 %) bilateral, whereas "sclerosis of the sound-conducting apparatus" could be recognized on both sides in as many as 86 % of these cases.

"Deafness" in the limited sense mentioned above was found on both sides in 87.7 %, and one-sided in only 12.3 %.

It seems natural to assume that the same causes which underlie the diseases which give us the picture of "nervous hardness of hearing," as a rule, also underlie those which lead to deafness for speech, and that "deafness" represents only a more intense form of these same diseases; but the author's statistics show that of the cases of "nervous hardness of hearing" 69.4 % were males, while of the "scleroses of the sound-conducting apparatus" 66.6 % were in female patients. These figures seem to indicate that the above assumption is at least not universally correct, which surmise is strengthened by the following observations.

There is a certain though small number of cases of unilateral deafness for speech in which the author was able by functional examination to establish the presence on the other side of diminished hearing, together with the characteristic symptoms of fixation of the sound-conducting apparatus. He also found gaps *within* the upper portion of the gamut accompanying the otherwise well-marked picture of sclerosis. The upper *end* itself is, as we know, missing in quite a number of these cases. We need not wonder at the simultaneous occurrence of these changes, undoubtedly situated in the inner ear, and sclerosis, when we bear in mind the pathological anatomical changes which, as the author has shown by five post-mortem examinations of temporal bones, are at the base of this affection,[1] and which have also been seen

[1] 1. *Aerztliches Intelligenzblatt*, 1885, No. 24. 2. A case of anchylosis of the

by others, especially Politzer.[1] The anchylosis of the base of the stapes in this disease is accomplished by an ostitis of the capsule of the labyrinth in the neighborhood of the pelvis ovalis. When the inflammatory process in the bone is not limited to this region it may reach the wall of the cochlea, as was seen by Scheibe and the author in their specimens and illustrated by them in the *Zeitschr. f. Ohrenh.*, vol. xxiv. (these ARCHIVES, vol. xxiii., p. 48). In consequence of the above-named observations on the living and on the dead, the author has come to the positive conclusion that this process can, even though this be the exception, advance as far as to cause deafness for speech. A case of this kind was observed by the author and reported in detail by Werhovsky.[2]

The majority of Politzer's autopsies were cases in which deafness had existed during life. However, his patients were inmates of a home for the aged, and the hardness of hearing had existed with all of them for a large number of years.

After what has been said above, the larger number of females in "acquired deafness" than in "nervous hardness of hearing," which can be recognized not only from the above compilation, but also from all of the author's former reports, can be explained by the fact that *deafness for speech may be brought about not merely by changes which are confined exclusively to the nervous apparatus, but also by the final stages of processes which first cause an anchylosis of the base of the stapes.*

In order to explain the relative participation of the two sexes in "deafness," it is not necessary to have many cases of the latter, since, as we have seen, sclerosis, and probably more particularly its gravest forms which lead to deafness for speech, occur much more frequently among women than among men. In connection with the above, it is of interest

stapes. *Zeitsch. f. Ohrenh.*, vol. xxiv., and ARCH. OF OTOLOGY, vol. xxiii., No. 1. 3. A further case of anchylosis of the stapes. *Zeitsch. f. Ohrenh.*, vol. xxvi., and ARCH. OF OTOLOGY, vol. xxv., No. 1.

[1] On primary disease of the bony labyrinth-capsule. *Zeitschr. f. Ohrenh.*, vol. xxv., and ARCH. OF OTOLOGY, vol. xxiii., No. 4.

[2] Examination of the duration of hearing, etc. *Zeitsch. f. Ohrenh.*, vol. xxviii., and ARCH. OF OTOLOGY, vol. xxv., No. 2.

to note that among Politzer's reported autopsies six were performed on women and one on a man.

Clinically, however, we are able only in exceptional cases to follow up the scleroses which we usually observe in middle-aged patients so far as to find that the hardness of hearing actually reaches deafness for speech. In spite of the above exceptions we are, therefore, able, with a clear conscience, to extend to these patients, in addition to our admission of helplessness, the comforting assurance that in all probability at least a portion of their hearing will remain.

Results of Treatment.

As in his former reports, the author summarizes the results of the most important ear diseases, namely, the acute and chronic middle-ear suppurations.

The therapeutic procedures employed by the author are too well known from his "Review" and his former reports to require detailed repetition, and during the past four years he has not felt called upon to deviate from them in any particular.

As has been his habit in former reports, the author again draws these last figures only from his private practice. His reason for this limitation is that the dispensary patients attend too irregularly, and often soon remain away altogether, thus rendering it impossible to follow up regularly the results of our therapeutics, whereas, on the other hand, private patients are much more reliable in this respect.

The frequency as well as the nature of the operative interference required in the various diseases can best be recognized from the summary of the operations during the last four years, which is given at the end.

I. Among 332 cases of *acute* suppuration of the middle ear in private practice

There were healed with closure of the drumhead perforation	243 or	73.2 %
There were improved with cessation of secretion but persistence of perforation	8 "	2.4 %
The secretion continued in spite of prolonged		

treatment in	4 or	1.2 %
There were seen only once, or a few times	74 "	22.3 %
There died	3 "	0.9 %

II. Among 870 cases of *chronic* suppuration of the middle ear

There were healed with closure of the drumhead perforation	22 or	2.5 %
There were improved with cessation of secretion but persistence of perforation	455 "	52.3 %
The secretion continued in spite of prolonged treatment in	124 "	14.2 %
There were seen only once, or a few times	267 "	30.7 %
There died	2 "	0.2 %

In addition to the above 5 deaths in private practice, there must be added from the patients of the hospitals and dispensaries for the years 1890–96, 6 deaths in 465 acute middle-ear suppurations and 9 deaths in 923 chronic middle-ear suppurations.

The complications emanating from the middle ear in these 20 fatal cases were:

Facial paralysis	in	4 cases
Deafness	"	9 "
Subperiosteal abscess in the external neighborhood of the ear	"	5 "
Extradural abscess and pachymeningitis externa	"	11 "
Fresh or old sinus-thrombosis and phlebitis	"	9 "
Metastatic foci in the lungs, spleen, and kidney, *without* sinus-phlebitis	"	2 "
Leptomeningitis (twice circumscribed)	"	7 "
Single or multiple brain-abscesses	"	8 "

of which 4 cases were abscesses in the temporal lobe (2 single and 2 double), 2 abscesses of the cerebellum, 1 an abscess of the occipital lobe, and 1 multiple abscess of the cerebrum and cerebellum (besides scarlet fever).

In 5 cases it is doubtful whether the ear disease was really the cause of death, inasmuch as it was accompanied twice by severe scarlet fever, once by acute miliary tuberculosis, and once by severe influenza-bronchitis, and in one case the

death of the patient was only reported half a year after his departure from the hospital.

In the remaining 15 cases the autopsy proved conclusively that death was directly dependent upon the affection of the ear.

The author hopes to be able to publish the autopsies in a later paper.

During the period 1890–96 inclusive, the middle-ear spaces were opened in 160 cases, the cranial cavity being opened in some at the same time.

It must be stated, however, that not a small number of these cases was sent from out of town in a condition which necessitated immediate operation. Among an equally great number of patients coming from a certain territory alone the number of operations would naturally be much smaller.

Of these 160 cases of opening of the middle-ear spaces, 12, or 7.5 %, died. The majority of the fatal cases came under observation at so late a stage that the prognosis was from the first rather hopeless.

The mortality in private practice for the 332 cases of acute suppuration of the middle ear, observed during the years 1890–96, was 3, or 0.9 %, and for the 870 cases of chronic suppuration 2, or 0.2 %.

The *mortality* among the ear patients in the *dispensary* and *hospitals* was somewhat higher.

During the same period there were among 465 cases of acute middle-ear suppuration 6, or 1.3 %, deaths, and among 923 chronic suppurations, 9, or 1.0 %, deaths.

In the *total number* of the 797 *acute diseases* observed during 1890–96, there were, accordingly, 9, or 1.1 %, deaths; in the 1793 *chronic suppurations* 11, or 0.6 %, deaths; and, finally, in the 2590 *acute and chronic suppurations* of the middle ear *together* there were 20, or 0.8 %, deaths.

The author concludes the report with a *review of the operations performed on the 5327 ear patients treated during the 4 years, 1893–96.*

Paracentesis of the drumhead..... 186
Viz.: for acute purulent otitis media with empyema of the mastoid..... 100

for purulent otitis media chronica	1	
for simple acute and subacute otitis media	58	
for affections of the Eustachian tubes	27	
Removal of granulations and polypi with snare, spoon, etc		226
Viz.: for acute purulent otitis media with empyema of the mastoid	21	
for chronic purulent otitis media	122	
for perforation of Shrapnell's membrane	18	
for cholesteatoma	53	
for caries and necrosis	9	
for polyps of the external meatus with normal middle ear	3	
Extraction of the hammer		16
Viz.: for chronic purulent otitis media	7	
for cholesteatoma	7	
for caries and necrosis	2	
Extraction of the hammer and anvil		4
Viz.: for chronic purulent otitis media	1	
for caries and necrosis	3	
Extraction of the stapes for chronic purulent otitis media		1
Wilde's incision for acute purulent otitis media with empyema of the mastoid		1
Opening of the mastoid after Schwartze		63
Viz.: for acute purulent otitis media with empyema of the mastoid	56	
for chronic purulent otitis media	2	
for caries and necrosis	5	
Opening of the mastoid and removal of the posterior wall of the meatus, after Zaufal		33
Viz.: for chronic purulent otitis media	1	
for perforation of Shrapnell's membrane	2	
for cholesteatoma	20	
for caries and necrosis	10	
Removal of adenoid vegetations from the naso-pharynx		118
Viz.: for acute purulent otitis media with empyema of the mastoid	6	
for chronic purulent otitis media	3	
for cholesteatoma	1	

for simple acute and subacute otitis media.....	8	
for affections of the Eustachian tube.....	83	
for causes not connected with the ear.....	17	
Tonsillotomy.....		15
Viz.: for acute purulent otitis media with empyema of the mastoid.....	1	
for simple acute and subacute otitis media.....	2	
for affections of the Eustachian tube.....	7	
for causes not connected with the ear.....	5	
Removal of nasal polypi and hypertrophies for causes not connected with the ear.....		10
Total number of operations.....		673

ON THE FUNCTIONAL EXAMINATION OF THE EAR. WITH AN EXHIBITION OF BEZOLD'S CONTINUOUS TONE SERIES.[1]

By HERMAN KNAPP, M.D., New York.

THE subject of my communication has been prompted by Bezold's recent paper on the "Determination of One-Sided Deafness, with Six New Cases of Necrosis of the Labyrinth," published in the ARCHIVES OF OTOLOGY, vol. xxvii., 1898, p. 158, which contains an irrefutable proof of the still disputed fact that an ear without a cochlea cannot hear. Bezold's demonstration, a triumph of long-continued painstaking labor, impressed me so forcibly that I think the examination of the whole range of audition will for the organ of hearing prove as important as is the examination of the field of vision for the organ of sight.

To consider the subject in connection, I would beg leave to touch briefly on well-known topics. A complete functional examination of the ear has to determine the three qualities of sound: intensity, pitch, and clang-tint.

The **examination of the intensity of sound** determines the *sharpness of hearing*, for which we use (1) the *watch* and different kinds of acoumeters, and (2) *the human voice.*

The watch and other instruments with ill-defined sounds were formerly thought to be particularly appropriate for determining the hearing power of noises. During the last years, since by the investigations of Barth and others it has been ascertained, acceptably to almost all otologists, that a noise is composed exclusively of musical sounds, though not

[1] Read in abstract at the meeting of the American Otological Society, held at New London, July 19, 1898.

so easily analyzable as those of tones, the acoumeters have lost credit in favor of the human voice; yet they are serviceable and, on account of their convenience, likely to continue being generally used.

In determining the *acuteness of hearing*, we want to find the minimum intensity of sound a given ear is capable of perceiving. In testing with instruments of an invariable loudness, the acuteness of hearing is proportional to the square of the greatest distance at which an ear can perceive their sounds. In this country we have long been accustomed to express this value by a fraction, the numerator of which denotes the distance at which the examined ear hears the test instrument, and the denominator the distance at which a normal ear would hear it. Other modes of notation may be desirable for particular cases, for instance the graphic (percentage) method of Hartmann, but I have heard of none that is so convenient and at the same time so accurate as ours which expresses the patient's hearing power in a fraction of the normal, just as all the world expresses the acuteness of vision. Our notation of the acuteness of hearing would also be universally adopted if there were so easy and uniform a means of testing hearing as are Snellen's test types. But if, in otology, we cannot have the best test, we must take the best we can, and that is, by common consent, the *human voice.* I need not go into details, but a few remarks I beg to make.

Is it better to use whispering or louder voice? I think we have to use both; loud voice if the patient is so hard of hearing as to understand no whisper. As regards the normal hearing distance of whispering or ordinary voice, this is a subject which every examiner has to determine for himself individually, as it depends on the strength of his own voice and the conditions of his surroundings. This is a personal matter, and when an aurist has once determined it, he will make all his entries on the same basis; they will be comparable with one another, and give just as reliable an account of the accuracy of his examination as the reports of his own cases are in other respects. We must, from time to time, verify our former standard. Just as a watch in the course

of years has a weaker tick, by smoothening of its gear, so a man's voice is apt to get weaker with advancing years.

As regards test words, I am accustomed to take them from the most diversified objects, so as to give patients no clew by guessing. Some, for instance Bezold, use numerals exclusively. The patient expects them and makes bold guesses which sometimes are correct. If I say "Washington," and the patient, in repeating, says "forty-one," I know in which way my predecessor had examined him. We must make allowances also for foreigners, and for the peculiarities and imperfections in our own enunciation.

Of great value is the **tuning-fork test.** It is used, however, not so much to determine the acuteness of hearing, as the *range of audition*, the *pitch of sound which the human ear is capable of perceiving*, not its intensity.

As a subject of transition between the examination of intensity and pitch of sound, let us consider how we can detect *one-sided deafness.* This is not so easy as to detect one-sided blindness. The sound waves passing through air, liquids, and solids, and not only in straight but also in crooked lines, it is impossible to prevent them from reaching the other ear. For practical purposes I have, for years, been able to recognize one-sided deafness with sufficient accuracy by using the following tests:

1. *Dennert's* test. The patient closes the good, or, let us say, the better ear, by pressing the end of his moistened index finger snug into the ear canal. The other ear is tested with an acoumeter and the voice. Then the patient is told to stop also the bad ear up, and keep both closed. If the acoumeter and the voice are heard at the same or almost at the same distance, the inference is, that the bad ear does not add anything to the hearing power of the patient.

2. *Weber's* test (*D. V.*). A tuning-fork, C, c, c,′ or c″, is sounded on the vertex of the patient, who is then asked on which side he hears it. If he says on the side of the good ear, we stop up this ear, and if the patient then says he does not hear it at all, he is either a malingerer or he tries to correct his impression by his mind, supposing that he could not hear when the good ear is closed and the other deaf. He may

act in good faith or not. We have to repeat the experiment with some cross-questioning. If he finds out that closing of the good ear lets him hear the fork louder, but closing of the deaf ear makes no difference at all, he is deaf in one ear, but honest. If, on the contrary, he persists that closing the good ear makes him deaf, or at least hard of hearing, in the good ear too, we may, according to Moos, put him down as a malingerer.

3. A test which the present writer described in 1873 and has used ever since, in combination with the preceding ones, is the following: If we move a tuning-fork of medium pitch, say c′, up and down before the good ear, the patient hears it sound with puff-like enforcements when it passes before the meatus of the good ear; moving it then up and down before the other, deaf, ear, he will hear it evenly or almost evenly; an intelligent person may hear also slight puffs when the fork passes before the meatus of the deaf ear. The reason of this is that the sound waves, reaching the good ear through the head, strike it more directly and with greater force when passing through the canal of the deaf ear than through the skull. This can be proven if we let the patient stop the meatus of the bad ear. He then hears the fork no longer in puffs, but evenly.

To detect real and simulated one-sided deafness, a forked elastic tube has been used by Coggin,[1] E. Bloch,[2] and others. The free ends of the tube are placed from behind into the patient's ears; the other ends are connected with a curved glass-tube, on which a tuning-fork is placed. If one ear is deaf, the sound of the fork can be heard only in the other. If the tube leading to the latter is noiselessly stopped, no sound at all is heard; but when the other tube is stopped, the sound, going wholly into the good ear, is heard enforced.

The determination of one-sided deafness has its importance not only by establishing the fact, for instance, after mumps, to give the patient a competent opinion as to the

[1] Coggin, these ARCHIVES, VIII., 177.
[2] E. Bloch: "Die Ermittelung einseitiger completer Taubheit." *Zeitsch. f. Ohrenhke.*, xxvii., p. 267, 1896.

uselessness of therapeutic trials, but also to guide our steps when radical operations are indicated. To illustrate this by an example:

At the end of June, 1898, a young man was brought to me by his physician. His right ear had suffered from purulent otitis since childhood, and had been operated on three times, the last time, two months previously, by an extensive mastoid opening. There was a large granulating wound in the mastoid, which reached high up. The tymp. memb. was gone, and granulations and bare bone could be felt at the bottom of the middle ear. The probe could be introduced under the lateral wall of the attic, up and considerably backward. Temperature 100°, headache, dizziness, etc.

The left ear was healthy, and hearing almost normal. The right ear was totally deaf, according to the above three tests, of which the last came out very definitely. I made the diagnosis of caries of mastoid, tympanum, and attic, extending into the labyrinth. There was no facial paralysis. I stated that a radical operation should be performed, to remove all dead and diseased tissue, including the labyrinth wall of the tympanum, the lateral wall of the attic, and all whatever was diseased in the mastoid. I told the physician that the utmost precaution should be exercised, in the endeavor to be thorough, not to injure the facial nerve. The operation was difficult, and lasted two hours. The dura at the bottom of the middle cranial fossa, evidently laid bare by the previous operation, was thickened by an inflammatory grayish-white coat, imposing for cholesteatoma. The posterior wall of the mastoid was carious, but I left it alone until toward the end of the operation, for fear of accidentally injuring the lateral sinus. The tympanum was cleansed, the posterior wall of the meatus chiselled away over a probe introduced from the attic into the antrum. The antrum was small, surrounded by sclerosed bone. The lateral wall of the attic, being freely exposed, was chiselled off in its whole extent, the corroded head of the hammer and the body of the more corroded anvil were picked up, the vestibule was entered, and the whole bony part of the operative cavity carefully curetted, its walls were smoothened, then the posterior wall of the mastoid, brittle and pervaded with granulations, was removed with a sharp spoon. In doing so, the healthy-looking sigmoid sinus was exposed. After stopping the

hemorrhage, the posterior soft wall of the meatus was split longitudinally, then vertically, at its anterior end, the upper flap stitched into the upper corner of the wound, and together with the lower flap pressed against the posterior bony wall of the wound by aseptic gauze passed through the meatus out of the wound in the mastoid. There was no facial paralysis.

The patient, thus far, has made favorable recovery.

Tuning-forks have long been used as an aid to the *differential diagnosis between diseases of the conductive and nervous parts of the auditory apparatus.* Being able to examine physically, *i. e.*, otoscopically, only a part of the conductive apparatus and nothing at all of the nervous portion, the correct diagnosis of ear disease is infinitely more difficult than that of the diseases of the visual organ. The functional examination, disappointing so long on account of the combination of affections of the conductive and the nervous apparatus, has only of late acquired greater precision, even a considerable degree of certainty, by the labors of Bezold, Politzer, and others. The anatomical investigations of cases that had been examined functionally have shed a great deal of light on this difficult subject.

The **range of audition** of the human ear, according to Bezold and Edelmann's determination, extends from the subcontra C ($C^{-II.}$) with 16 double vibrations up to a^8 with nearly 55,000 v. d., comprising almost 12 octaves. Just as in the visual field of the organ of sight, defects in any part of this extensive range have been found to exist and have a good deal of significance. They are met with chiefly at the two ends of the scale, those at the lower end, the deep tones, pointing to disease of the conductive apparatus, and those at the higher end, to disease of the nerve.

It has been a difficult thing to obtain an instrument of examination capable of testing all the tones that the healthy human ear is capable of hearing. Bezold, after years of persistent labor, and aided by his able colleague, the celebrated constructor of physical instruments and apparatus at the University of Munich, Prof. W. Edelmann, has succeeded in devising and having made in most accurate manner a **continuous tone series,** of which I have the pleasure

of placing before you a copy of the newest model. It is a large and cumbersome apparatus, requiring two large boxes to contain the necessary parts.

The series from the lowest 15 v. d. (formerly 16 v. d.), C_{-II}. to c^3 (1024 v.), is furnished by a series of 10 clamped tuning-forks. Each of them contains about a quint. The intervals are marked with half-tones and the numbers of vibration. The single tones are distinguished by a remarkable uniformity of intensity in the whole series.

The upper part of the tone series from c^3 to the upper tone-limit is contained in two covered organ pipes, and the new modification of Galton's whistle by Professor Edelmann.

The three instruments are provided with devices to change the width of their mouthpiece, to "intone" them, so as to let all the tones contained in them come out with the same clearness. By this new device it is possible to adjust, by means of a micrometer screw, the mouthpiece of the Galton whistle so accurately as to pull the upper tone-limit of the normal ear in all copies at the same place of the millimetre scale. The upper tone-limit comes out much more distinctly than with the former copies and can now, without difficulty, be perceived by the patient, and at so large a distance that the simultaneous blowing sound becomes inaudible.

The progress of the availability of tuning-forks as an aid in diagnosis has been so very slow that their value in general continues to be questioned even at the present day. The greatest skeptic in this line, Dr. L. Jacobson, for many years chief of Professor Lucae's otological clinic at the University of Berlin, sums up in the second edition of his excellent text-book of otology, 1898, p. 86, his discussion on the diagnostic use of tuning-forks as follows: "*For all these reasons the results of these methods can, in my opinion, under no condition furnish sure points of information* [*sichere Anhaltspunkte*] *concerning the differential diagnosis of the seat of disease in the sound-conducting or the sound-perceiving apparatus*" (italics his). The methods he discusses are well known, namely:

1. *The duration of perception of the tuning-fork by bone-conduction* (*Schwabach's* test). He says the moment a tuning-fork stops being perceived is not easily determined,

requiring the verifying examination of a normal ear of a person of the same age as the patient. Apart from this difficulty we have to take into account that the duration of sound-perception by bone-conduction, according to Siebenmann, seems to vary not inconsiderably in persons of the same age, probably owing to differences in the pneumatic cavities of the temporal bone.

2. *Weber's* test. If only one ear is affected and the tuning-fork is constantly lateralized to that ear, we have to deal with disease in the sound-conducting apparatus on that side. If both ears are affected, the results are less decisive, but even then the test will be a valuable complement to other methods of examination. Jacobson, however, dwells on the uncertainty of the patient's powers of observation, and the changes of the result with the changes of application of the fork (Urbantschitsch) and also with the pitch of the fork. He cites Schwartze[1] as drawing conclusions from Weber's test only if at different times, before and after air-douche, with forks of different pitch, and applied to different places of the skull, the result is invariably the same. Jacobson accepts also the statement of Lucae[2]: "If in the course of a middle-ear suppuration the lateralization of the sound disappears from the diseased ear, extension of the suppuration to the labyrinth may be assumed, which renders the prognosis exceedingly unfavorable not only as to hearing but as to life."

3. *Rinne's* test receives from Jacobson the following endorsement: "Its negative result, according to Bezold,[3] proves the presence of an alteration in the conducting apparatus in all affections of both ears, if the hearing power of the one does not differ too greatly from that of the other."

We see that Jacobson himself makes extensive concessions as to the utility of the tuning-fork test in the diagnosis of the seat of ear diseases.

Let us now consider these tests in regard to the **range of audition,** the pitch of sound. There is no instrument (piano,

[1] Schwartze, *Die chirurgischen Krankheiten des Ohres*, Stuttgart, 1885.
[2] Lucae, *Die Schallleitung durch die Kopfknochen*, Würzburg, 1870, p. 48.
[3] Bezold, *Zeitsch. f. Ohr.*, "Statistische Ergebnisse über die diagnostische Verwendbarkeit des Rinne schen Versuchs," xvii., p. 153, 1887.

König's steel rods, and others) so convenient and reliable as the tuning-fork, supplemented by organ pipes or a Galton whistle. The continuous tone series lets us recognize any tone defect, small or large, and in this wise aids materially in the location and significance of ear disease.

First of all we determine the *lower and upper tone-limits*, in regard to which it is now generally believed, in the light of a goodly number of post-mortem examinations, that defects at the lower end of the scale indicate disease of the conducting apparatus, and defects in the upper, disease in the perceptive apparatus. The conducting apparatus includes the windows, especially the oval which, as has been known for many years, may be affected with degenerative diseases, fibrous and bony anchkylosis, interfering with the vibratility of the foot-plate of the stapes. The nervous diseases of the ear, in spite of excellent work done by Moos, Steinbrügge, and others, are not sufficiently known to admit of a classification based on pathology.

Bezold has made very remarkable discoveries of the preservation of single and connected tones, and series or groups of tones, in the hearing organs of deaf-mutes, resembling the islets in the field of vision of certain blind people, in particular such having suffered from retrobublar neuritis. He ascribed them at first to preserved parts of Corti's organ, but afterward found it probable that they did not result from destruction in the labyrinth, but rather from central disturbances, probably in the auditory centre situated in the temporal lobe. They seemed to be examples of genuine word-deafness. He found that the preservation of an acoustic range from b^1–g^3 was the best field for the cultivation of speech in deaf-mutes. The Bavarian Government, in building a new and magnificent Deaf-Mute Institute, has ordered that every pupil soon after his admission shall be examined by a competent aurist as to his capabilities of learning spoken language.[1]

A very brilliant use of his continuous tone series has been

[1] Bezold, "Nachprüfung der im Jahre 1893 untersuchten Taubstummen." Zweiter Nachtrag zum *Hörvermögen der Taubstummen.* J. F. Bergmann, Wiesbaden, 1896.

made by Bezold, in the examination of labyrinthless ears, of which he describes six new cases.[1] In every one the hearing power left was reflected (a faint photograph) from the other ear, which proved conclusively that the labyrinthless ear has no hearing power in itself, just as the moon has none but borrowed light. The cases in which the hearing in the labyrinthless ear is stronger, when only the good ear is closed, than when both are closed, is explained by the fact that the air in the meatus and in the cavity of the middle ear formed by the exfoliation of the labyrinth acts as a resonator in enforcing the sound.

In conclusion, I want to say that *a thorough functional examination of the ear* (or of the eye) *consumes so much time* that we can do it only as a laboratory study to educate ourselves, and in particularly important cases of disease.

In the ordinary routine practice it should never be entirely omitted, but restricted to the requirements of the case. In all cases we should test the acuteness of hearing with the watch or an acoumeter as well as with the voice in whispering or louder speech, and record the results as fractions of the normal standard.

Whenever impairment of hearing is present or imminent, the tuning-fork tests, both for air- and bone-conduction, are indispensable. Rinne's test with a fork of middle pitch, from c to a^1, is sufficient in simple cases; in complicated, especially chronic cases, be they catarrhal, adhesive, or suppurative, Rinne's test is to be supplemented by Schwabach's (measuring the duration of sound) and Weber's tests.

In advanced cases we should examine the range of audition as to pitch, especially both ends of the scale, with three forks: a lower C–A, a middle c^1–a^1, and a high one c^4.

For one-sided deafness, Dennert's, Weber's, and the present speaker's tests are sufficient, whereas in the gravest cases with tone defects in one or both ears, for instance in deaf-mutes, Bezold's continuous tone series alone will make a thorough examination possible.

[1] Bezold, "The Determination of One-Sided Deafness. Six Additional Cases of Necrosis of the Labyrinth." Supplement to article on "Labyrinth Necrosis and Paralysis of the Facial Nerve." ARCH. OF OTOL., xvi., p. 297; ARCH. OF OTOL., 1898, p. 158.

HEMORRHAGE FOLLOWING TONSILLOTOMY.

By C. ZIMMERMANN, M.D., Milwaukee, Wisconsin.[1]

A man, aged nineteen years, came to me on account of an acute exacerbation of a chronic purulent otitis media of his left ear, which, after about a month's treatment, healed with closure of the perforation and normal hearing. Soon he had a relapse with profuse mucous secretion. I, therefore, advised him, as I had done when he first came, to have his hypertrophied tonsils removed, as they produced by the cheesy accumulations in their crypts a constant irritation of his throat and predisposition to the recurrence of the ear affection. I cut the tonsils in local cocaine-anæsthesia with Blandin's knife. When the bleeding seemed to have ceased he rested a little. After a while I noticed that the left tonsil was again bleeding. Gargling with ice water being of no avail, I cauterized the cut surface with the galvano-cautery, which proved also insufficient. Then I made compression with a piece of cotton soaked in perchloride of iron. About an hour and a half had elapsed with these procedures when the hemorrhage seemed controlled. At twelve noon he left my office with the advice to send for me, or to return immediately if the bleeding should return. At 5 P.M., he came again, looked very pale, and stated that he had vomited large quantities of blood. On re-examination I found a large blood clot covering the tonsil which irritated the pharynx and made the patient vomit considerable blood repeatedly. From the lowest part of the tonsil arterial blood trickled down his throat. I then compressed this place with styptic cotton, but in vain. His pulse was rather low, and he felt weak and looked very anæmic. In order to get a better view, I removed the whole clot, and found a bleeding spot, apparently

[1] Read, by invitation, before the Fox River Valley Medical Society at Marinette, Wisconsin, April 12, 1898.

an artery, in the centre of the cut surface. Cauterization with a thick red-hot iron probe not being sufficient, the bleeding place was grasped with an artery forceps, under the kind assistance of Dr. G. D. Ladd, which controlled the hemorrhage. After the forceps were left in place for a while, the vessel was twisted and the bleeding did not recur. The patient, who was very anæmic from the loss of blood, stayed in bed for several days and made a good recovery. The discharge from his ear ceased entirely on the day after the operation.

This was my first experience of the kind, although I have removed a large number of tonsils with Blandin's knife as well as with Mackenzie's and Mathieu's tonsillotomes.

If we consult literature we also find that hemorrhage after tonsillotomy is of very rare occurrence. De Santi published a very good paper on this subject in the *Lancet*, 1894, I., p. 83, in which he gives a review of the incident literature. Capart saw but one severe hemorrhage in more than two thousand tonsillotomies. In Sajous's *Annual* of 1891, vol. iv., only nine cases of hemorrhage are recorded from a collection of twenty thousand cases. Wright has published a table of cases of hemorrhage after tonsillotomy from the records of the previous twenty-five years in the library of the Surgeon-General at Washington, which amounted to thirty-one cases. In more than one-third of them, *ice, direct pressure to the bleeding surface, or torsion of the spurting vessel was sufficient to check the hemorrhage;* in two cases the *common carotid was tied;* in three the patient was hæmophilic; in two vomiting set in and stopped the hemorrhage; and in another case, when styptics, direct pressure, and Paquelin's cautery had been used without success, the stump of the tonsil was tied *en masse* and the bleeding ceased. Many of these cases were very severe and *two out of thirty-one had a fatal issue;* in one of them, a child aged eight years, there was an abnormally distributed internal carotid artery. Semon saw his first case of hemorrhage, after several hundred tonsillotomies, in a man, aged forty-six, with chronically enlarged tonsils; the bleeding was stopped by direct digital compression. He had used Mackenzie's tonsillotome, as well as in another case, in a female, aged twenty-three, in which an uncontrollable

hemorrhage followed from the whole surface of the tonsil. Tannic acid and gallic acid, ice, direct digital pressure, all failed, and the bleeding eventually ceased spontaneously in about two and a half hours, when the patient was put to bed and kept at rest. Billroth attributed the bleeding in his case to a wound of the faucial pillars by his bistoury. Downie checked a hemorrhage after tonsillotomy, performed with Mackenzie's tonsillotome, by applying the actual cautery to the bleeding point. De Santi observed three cases, one in a girl of fifteen, another in a child of eight years, all operated upon with Mackenzie's tonsillotome. In the one, a large slough in the situation of the right tonsil was seen, and in the centre of it arterial hemorrhage noted, which was controlled by Paquelin's cautery; in the other case, it was arrested by ice in the mouth. Morrell Mackenzie mentions in his book on diseases of the throat that he had only once met with a case in which the bleeding appeared actually to endanger life, and Hunter Mackenzie never saw it in 230 cases.

How can the Occurrence of Hemorrhage after Tonsillotomy be Avoided?

Tonsillotomy should never be performed in certain constitutional affections, as in hæmophilic or such persons who, from various reasons, have a tendency to bleed profusely, or where there is hypertrophy of the left ventricle.

Age seems to be of some importance, as hemorrhage after tonsillotomy occurs more frequently in adults, but it has also been observed in children. Wright, *Boston Medical and Surgical Journal*, 1892, May 12th, advises to exclude the cutting operation in all patients past eighteen years of age, as it is impossible to tell, by feeling or inspection, in an adult case, what the vascular condition of a tonsil is at the plane through which the incision is to pass.

According to de Santi, the bleeding is usually traceable to some abnormality in the distribution of the blood-vessels: of the ascending pharyngeal artery, to abnormally large tonsillar artery, abnormally internal carotid, large vessel in the anterior faucial pillar, large venous plexus at the lower

and outer border of the tonsil. The tonsillar artery is a branch of the ascending pharyngeal and ascending palatine.

Zuckerkandl attributes the cause of hemorrhage after tonsillotomy to the relation of the tonsillar artery to the capsule of the tonsil. If the artery is cut in the plane of the capsule with which it is closely connected, winding around it before penetrating it, the artery cannot retract or contract, so that the formation of a thrombus and closure of the vessel is prevented.

Sometimes large vessels are seen on the surface of the tonsil, which itself may consist of erectile tissue, as Schech observed in a child, in which the tonsils almost disappeared after application of cocaine.

If there is atheroma of the blood-vessels in older persons, the vessels do not contract after being cut.

The same may occur in very solid tonsils of a fibrous structure, which may be felt with a probe. In these the walls of the blood-vessels are adherent to the surrounding unyielding tissue, and cannot collapse. But a soft surface is not always a criterion of the condition of the deeper tissue, which may be fibrous.

Tonsillotomy should never be performed in the state of acute inflammation, as there is hyperæmia, and the blood-vessels are injected and more apt to bleed.

In our case cocaine has been used, but it cannot be accused for the bleeding by the following relaxation of the blood-vessels, as its action is limited to the surface, and does not extend to the deeper vessels. Cholewa (*Monatsschrift f. Ohrenheilk.*, 1897), however, warns against its use in the operation of adenoid vegetations, as he thinks it may give rise to secondary hemorrhage.

Some claim that bleeding is more apt to occur after the use of the bistoury than of the tonsillotome. This, however, is not corroborated by literature, which shows that in most cases of hemorrhages reported the operation was done with the tonsillotome. I have removed many tonsils with the knife, which in some cases is the only instrument to be used,—for instance, in very large tonsils, which cannot be encircled by the ring of the guillotine,—and I never saw bleed-

ing of any amount except in this particular case. Of course, the anterior faucial pillar must not be cut, and the knife must not stray so far as to imperil the carotid. To be sure, the latter is safe when the tonsillotome is used. In either case the tonsil should not be pulled out too much between the faucial pillars, and *no pressure from outside should be exerted towards the instrument.*

Moritz Schmidt, Schech, Huguenin, Magnan, and others, *use now exclusively the galvano-cautery snare*, to avoid hemorrhage, but this does not insure absolute security from bleeding, there being records of several cases of severe hemorrhage resulting from its employment.

After the operation the patient should keep quiet, not travel, not use his voice, avoid alcoholics, and not eat solid food for several days.

Cases of secondary hemorrhages have been recorded in which a severe hemorrhage occurred, *e. g.*, after eating bread on the fourth day. Gargling with cold water after the operation is to be recommended, but must not be continued too long, as it may interfere mechanically with the formation of thrombi. Then it is better to keep a piece of ice in the mouth.

After the bleeding ceases, I generally dust the cut surface with iodoform mixed with tannic acid. Should the bleeding persist, Mackenzie recommends to powder the wound with a gallic and tannic acid mixture, 1 : 3, or to let the patient sip it in a watery solution. Hovell makes a stiff paste of it and rubs it with his finger into the bleeding surface. If the hemorrhage is parenchymatous from the whole surface, some recommend the application of perchloride of iron by a piece of cotton soaked in it. It forms, however, thick blood-clots, which, when the bleeding does not stop, greatly interfere with a good view of the parts, as in our case, in which the bleeding spot was hidden by the clot.

Compression, digital or with a pair of long forceps, the blades being covered with cotton or gauze, one applied to the cut surface, the other on the outside close to the angle of the jaw, and then tied together, will not be tolerated very well by the patient, although it has been reported to be suc-

cessful. The best method in persistent hemorrhage is to make a very careful examination of the cut surface, to see whether a single point is bleeding. This may be cauterized with Paquelin's thermo-cautery, or a thick probe made red-hot. The galvano-cautery at once becomes inefficient, being cooled by the amount of blood.

If cauterization is not successful, the bleeding spot is best grasped with an artery forceps, which is left in place for a while, and then torsion is made.

Butler suggested ligature *en masse*, which, however, would hardly be possible, as there is no stump to put it around, so that slipping of the ligature can scarcely be avoided. Dawbarn (*Med. Record*, December 17, 1892, p. 699) devised a purse-string ligature around the bleeding surface made with four stitches by a large semicircular needle and needle-holder. In desperate cases, ligature of the external, not common, carotid remains as the ultimate refuge.

In all cases of severe bleeding after tonsillotomy the patient ought to be kept in an erect position, so that by the resulting anæmia of the brain he is apt to faint, as a spontaneous restraint of the bleeding has been observed in cases in which an attack of syncope occurred. As mentioned before, severe hemorrhage after tonsillotomy is rare, but if a surgeon once has had such an experience, he cannot lay too much stress on the advice, before every tonsillotomy, to be thoroughly prepared to meet such an emergency effectually.

SINUS DISEASE OF OTITIC AND RHINITIC ORIGIN AND GENERAL INFECTION; CENTRAL DEAFNESS IN SUPPURATIVE AFFECTIONS OF THE CRANIAL CAVITY.[1]

By Dr. H. PREYSING (Assistant).

Translated by Dr. Arnold H. Knapp, New York.

FROM November 1, 1896, to November 1, 1897, the following nine cases of otitic and rhinitic sinus disease were observed at the Rostock Ear and Throat Clinic:

Case 1.—Suppurative Ethmoiditis after Scarlet Fever—Orbital Abscess—Phlebitis of Cavernous Sinus and Septico-pyæmia—Evacuation of the Orbital Abscess and the Ethmoid Cells—Death.

B. D., five years old, was taken ill with scarlet fever on January 26, 1897. Four days later a purulent discharge from the nose set in, and the temperature rose to 40°. On February 5, 1897, the left eye became sensitive to light and the lids œdematous. On February 9th, both mastoid processes became tender. On the following day both ears discharged, and patient was admitted to the ear clinic.

The child appeared emaciated, the lids of the left eye were œdematous. Both auditory canals filled with pus; a light reflex could be observed in the depth of each. The mastoids were not swollen nor tender. There was a hard, painful group of glands below the right mastoid process extending to the inferior maxilla. The nose contained thick muco-pus. Otherwise the child seemed healthy. In the following days the œdema of the lids increased, and the left eye protruded. The glandular swelling grew larger, and on February 15th fluctuation was apparent.

[1] From the Ear and Throat Clinic in Rostock.

The mass was incised, and pus, glandular débris, and granulations were evacuated.

The temperature had gradually returned to the normal, but on March 2d it suddenly shot up, with diarrhœa and abdominal distension, rapid pulse and respiration. The left eyeball was forced down and out, but no swelling appeared at the orbital margin except the œdema.

The protrusion of the eye increased; the fever continued high with deep remissions. As there was no evidence of pus retention in the ears, the cause for the pyæmia had to be looked for in the ethmoidal suppuration and orbital abscess. On March 6th an incision was made along the supraorbital margin to the root of the nose, the orbital contents were pushed aside, and a subperiosteal abscess evacuated; the os planum was carious, and the diseased ethmoidal cells were curetted. The frontal sinus was opened and found empty.

Though the symptoms were alleviated, the patient grew weaker, and died on March 9th. The sensorium remained perfectly free to the last. An autopsy was not permitted.

This case differs from the nine cases of fatal ethmoid disease described by Dreyfuss in his "Disease of the Brain and its Adnexa after Nasal Suppuration," as in all of that author's cases, meningitis was the eventual cause of death. In our case every sign of meningitis was wanting. From the clinical symptoms, the pyæmia evidently started from the ethmoid suppuration, complicated with an orbital abscess, in a child already weakened from scarlet fever. Systemic infection from an orbital abscess through the cavernous sinus is readily explicable from the anatomical relations.

Case 2.—Pyæmic Fever in Acute Otitis Media—Recovery after Evacuation of the Tympanic Abscess.

M. M., fifteen months old, was taken ill two weeks ago with acute otitis media of the right side and then of the left. After ten days the right ear ceased to discharge, and the temperature rose to over 40°, with anorexia, somnolence, and irritability. The child was admitted to the clinic on May 9, 1897. Temperature, 41.2°. The internal organs were found normal. The left auditory canal contained pus, and a pulsating light reflex was visible;

the right *Mt* was red and prominent. The mastoid processes were unchanged.

The right *Mt* was incised; serous fluid and blood escaped. The day following, the canal was filled with pus. Rectal temperature showed a fall of 5°, to 36.2°, on the morning of the two following days, with a rise to almost the same height in the evening. No other cause for the fever could be found than the tympanic inflammation. The discharge from both ears grew less, and the child made a rapid recovery. The temperature returned to the normal on the tenth day.

The temperature curve showed a pyæmic type with unusually pronounced daily variations. Koerner has observed a temperature decline of 4° in a few hours during otitic pyæmia; in our case the decline was 5°.

The systemic infection in this child may have occurred through the medium of a sinus phlebitis, or direct absorption from the tympanic mucous membrane. A sinus phlebitis is improbable, as there were no evidences of bony involvement, on account of the rapid fall of temperature after evacuation of the tympanic cavities and the absence of all meningeal symptoms.

Case 3.—Cholesteatoma, Sinus Thrombosis—Operation—Recovery.

P. H., age twenty-nine years, has always suffered from right-sided otorrhœa which had recently been more profuse up to one week ago. The discharge then suddenly ceased; severe pains in the head set in, with chills and fever. He was admitted on September 24, 1897, complaining greatly of pain in the head. The right auditory canal contained a large polyp; the tympanic mucous membrane was granulating. The right mastoid process was tender along the posterior margin, but was not swollen. L ear normal. Temp. 38.2°; no other symptoms of importance.

On the same evening the mastoid process was opened. The bone was found sclerosed. The sinus was encountered at a slight depth and situated far forward. The sinus was surrounded with pus, and granulations lined the bony wall of the sulcus transversus down to the jugular foramen. The discolored sinus pulsated after it was exposed for some length. The wall was covered with a grayish membrane, but no granulations. The antrum was next

exposed after Stacke's method; it was found to be small at a high level, and contained a few granulations. A fistulous tract led to the diseased sinus. The sinus was finally incised, and a soft, dark clot evacuated, followed by free hemorrhage without pulsation. The wound was packed. The patient's recovery was uneventful, except for slight jaundice during four days. On October 20, 1897, the wound was closed with Koerner's plastic and healed twenty-seven days later.

Remarks.—This was a striking demonstration of the path of infection from the antrum to the sinus.

CASE 4.—**Cholesteatoma, Sinus Phlebitis—Pyæmia—Operation—Meningitis Serosa Ventricularis Acuta—Death.**

H. G., twenty-one years old, admitted September 24, 1897. The left ear has discharged since early youth. On September 19, 1897, patient felt severe pain in the left ear which radiated to the back of the neck. Temp. 40.2°. A large quantity of pus was removed from the left ear with the syringe. The left mastoid process was tender but not swollen. On September 22d renewed chills and fever over 40°. The condition of the patient then improved and on September 24th he was transferred to the clinic. On admission the temp. was 38.3°, pulse good, cerebration good, ocular motility and pupils normal. The patient complained of occasional pain in the back of the neck. The left auditory canal led to a cavity filled with cholesteatomatous masses. An area corresponding to the mastoid vein was tender but not swollen. The right canal contained pus; the *Mt* was perforated, otherwise normal.

On the following day, September 25, 1897, the radical operation was performed on the left side. The bone was eburnated, but soft and hyperæmic at the tip. Antrum, tympanum, and canal formed a large cavity, filled with cholesteatoma extending deep towards the tip and posteriorly to the sinus. The middle cranial fossa was exposed but found healthy. The sinus was exposed; it was discolored but pulsated. There was a fistulous opening at the facial canal; on probing, the spasmodic contractions appeared in the facial distribution. The sinus wall was accidentally torn; free hemorrhage; packing and bandage.

On return to consciousness, facial paresis observed. The temperature rose in the afternoon, with the same pain in the back of

the neck. Examination of the cervical vertebræ proved negative; the spinous process of the fifth vertebra is unusually prominent, that of the fourth is deflected to one side, thickened and tender. Patellar and abdominal reflexes are feeble, but present. Internal organs normal.

The same symptoms were present on the following day; pain in paroxysms and causing the patient to cry out. The pulse was slow in comparison with the temperature, sluggish and irregular. The condition unchanged on the second day, the wound appeared clean. No disturbance of the brain functions except horizontal nystagmus on looking to the right. Deglutition difficult and imperfect. The mind is clear; no rigidity of neck. Examination of the ocular fundus could not be made. The patient grew comatose, with Cheyne-Stokes respiration; the pulse rose from 64 to 140; death at 7 o'clock.

An autopsy was not permitted, so the wound was enlarged. The sinus was not thrombosed, as far as could be observed. The cerebral convolutions were flattened, no lepto-meningitis. The base of the middle cranial fossa normal. No abscess found in the cerebellum or cerebrum; the left lateral ventricle greatly distended by a clear yellowish fluid (meningitis serosa).

From the high irregular fever and rigor, pyæmia was suspected. The wall of the sinus was found diseased but no thrombus.

In the following two days the fever continued, with pain in the neck. This we regarded as a symptom of a metastatic disease of the fourth cervical vertebra. On the third day, symptoms appeared suggestive of a further intracranial complication. Reasoning by exclusion, a cerebellar abscess seemed probable, supported by the symptom of nystagmus.

The rapid decline in the patient's condition and the uncertainty of the diagnosis made us abstain from further operation.

The post-mortem examination showed the absence of leptomeningitis and brain abscess, and the cause of death seems to have been a dilatation of the lateral ventricles, causing compression of the brain. Was this exudate due to an interference with the blood-current in the cranial cavity, or a meningitis serosa? As a closure of the lateral sinus by

artificial means (ligature of the jugular, packing in hemorrhage from the sinus), or by thrombosis, does not usually cause a ventricular hydrops, meningitis serosa seems to be most probable.

The rapidly progressive brain symptoms, occurring within forty-eight hours after the operation, presume the possibility that by the concussion during the chiselling infection was carried to the ventricles. At any rate, puncture of the left ventricle would have alone cured the patient.

CASE 5.—**Acute Suppuration in Both Temporal Bones, Presumably after Measles. Severe Pyæmia, with Multiple Joint-Metastases. Opening of Both Mastoid Abscesses, and of Three Joints. Death after Six Hours—No Autopsy.**

Prof. Koerner has published this case, in the *Zeitschrift f. Ohrenheilk.*, vol. xxx., p. 231 (these ARCHIVES, vol. xxvi., No. 3).

CASE 6.—**Thrombophlebitis of the Lateral Sinus. Purulent Leptomeningitis. Metastases in the Lungs.—Death.**

Of this case, which entered the hospital in a moribund condition, we can only give the autopsy report. This is of interest, as it gives an exact picture of the metastatic inflammations in the internal organs in pyæmia.

Autopsy.—Body of a man about thirty-five years old. The veins of the cortex are congested. The upper wall of the left lateral sinus is transformed into a yellowish, cheesy mass. The longitudinal and the right lateral sinuses contain coagulated blood. The lower surface of the left cerebellar hemisphere is covered with a purulent membrane. Puriform masses have perforated the pia and have extended beneath this membrane. The purulent infiltration continues over the upper surface of the left cerebellum. In the post. fossa near the sigmoid sulcus, the bone is carious. The ventricles are distended with clear serum. The brain is otherwise normal. The pericardium contains some clear fluid. Heart normal. The left lung is adherent to the costal pleura. In the left lower lobe, there are two fluctuating prominences about $\frac{3}{4}$ *cm* in diameter. On section these prove to be abscess cavities. Many similar abscesses are scattered over the surface of the 3 lobes on the right side. Moderate changes in the other organs.

Case 7.—Thrombophlebitis of the Right Lateral Sinus—Sepsis—Operation—Death.

M. W., twenty years old, was admitted on Oct. 18, 1897. The patient had complained of cough and fever for several weeks; a pulmonary affection was suspected. The left mastoid process became swollen, and she was sent to the hospital.

The patient is slightly jaundiced, temperature 40.2°, pulse 144–152. Pain only on coughing. She claims to see everything smoky. The mind is clear; no cerebral symptoms. Internal organs are normal. The right auditory canal is filled with pus and a large granuloma. The upper part of the right mastoid is normal, and free from pain. The tip and posterior margin are tender. The neck below is diffusely infiltrated and hard; this area extends behind the sterno-mastoid to the middle of the neck.

The mastoid process was immediately opened; the skin and periosteum bled very freely. The bone was soft in the antrum pit and near the tip, otherwise very hard and hyperæmic. Posteriorly, at a depth of 1 *cm*, a perisinuous abscess was encountered. The middle cranial fossa normal. The region of the sinus was curetted; owing to the very free hemorrhage no exact knowledge of the anatomical parts could be ascertained. The antrum filled with granulations. A track was found leading from the antrum to the perisinuous abscess. Packing. The incision was prolonged downwards, along the sterno-mastoid. Respiration during the operation was very bad, the patient did not rally, and died half an hour after the operation.

Autopsy.—October 20, 1897. No meningitis. The brain substance appears normal. No signs of abscess. The dura is unchanged except in region near mastoid antrum; the bone is bluish. The lateral sinus is ulcerated at the knee towards the bone. The neighboring bone is discolored and soft. Thrombus extends in the sinus half way back to the torcular. The thrombus is adherent to the wall and near the centre grayish green and soft. The jugular bulb is normal. The lungs show no signs of metastases. Spleen and liver enlarged.

The unusually extensive infiltration of the tissues about the occiput and the neck on the affected side is characteristic of the septic nature of the lesion (see Koerner, *Otitic Diseases of the Brain*, 2d edition, p. 94), similar to the diffuse swellings in the neck in septic diphtheria. This is the

third case of this kind which Prof. Koerner has been unable to cure by operation. According to his judgment, it is as well to leave these cases alone.

Case 8.—Thrombophlebitis of the Lateral Sinus and Pulsating Abscess of the Sinus from Cholesteatoma in a Woman Seventy-four Years of Age, after Otorrhœa of Sixty Years' Duration—Operation—Recovery.

S. B., seventy-four years old, was admitted on May 18, 1897. In her fourteenth year the left ear began to discharge, but caused her no trouble until February 8, 1897, when she was taken ill with influenza and pneumonia and remained nine weeks in bed. A few days after the onset of the pneumonia the left ear began to pain, and the discharge ceased for the first time. The pain became very severe from March 6th to 10th, with high fever, rigor, and delirium. The region about the left ear was swollen and very tender. On March 10th, there was a spontaneous discharge of blood and pus, followed by general relief of the symptoms. Some pain persisted and she came to the clinic for treatment. The patient is emaciated. She hears loud conversational voice near the right ear. Except for the pain in the ear and general weakness, there are no symptoms. The left mastoid is tender, the overlying soft parts are swollen. The upper wall of the canal is bulging; the canal contains granulations and pus. The right ear, the internal organs, and the eyes are normal. On May 19, 1897, the radical operation was performed. The bone is hyperæmic and sclerosed. The bend of the sinus is exposed at a depth of ½ *cm*; it is covered with granulations and pulsates. The antrum is situated to the inner side and extends behind the sinus; it is enlarged and filled with cholesteatomatous masses. The sinus is accidentally lacerated and pus escapes. The opening is enlarged and the sinus is further exposed. Pus but no blood appears. The antrum, middle ear, and canal are transformed into a large cholesteatomatous cavity. The bony cavity and the sinus are separately tamponed. On account of the sinus affection the wound was dressed daily. The wound cleaned itself and the secondary plastic operation (Koerner's) was made three weeks later, on June 10th. In the beginning of October the wound was healed.

This is an unusual case of intracranial complication after otorrhœa of sixty years' duration. The remarkable pulsating

sinus-abscess will be discussed at length farther on. A primary plastic operation was not feasible on account of the diseased sinus.

CASE 9.—**Healed Otitic Phlebitis of the Left Cavernous Sinus.**

A. F., thirteen years old, admitted on May 28, 1897, had suffered from otorrhœa of both ears for seven years. The discharge stopped on May 21st with high fever, rigor, and severe headache. After three days the otorrhœa began again; the symptoms were somewhat relieved, but headache, fever, and weakness remained.

On admission the temperature was 39°. The child appears very ill. The left auditory canal contains pus. The drum-membrane is swollen above, in front there is a perforation, several white shreds appear behind. The right drum-membrane has a large, dry proliferation. The internal organs are normal. The sensorium is free. There is marked deafness, and pain in the left half of the head. The pulse is 96, small and intermittent.

On May 28, 1897, the left antrum and tympanum are exposed, and the posterior wall of the auditory canal is removed. The bone is sclerosed. The granulations in the middle-ear spaces are curetted; the carious hammer and anvil are removed. The lateral sinus is exposed and found normal. Plastic.

On the following day the patient complained of diplopia; the left abducent nerve was paralyzed. Mind clear, pupils active. In the afternoon diarrhœa of typhoid character and abdominal pain set in; 7–8 small, raised roseolar spots appeared on the abdomen.

On the second day the sclera, skin, and urine showed jaundice color. Repeated vomiting. The left eyeball is distinctly prominent. Double choked disk (right more than left). The eruption had disappeared. No cerebral symptoms. The jaundice disappeared in five days. The eye symptoms improved, though after four weeks the right disk was still indistinct and the blood-vessels tortuous; the sixth-nerve paralysis was less.

On the fifth and seventh days, moderate hemorrhages from the sinus occurred in the dressings. On the sixth day the child's general condition was much improved. The temperature, which had reached 40.6°, gradually declined. The hearing was lost from the fifth to the seventh day. Four weeks later the left ear was still totally deaf, but the right ear could perceive whispering

voice. The healing of the wound progressed favorably ; a small area of necrosed bone was removed. On August 8, 1897, nine weeks after the operation, the patient was discharged healed. Whispering could then be heard

L. : twenty-two = 40 *cm* ; five = 20 *cm* ; hundred = 10 *cm*.
R. : " = 400 " " = 300 " " = 100 "

The left-sided purulent otitis had led to the inflammation of the cavernous sinus, and to a general infection simulating typhoid fever. The diagnosis of disease of the cavernous sinus is assured from the abducent paralysis, the exophthalmos, and the double-choked disk. It is difficult to define the exact method of infection of the cavernous sinus. The carotid sinus, which surrounds the carotid in its bony canal, is contiguous with the tympanum, and communicates directly with the latter. On the other hand, one of the petrosal sinuses, or the lateral sinus, may have been affected without especial signs, and conveyed the infection to the cavernous sinus.

The transient bilateral deafness is remarkable. This will be discussed farther on with a case of complete central deafness from meningitis.

CENTRAL, PARTIAL, AND COMPLETE DEAFNESS DURING INFLAMMATORY PROCESSES WITHIN THE CRANIAL CAVITY.

In Case No. 9, the intracranial inflammation, with symptoms of a phlebitis of the cavernous sinus, led to transient central deafness.

The partial deafness in this case became total on the fifth, sixth, and seventh day, although no change occurred in the ears. The complete deafness coincided with the height of the temperature. The patient was somewhat apathetic, though reacted to everything except auditory impressions, and complained about her loss of hearing. This condition is suggestive of the so-called crossed deafness, which has been repeatedly noted in abscesses of the temporo-sphenoidal lobe. A bilateral deafness is, however, more probable than the crossed deafness in these cases, as the other ear had always suppurated, had been operated upon, and bandaged.

A bilateral central deafness may even have been present in those cases which, from the mentioned causes, had only been noted on the opposite side. Oppenheim states, with justice, that a one-sided disease in the temporal lobe cannot produce a severe or a lasting deafness on the opposite side, because each auditory nerve is in relations to both auditory spheres. In brain abscess, a severe and lasting crossed deafness has never been observed; the deafness has always been transitory.

How can we then explain the transient right-sided total deafness in Case No. 9? If the right ear had previously been normal, as in the cases of brain abscess with crossed deafness, it would probably have been only partly deaf. A central deafness may have been added to the previous peripheral partial deafness. As the patient recovered, the origin of the central deafness cannot be positively ascertained. It was perhaps due to a circulatory disturbance from disease of a sinus of uncertain extent. The case at any rate shows the possibility of a central deafness in a phlebitis at least of the cavernous sinus. The case leads us to report another case observed at the surgical clinic at about the same time.

CASE 10.—**Traumatic Meningitis, with Pronounced Involvement of the Lateral Ventricles—Central Complete Deafness.**

K. J., eight years old, was admitted on April 12, 1897. Twenty-two days ago he received a kick from a horse's hoof in the left ear, which knocked him down though it did not stun him. The left ear was swollen and presented a small wound. The patient vomited a number of times, but there was no discharge from the ear and no other symptoms. In the evening of the second day the child was feverish, restless, and complained of severe headache. In the night of the third day the boy suddenly lost his hearing. He could be made to understand only by gesture or by writing. The sensorium remained clear. The evening temperature was always raised between 38° and 40°. On day before admission patient had a severe chill.

On admission: No ocular symptoms. Hearing for conversation and loud noises lost. No signs of word-deafness or word-blindness. Pain in the left ear and occiput. No paralysis. The

region of the left ear is swollen. On palpation a depression admitting the thumb occupies the temporal squama and the parietal bone. The depression is oval, and the edges are sharp.

Prof. Koerner examined the ears and found the auditory canals and *Mtt* normal. No signs of exudate in the tympana. Total deafness for speech, bells, high and low tuning-forks. No bone-conduction. The patient is perfectly bright, can read writing, answers written questions, but does not react to unexpected noises, though he perceives the commotion caused by the slamming of the door.

Probable diagnosis: Abscess of the dura or of the brain probably in the left temporal lobe. On the second day the temperature again rose with chills, and on June 14, 1897, it was decided to open the skull.

Operation.—An oval Wagner flap was formed with the base corresponding to the depression above the left ear. On dividing the integument over the posterior end of the fracture half a teaspoon of purulent fluid appeared. A piece of bone corresponding to the skin incision is reflected. The dura is normal and pulsated; at the lower part near the depressed fracture an area of yellowish red granulation tissue is visible between the dura and the bone. This is very friable and is removed. The wound is partly closed with sutures and packing.

In the following days repeated vomiting and headache. Deafness persists. On June 16th the dura is opened and the brain is punctured with a scalpel to a depth of 3 *cm*, without result. June 16th, œdema of upper eyelid. June 18th, in the lower part of the wound the dura protrudes. An incision in that region evacuated pus and broken-down brain matter. A superficial abscess cavity is found in the temporal lobe. The pus contains streptococci. June 21st, general condition worse. The temperature varies daily between 37° and 40°. Punctures of the brain, without result, are frequently repeated.

July 16th, lumbar puncture is performed. The fluid is cloudy and contains many pus cells with diplococci and cocci in chains of four, resembling more the diplococcus lanceolatus than the meningococcus intracellularis. In cultures the staphylococcus alb. and spore-containing rods like the bacillus subtilis are grown. July 17th, gradual failing, restlessness, nystagmus, spasms of the right facial nerve, and convulsions. July 27th, death.

Autopsy, July 28th.—The left temporal lobe contains a cavity

filled with 50 *ccm* of cloudy yellow fluid. The pia over the base is normal. The pia over the pons, medulla, and cerebellum opaque and infiltrated with pus. The dura behind the area of the defect from the operation is covered by a brownish membrane. Vertical section through the hemispheres discloses the lateral ventricles, distended and containing 100 *ccm* greenish flocculent fluid. The ependyma is thickened and cloudy. In the left lateral ventricle, near the optic thalamus, the brain substance is broken down. The brain shows no other marked lesion.

Pathological Diagnosis.—White softening in the left temporal lobe. Pus in the distended lateral ventricles. Leptomeningitis in the posterior fossa.

In this case the bilateral total deafness occurring after an injury to the left temporal bone is of especial interest to us. The sound-conducting apparatus seems to have been unaffected, as the drum-membranes and the middle ears were normal. An injury to the labyrinth was possible, but there were no signs of a fracture of the base, and there was no escape of blood or cerebro-spinal fluid from the ear. In addition, the deafness did not come on until the third and fourth days. Furthermore, the traumatic abscess in the left temporal lobe could not have caused the complete deafness. We must, therefore, fall back upon the bilateral meningitis in the ventricles, as the etiological factor causing a disturbance in that portion of the brain where the two auditory tracts decussate. We know from Siebenmann's investigations that this takes place in the tegmentum.

THE PULSATORY MOVEMENTS OF THE EXPOSED LATERAL SINUS AND THE PULSATING SINUS-ABSCESS.

The exposed lateral sinus often shows pulsation; this may be transmitted brain pulsation or waves of the normal Riegel's jugular pulsation recurring in the sinus. If the pulsations are transmitted by the blood-current, they show that the sinus is not thrombosed; if they are lateral movements only, they are of no other diagnostic importance than the brain pulsation itself. From our cases we were able to conclude that there was no sinus pulsation if the sinus

was only exposed for a short distance, and that a considerable part of its bony support had to be removed. This seems to show that the sinus pulsations are due to transmitted lateral movements of the brain. If the sinus or the mastoid vein are injured, pulsation does not occur, though the blood pressure was considerable. Hence the presence of pulsation does not allow us to conclude whether the sinus is thrombosed or not. In Case 3 a thrombosed sinus showed pulsation, and in Case 8 an abscess situated between two occluding thrombi pulsated. In conclusion it may be stated that **the pulsation of a sinus is of no diagnostic value.**

REPORT ON THE TRANSACTIONS OF THE AMERICAN OTOLOGICAL SOCIETY AT ITS MEETING JULY 19, 1898.

By HERMAN KNAPP, M.D.

The Society was called to order at 10 A.M. by the President, ARTHUR MATHEWSON, of Brooklyn.

I.—DR. GORHAM BACON, New York: **A Case of Double Mastoid Disease, Presenting Symptoms of an Intracranial Complication; Operation; Recovery.**

"[1] The case was that of a boy, four years of age, who had a cold and complained of an earache. A few days later, the pain was quite severe and he had a temperature of 104° F. The left ear was first affected, and later the right. A free incision was made in each drumhead, as there was marked bulging. This was followed by a free discharge, and by a temporary improvement in the boy's general condition As the mastoid processes were tender on pressure, the Leiter coil was applied on each side. Three days after making a free incision in each drumhead, it was deemed best to open the *left* mastoid process, as the temperature was about 104° F., and the boy's general condition did not improve. The sinus was laid bare, but was not opened, as it did not seem necessary. After the operation, the temperature fell to 102° F., but soon rose again to 104° F. On the following day, the *right* mastoid was opened and the sigmoid sinus was exposed. Very little pus was found in either mastoid process, but the bone was soft and there was granulation tissue.

A culture was made and pneumococci were found, with a few staphylococci.

Remarks.—The case presented symptoms of sinus thrombosis,

[1] Quotation marks indicate that the abstracts were furnished by the speakers.

but it was considered best to operate on both mastoid processes first, and to expose the sigmoid sinus on each side and watch the effect of such procedure, before resorting to the more serious operation of opening either sinus. The wisdom of this course was fully justified in the result of the operation, for the rise in temperature and other symptoms disappeared entirely, and the boy made an excellent recovery. The Leiter coil in such cases (viz., where pneumococci and streptococci are found) is of but little avail and in fact often masks the symptoms. If the temperature remains high after a free incision has been made in the membrana tympani, our attention should be immediately directed to the condition of the mastoid cells and the sigmoid sinus, remembering that the operation of opening the mastoid cells and exposing the sigmoid sinus is a comparatively safe procedure, if performed carefully and under strictly aseptic conditions."

Discussion.—Dr. GRÜNING, who was present at the operation, said that the walls of the sinuses were thickened, which made them suspicious of the presence of a clot. The sinuses were not opened owing to the absence of symptoms of sepsis.

Dr. F. B. SPRAGUE, of Providence, reported a similar case in a child. Temp. high ; vomiting. Both drum-membranes punctured. Then left mastoid opened ; pus in antrum ; sinus exposed and punctured ; escape of blood. The other mastoid opened, found more affected ; the sinus exposed and slit ; fluid blood escaped. Euphoria at first. Aggravation in a week. Apathy ; coma. Cranial cavity opened, nothing found in middle fossa, nothing in brain. Opened the left mastoid again, nothing found in the cranium. The coma disappeared in a day. Patient felt better from the third day, when on changing the dressing a large quantity of pus escaped from the wound. Recovery.

Dr. KNAPP said that after opening the cranial cavity when no pus was found, pus might escape copiously a few days later. This fact was not unknown, and he himself, a few years ago, had communicated such a case to the Society, where, on account of grave meningitic symptoms, the diseased mastoid had been opened, and both the middle and posterior cranial fossæ exposed, without liberating pus, but two days later, while changing the dressing, a large quantity of fœtid pus soaked the gauze. Rapid and permanent recovery.[1] He had asked himself where this pus

[1] *Trans. of Am. Otol. Soc.*, vi., p. 290.

had come from, and believed that it must have been penned in the jugular foramen, around the bulb of the vein.

His view was supported by an autopsy he made about ten years ago.

Dr. BLAKE confirmed Dr. Knapp's opinion.

II.—DR. J. E. SHEPHARD, of Brooklyn: **A Case of Sinus Thrombosis; Operation; Recovery.**

After grippe, earache, temp. 103°. Chills, temp. 105°. Weakness. Otorrhœa. Tenderness at posterior border of mastoid. Membrana tympani incised. Tip filled with pus. Extradural collection of pus. Temp. fell temporarily. Four days later lateral sinus opened, septic thrombus found. Both optic disks choked.

Another operation. The jugular vein found free from pus. The lateral sinus was opened toward torcular Herophili. Thrombosis and pus found, especially in bulb of jugular. Recovery.

Staphylococcus found.

Discussion.—Dr. GRÜNING, who was present during the operation, said that subnormal temperatures were sometimes met with in thrombosis, not in malaria. Dr. Shephard's patient also had felt well for a time.

III.—DR. J. ORNE GREEN, of Boston, demonstrated **Three Specimens of Suppuration of the Labyrinth, Two of them Producing Abscesses of the Cerebellum; Operations.**

"Three temporal bones showing caries in labyrinth, the effects of chronic suppuration of tympanum, all leading to infection of the cerebellum and abscesses in the anterior portion of that organ. In all, a full tympano-mastoid exenteration (radical operation) had been performed, and the caries of the labyrinth exposed, and the diagnosis of the cerebellar disease made. In all, the caries was essentially in the same positions, but more extensive in the third than in the other two. All showed a carious perforation into the vestibule, one eighth of an inch above the foramen ovale, a carious opening into the external semicircular canal through the wall of the aditus, and a carious perforation into the superior semicircular canal. In two the horizontal (tympanic) portion of the Fallopian canal had been destroyed, and in the third it was carious but not yet perforated."

He added another specimen. Caries of the *descending process of the incus.* The patient had been successfully operated on for *cholesteatoma* nine years ago. Nine months ago otorrhœa again. A drop of pus came down the attic. Ossicles removed; only the

descending process of anvil carious. Discharge ceased. Patient is well.

IV.—Dr. C. J. BLAKE, of Boston: **Blood-Clot in Mastoid Operations.**

Dr. Blake for two years has tried to obtain healing by first intention, under a blood-clot, in operating on the mastoid both in acute and chronic cases. In both he obtained encouraging results. As soon as discharge set in, he removed the clot, yet there were cases where discharge appeared only in one corner of the wound, necessitating only the removal of the adjacent portion of the clot. He treated in this way 25 cases, 16 acute, 9 chronic. He wants to pursue this treatment longer before he gives a definite opinion as to the breadth of its applicability.

Dr. Sprague has made similar experiments since 1893; ten cases, results satisfactory.

Dr. Bacon has seen some of Dr. Blake's cases and found the results very satisfactory, even in chronic cases. He tried it years ago, particularly in acute cases.

Dr. E. A. Crockett tries to obtain primary union, opens only at appearance of discharge.

V.—Dr. E. GRÜNING, New York: **Case of Abscess in Temporo-Sphenoidal Lobe; Autopsy.**

Dr. Grüning related a very complicated case of brain abscess. Boy of seventeen years. Chronic otorrhœa, at times offensive. Headache, etc. Pulse 80, temp. 100°. Admitted to Mt. Sinai Hospital. Stupor, coma. Mastoid caries in antrum; cholesteatoma. Complete exenteration of middle ear. On opening post. cranial fossa, an extradural abscess was found. A large quantity of pus escaped. Coma disappeared. No dizziness. Euphoria for a week; at each dressing a large quantity of pus was liberated. No dizziness, no fever, but coma again. Another operation discovered and emptied a large abscess in the temporo-sphenoidal lobe. Death in a week. The autopsy showed that the abscess drained through a fistula into the post. cranial fossa.

Discussion.—Dr. Green wanted to know what course the fistula took, especially with regard to the tentorium cerebelli. Dr. Grüning said he had not been present at the autopsy and could not state the exact topographical relations.

VI.—Dr. C. J. BLAKE **makes a short communication: How the Intracranial Pressure can be Utilized to Stop Hemorrhages in Accidental Wounding of a Sinus or an Artery.**

He removes the bony wall at the outer side of the sinus for a short distance. The intracranial pressure will then crowd the sinus against the bone at the border of the gap, and by bending and compressing it stop the hemorrhage. In certain cases he has found this procedure expedient.

VII.—Dr. H. KNAPP: **The Functional Examination of the Ear; with Demonstration of Bezold's Continuous Tone Series.**

"We have to examine the perception of the intensity, pitch, and clang-tint of sound. The latter has not yet been tested. The first, intensity, gives us the patient's sharpness of hearing. Watch and acoumeters, though our views of noise and tone have changed, will, by their convenience, remain in use. The human voice is now universally acknowledged as the best testing means. The handling and interpreting it have largely a personal character. As every one has to try his own watch on a sufficient number of healthy ears, so he has to try the audibility of his voice, its strength as a given factor, and the dampening surroundings as resistances. The method of recording the acuteness of H as a fraction of the normal, long ago introduced in America, should be continued. For the detection of absolute deafness in one ear, Knapp has always obtained satisfactory results by using three tests: Dennert's, Weber's, and the one described by himself about fifteen years ago, when judiciously applied. The examination of pitch is important for diagnostic purposes. It has been brought to perfection by Bezold's continuous tone series, which of late has brought to light two very remarkable and important facts, 1. the preservation of portions of the scale in the hearing of deaf-mutes (hearing-remnants, tone-islets), which should be found out in every deaf-mute before a plan of his teaching is determined on in his particular case; 2. that the alleged hearing in labyrinthless ears is but a reflex, a pale photograph, of the hearing picture of the other ear, thus settling in the negative forever this old controversy of the hearing of labyrinthless ears."[1]

Bezold's instruments were inspected by the members of the Society with great interest, and a lively

Discussion ensued as to the designation of the tuning-forks used in testing H. Dr. Green advocated always to write the letter, say

[1] A more detailed abstract of Dr. Knapp's communication will appear in the *Trans. of the Am. Otol. Soc.*, and the full paper is contained in this number of the Archives of Otology (August, 1898).

c^2, and add the number of vibrations, single or double, etc. Dr. BLAKE said the numbers for the same tone were given differently by different authors, in the history of acoustics. Dr. KNAPP said that was so at the present day, and he would propose that we should use the values given by Helmholtz in his "Tonempfindungen." It was mentioned that an international agreement should be brought about. As to detecting one-sided deafness, Dr. BLAKE said that Dr. Knapp's test had given him reliable results. He uses a c^2 fork.

VIII.—DR. H. A. ALDERTON, Brooklyn: **Tuning-Fork Reactions in Affections of the Sound-Conducting Apparatus.**

"Gives the results of tests with Hartmann's set of tuning-forks, to which the C^{-1} fork was added. First gave the average normal reaction in seventeen cases, obtained with the same set of tuning-forks; then the average reaction in thirteen cases of cerumen and otitis media purulenta, both before and after treatment. These latter cases all having great impairment of hearing before treatment and practically normal hearing after."

Alderton arrives at the following conclusions:

"1. The C^{-1} fork is unreliable in testing by B. C. In the normal ear Rinné is often given as negative with it.

2. The absolute duration of B. C. in lesions of the sound-conducting apparatus exclusively would seem to be diminished slightly from the normal.

3. A. C. is the more impaired the lower we go in the scale.

4. B. C. is maintained as well for the higher as for the lower forks. Certainly there is no decided falling off as the higher forks are reached.

5. There is an abbreviated positive duration Rinné for all except the C^{-1} fork, which gives a negative duration Rinné.

6. There is a negative intensity Rinné extending over the lower forks.

7. Improvement in hearing carries with it a withdrawal of the negative intensity Rinné towards the lower tone-limit.

8. Improvement in hearing increases A. C.

9. Improvement in hearing brings about also an increase in B. C. up to or above normal.

10. The Weber test, in the majority of cases, was changed from positive before treatment to equality after treatment.

11. The Galton whistle showed the upper tone-limit, which was at the mark 1.25 in the normal, to be lowered to 1.6 in diseases of

the sound-conducting apparatus previous to treatment, and elevated nearly to normal, viz., 1.38, after treatment. This slight lowering of the upper tone-limit in diseases of the sound-conducting apparatus confirms the earlier findings of the writer."

IX.—Dr. H. A. ALDERTON: **Trephining of the Stapedial Footplate for Otitis Media Sclerosa.**

"Related the history of a case of otitis media sclerosa, in which the attempt to extract the stapes ruptured the crura without bringing away the footplate, but advanced the hearing distance from under four feet to over eighteen feet, probably by violently breaking up the bony and fibrous union of the footplate to the oval window. This improvement was only temporary, the hearing returning to its former condition.

At a subsequent sitting the footplate was trephined without any bad effects, but also without any improvement in the hearing. No dizziness followed, but only a strange commotion of sound. Autophony was complained of. There was no inflammatory reaction.

Doubts whether any permanent improvement in function is to be hoped for as the result of this procedure *in otitis media sclerosa.*"

Discussion.—Dr. Jack said that the removal of the stapes in two of his cases had produced a permanent improvement of hearing. Dr. Blake spoke of some cases in which he had removed the whole stapes, or the limbs only. In one the hearing immediately after the operation was greatly improved, the patient was dizzy, and there was discharge of watery liquid from the ear. When the outflow stopped, the dizziness and also the improvement of hearing disappeared. Dr. E. A. Crockett: In a case of removal of the stapes hearing improved, and was kept improved by Politzer's inflation. In a case of mobilization of the stapes with a fine hook, hearing was not improved, and vertigo ensued.

X.—Dr. THEOBALD, of Baltimore: **Remarks upon the Treatment of Otomycosis by the Insufflation of Boracic Acid and Oxide of Zinc.**

"Seventeen years ago, in the *American Journal of Otology*, he had first called attention to this method of treating otomycosis, which he has since used in every case that he has met with, with uniformly favorable results. The fact that the majority of otologists still seem to adhere to the treatment of this affection by instillations of alcohol, which he thinks should long since have

become obsolete, led him to speak of the subject again. Alcohol is not a suitable agent to pour into an inflamed and painful ear, and its comparative inefficiency as a parasiticide seems to be shown by the fact that Hovell recommends that the instillations should be kept up for three months, and Politzer for a year, in order to prevent a regrowth of the fungus. On the other hand, one, two, or, at most, three applications of the oxide of zinc and boracic acid powder, which is blown lightly into the ear at intervals of twenty-four or forty-eight hours, effect as complete a removal of the parasite as possible, effectually destroy the fungus, and the powder is at the same time one of the best remedies we have for overcoming the attendant inflammation."

Discussion.—Dr. SUTPHEN found that boric acid powder alone cured otomycosis.

XI.—DR. ROBERT LEWIS, JR., of New York: **Extradural Abscess; Operation; Death.**

Chronic otorrhœa. Facial paralysis for two weeks. Removal of polypi and carious bone. Radical operation. Opening middle cranial fossa. Epidural abscess, in which tubercle bacilli were found. Three days later drowsy. Operated again. Ether. Patient asphyctic, requiring artificial respiration for two hours. Then Dr. Lewis went into the brain with an aspirator needle and withdrew cerebral liquid. In five hours patient expired. No autopsy.

Discussion.—Dr. GRÜNING thinks that the aspirator needle should not be longer than 1½ inches. Dr. BLAKE said in one case where he had failed to find pus in the brain, it had been found at the autopsy situated in a recess of the bone over which the aspirator needle had passed.

The meeting of the Society was closed at 4.35 P.M. It was attended by thirty-nine members, and some guests who had been invited to take part in the discussions. A number of new members were elected. Dr. E. L. HOLMES, of Chicago, one of the oldest members of the Society, who, on account of ill-health, had sent in his resignation, was unanimously elected an honorary member.

The officers of the Society were re-elected, only Dr. VERMYNE, who for years had served the interests of the Society with the greatest punctuality and accuracy, was, on his resignation on account of ill-health, replaced by Dr. JACK of Boston.

SYSTEMATIC REPORT ON THE PROGRESS OF OTOLOGY DURING THE FIRST QUARTER OF THE YEAR 1898.

ARRANGED BY DR. A. HARTMANN.

Translated by Dr. ARNOLD H. KNAPP.

ANATOMY OF THE EAR.

1. HEGETSCHWEILER, J. The embryological development of the stapes. *Arch. Anat. u. Entwicklungsgeschichte*, 1898, Heft 1.

2. BRÜHL, G. New method to demonstrate the cavities of nose and ear. *Anatom. Anzeiger*, xiv., No. 2.

1. HEGETSCHWEILER found that the stapes first appears as an annular formation around the stapedial artery, derived from the hyoid arch, independent of the labyrinth wall. KRAUSE.

2. BRÜHL's method is: Injection of Hg into the free spaces of the decalcified and dehydrated bone, and clearing with xylol; further injection of Hg into the pneumatic cavities of the ear and the accessory cavities of the nose, and photography with the Röntgen rays. KRAUSE.

PHYSIOLOGY.

3. BRAUER, J. On semicircular canals and space-sense. Pflüger's *Arch. f. Phys.*, vol. 68, p. 596, 1897.

4. OSTMANN, J. On the action of the tensor tymp. muscle, etc. *Trans. of the Soc. of Naturalists*, Marburg, No. 1, 1898, p. 1.

5. HAMMERSCHLAG, V. Contributions to the embryological development of the mechanism of the cochlea. *Arch. f. Ohrenheilk.*, vol. 44, p. 101.

6. COLMAN, W. S. Further remarks on color-hearing. *Lancet*, Jan. 1, 1898.

3. The old controversy, especially against Cyon, continued.

4. On the function of the tensor tympani there are three different opinions: *a.* the muscle serves only as an elastic ligament in the conductive apparatus of sound; *b.* it is a protective apparatus against excessive sound waves; *c.* it is an apparatus of accommodation. OSTMANN concludes from the actual facts that (1) the presence of the tens. tymp. muscle is of little influence on the acuteness of sound; (2) absence of its action renders the ear insensitive for high tones; (3) it strongly checks the outward movements of the hammer and tymp. memb. Experiments on dogs seem to justify the conclusion that the muscle does not serve the accommodation of the ear for different conditions of sound.

5. HAMMERSCHLAG tries to support, by phylogenous development of the cochlea, the hypothesis that this organ is adapted as well for sensations of noises as for sensations of tones, an opinion which now is almost universally accepted.

6. COLMAN wrote papers on this interesting subject in the *Lancet* of March 31 and April 7, 1894. He deals with the faculty present in a considerable percentage of persons, of experiencing a sensation of color in association with certain sounds, the color being definite and invariable for the same sound.

The cases fall into two groups:

(1) A crude color sensation, often very beautiful, is associated with certain sounds, such as each of the vowel sounds, musical notes, or particular musical instruments; the appearance being usually that of a transparent colored film, similar to a rainbow, in front of the observer, but not obscuring objects.

(2) Color sensations whenever letters or written words (symbols of sound) are spoken or thought of, so that when a word is uttered the subject visualizes the letters, each of which has a distinctive tint. Interesting cases are related.

ARTHUR CHEATLE.

GENERAL.

a.—REPORTS AND GENERAL COMMUNICATIONS.

7. GRUNERT, C. Annual reports of the Halle ear-clinic for 1895 and 1896. *Arch. f. Ohrenheilk.*, 44, p. 1.

8. SZENES. On traumatic lesions of the auditory organ. *Ann. des mal. de l'or., du lar.*, xxiv., 1.

7. These reports are prepared with the usual care. Several interesting histories of cases and operations deserve to be studied in the original. It seems that at Halle they are now beginning to operate with primary closure of the retro-auricular wound, a practice which the reviewer has followed for nearly four years with perfect satisfaction. BLOCH.

8. Of the seven reported cases, three were the result of a fall on the parietal bone, with subsequent deafness from concussion of the labyrinth; one was a fracture of the base of the skull with fracture of the auditory meatus and the hammer—the resulting deafness was referable to a lesion in the tympanum ; one, injury to the auditory canal; one, fissure of the canal with severe labyrinthine symptoms, with complete recovery. In the seventh case, the diseased epitympanic recess was syringed with a weak lysol solution and under slight pressure; immediate signs of marked vertigo set in, with vomiting and slowing of the pulse to 56, and the patient had to keep to his bed for five days; later he was cured by a radical operation. ZIMMERMANN.

b.—GENERAL SYMPTOMATOLOGY AND PATHOLOGY.

9. RANDALL, ALEXANDER. Tinnitus in its relation to nasal and aural affections. *Jour. of Amer. Med. Assoc.*, vol. xxx., No. 12.

10. ALDERTON, H. A. Some unusual aural cases. *Annals of Otol., Rhinol., and Laryngol.*, vol. vii., p. 15.

11. BREITUNG. A case of diplacusis. *Deutsche medicin. Wochenschr.*, No. 9, 1898.

12. OSTMANN, Prof., Marburg. On the relation between the ear, nose, and throat, and on rational treatment of middle-ear disease. *Die Heilkunde*, Vienna, 1897.

13. DOWLING, FRANCIS. The relation existing between Bright's disease and certain ear symptoms. *Jour. of Amer. Med. Assoc.*, vol. xxx., No. 13.

9. RANDALL divides tinnitus into an objective and subjective form. The subjective form is again subdivided into the cerebral, labyrinthine, tympanic, tubal, and the purely nasal forms of tinnitus. Before inaugurating treatment, a careful differential diagnosis is absolutely necessary.

10. ALDERTON reports the following cases: I. *A case of diplacusis binauralis echoica.* A young man, twenty-seven years

old, complaining of tinnitus and deafness in the left ear, with the c^3 fork placed on the mastoid process of the affected side (the finger in the right ear to shut out air-conduction), hears two notes, one a little later than the other; at the end of thirteen seconds the note heard by the left ear ceased, while that heard by the right ear continued to be heard for seventeen seconds more. The c^3 was the only one that gave such a reaction; as the patient was not musical, it was impossible to determine the interval. The explanation seems to be warranted that the right ear, because of its superior functional ability, heard the note as elicited, and across the head, even while the left ear was perceiving it. The pathological changes in the left ear must have been of a nature to alter the musical character of the note and to limit its duration, at the same time delaying its transmission, so that the effect of an echo was produced. Bone-conduction throughout, except for the c^4, was reduced. The author assumes therefore a change in the transmitting as well as in the perceiving apparatus.

II. *Two cases of peculiarly shaped exostosis of the external auditory canal.* In a young lady, eighteen years of age, the examination of the left ear revealed the existence of a sharply defined pyramidal exostosis on the superior portion of the posterior canal-wall, 3 *mm* in height, and the same distance from the *Mt*, the apex pointing directly toward the short process of the malleus, a true cone; the apex white as ivory, and the whole hard to the touch of the probe. Growth still seemed taking place at the pinkish vascular base. In a man, forty years of age, the author found a similar exostosis as in the previous case, and likewise in the left ear, anteriorly, about 2 *mm* external to the bony edge of the pars epitympanica; the apex white and hard; pointing to the short process of the malleus. The growth, truly cone-shaped, about 2–2½ *mm* in height, the base pinkish. The rarity consists, according to the author, in the peculiarly sharp cone-shape, in the marked vascularity of the base, and in the absence of all cause for the growths except such as might be attributed to the gouty or rheumatic diathesis.

III. *Case of marked vertigo following stimulation of the nerve-endings of the middle ear, without any change in labyrinthine tension.* In a female, aged thirty years, suffering from an otitis media purulenta chronica, following measles, the author had removed the carious malleus and incus; on syringing or pressure on the stapes, vertigo can be produced. The vertigo, however, resulted

at times when a cotton-tipped probe was applied to regions of the middle-ear cavity so far removed from the labyrinthine fenestræ that an increased labyrinthine tension could be eliminated as the cause of the vertigo. The observed condition, on irritation, was: loss of balance, staggering with tendency to fall, dilatation of pupils. Patient has the feeling as though the eyeballs were turning round; a feeling of oppression in breathing; sighing respiration; pulse weak, but not accelerated; head moves to and fro; vision, for the time being, obscured. The author cites this case as one supporting Barr's theory (*British Medical Journal*, May 1, 1897), who believes that many cases of giddiness are not due to disturbance in labyrinthine tension, but to reflex action between the nerves distributed in the mucous membrane of the middle ear and the centre of equilibrium in the cerebellum, so that when the former are irritated, the latter is apt to be disturbed. FELIX COHN.

11. A man, otherwise healthy, was suffering from catarrh of the Eustachian tube, and noticed that on whistling he perceived the tone double, with the left ear of the normal pitch, but with the right ear one half a tone higher. This phenomenon disappeared on catheterization. BREITUNG thinks that the diplacusis was caused by anomaly of tension in the drum-membrane acting reflexly through fibres of the fifth nerve on the auditory nerve.

NOLTENIUS.

12. OSTMANN describes the well-known connection between diseases of the middle ear and any pathological change in the nose and pharynx, and pleads for the proper treatment of the nose and pharynx before the ear proper is treated.

BRÜHL.

13. A limited number of cases of ear affections, accompanied by certain well-marked symptoms, such as tinnitus aurium, dull aching pain in the region of the mastoid, more or less reduction of the hearing power, slight irregularity of the gait, have been observed by DOWLING to occur in patients suffering from Bright's disease. Author cites two cases, and explains the aural symptoms with the theory that probably the retention of morbid matters in the blood produces a toxic irritation of the filaments of the nerves of hearing, as they spread out in the labyrinth, and possibly causes an albuminous degeneration similar to the condition known as retinitis albuminurica.

FELIX COHN.

c.—METHODS OF EXAMINATION AND TREATMENT.

14. POLITZER, A., Prof. Treatment of aural affections from the auditory canal. *Klinisch-therapeut. Wochenschr.*, Nos. 10 and 11, 1898.

15. FRIEDLANDER, E. Treatment of sclerosis of the tympanic mucous membrane with massage. *Berl. klin. Wochenschr.*, No. 12, 1898.

16. LUCAE, A., Prof. Remarks on Breitung's article on pneumatic massage of the drum-membrane with an electromotor air-pump in the treatment of progressive deafness. *Deutsche medizinal Zeitung*, No. 91, 1897.

17. MARSHALL, M. E. What can be accomplished by treatment of Eustachian tube. *Jour. Amer. Med. Assoc.*, xxx., No. 12.

18. MÉNIÈRE. The use of rubber bougies in the treatment of chronic catarrhal affections of the Eustachian tube and the middle ear. *Arch. internat. de lar., d'otol.*, xi., No. 1.

19. REYNIER and GLOVER. Anatomical relations of the cranium, the bony cavities of the face, and the cerebral sinuses studied by means of radiographs. *Rev. hebdom. de lar., d'otol.*, xix., 3.

20. LAUTENBACH, L. J. Some further results in treating ears by massage methods. *Jour. of Amer. Med. Assoc.*, vol. xxx., No. 13.

14. POLITZER discusses the relative value of air-condensation, of air-rarefaction, and the alternating air-condensation and air-rarefaction (massage Delstanche) in diagnosis and treatment. He employs air-rarefaction (1)in the diagnosis of the degree of tension and resistance of the various parts of the drum-membrane; (2) to discover the seat of perforation when this does not become apparent with Valsalva or the air-douche; (3) to diagnose partial suppurations in the middle ear and possibly extradural abscess. In treatment air-rarefaction is of value (1) in middle-ear catarrhs with marked retraction of *Mt;* (2) to remove serous and mucous masses from the tympanum after paracentesis; (3) to remove the discharge in middle-ear suppuration; (4) in nervous deafness; (5) in subjective noises, and finally in cases of aural vertigo.

Air-condensation is diagnostically important in Gellé's test, and to restore the patency of the Eustachian tube in cases of perfora-

tion of the *Mt* and to irrigate through the Eustachian tube. Politzer recommends massage (Delstanche), especially in the treatment of middle-ear sclerosis. POLLAK.

15. FRIEDLANDER has treated twenty cases of sclerosis with Wegener's "vibromasseur"; the subjective sensations were relieved in all except one case, though the hearing was unaffected.

MÜLLER.

16. LUCAE protests against the criticism of his results obtained by massage of the drum-membrane. The criticism is misunderstood, as Lucae's experience was obtained with the use of Delstanche's hand-pump and not with Breitung's apparatus. Lucae has obtained a simple guard by making a small opening in the rubber tube of Delstanche's instrument which serves as a safety-valve. H.

17. MARSHALL recommends the use of bougies streaked with 3 % silver nitrate in lanolin, in the treatment of chronic stenosis of the Eustachian tubes. The bougie is to remain from twenty to thirty minutes, and is not to be applied more than twice in a week. Seventeen cases of chronic deafness and tinnitus were treated systematically; seven of these were greatly improved, five showed moderate improvement, and in five no change was to be found.

FELIX COHN.

18. MÉNIÈRE, assuming that catarrh of the Eustachian tube is the primary lesion which later causes changes in the middle ear and deafness, advocates the passage of bougies, a practice which has been dropped on many sides. He uses well-made rubber bougies, dipped in an iodine-potassium-iodide solution and left in place from one half a minute to one hour. In the two cited cases, which had been treated for a long time with a catheter without success, hearing was very much improved, though distinct swelling of the tubal mucous membrane was present.

ZIMMERMANN.

19. The topographical relations were studied with the aid of the X-rays after hardening and injection of the blood-vessels. The sinus usually occupied the posterior quarter of the mastoid, though in a few cases the centre and the anterior half; the younger the individual the more anterior was the sinus.

ZIMMERMANN.

20. LAUTENBACH again advocates his massage apparatus, and claims good results in a number of cases.

FELIX COHN.

EXTERNAL EAR.

21. HECHT, H. On the operative treatment of congenital lack of development of the auricle, with a case. *Arch. f. Ohrenheilk.*, vol. xliv., p. 89.

22. CARETTE. On foreign bodies in the auditory canal. *Ann. des mal. de l'or., du lar.*, xxiv., 2.

23. HAUG. Operative extraction of a foreign body from the ear. *Monatschr. f. Ohrenheilk.*, No. 2, 1898.

24. BRÜHL, G. A death after extraction of a foreign body from the ear. *Monatschr. f. Ohrenheilk.*, No. 2, 1898.

25. BREITUNG, M. Chorea minor. Foreign bodies in the ear. Recovery. *Centralbl. f. innere Medicin*, No. 10, 1898.

26. REID, ST. GEORGE. Traumatic rupture of the tympanic membrane. *Medical Press and Circular*, Feb. 23, 1898.

27. BIEHL, C. Closure of perforations of the drum-membrane. *Wiener klin. Wochenschr.*, No. 12, 1898.

28. SEISS, RALPH W. Acute myringitis. *Jour. Amer. Med. Assoc.*, vol. xxx., No. 12.

21. A child, four months old, showed a combination of macrotia and microtia. The deformity was partly overcome notwithstanding suppuration during the healing process. BLOCH.

22. The bullet from a revolver became firmly imbedded in the auditory canal in front of the tympanic membrane without causing any other injury; the extraction was only effected after chiselling for 1½ hours. Recovery after four weeks.

ZIMMERMANN.

23. A carob-bean was removed after retraction of the auricle.

NOLTENIUS.

24. A child, four and a half years old, had introduced a stone in the ear, which the village barber had unsuccessfully attempted to remove. A violent inflammation of the canal and the middle-ear spaces ensued. The foreign body was removed by operation, and the antrum and the lateral sinus were exposed. The child, notwithstanding, succumbed to lateral sinus thrombosis and pyæmia. Probably a middle-ear suppuration had existed previously. KILLIAN.

25. The patient, thirteen years of age, became deaf after diphthèria five years ago, and had suffered from chorea minor for two years. A foreign body was found in the ear on examina-

tion, which was removed by syringing, and proved to be a piece of pencil. At the time of her discharge, three weeks later, the chorea had disappeared. HARTMANN.

26. A child, aged nine years, fell on the point of her chin and ruptured the drum by indirect violence. ARTHUR CHEATLE.

27. BIEHL confirms the favorable results after cauterizing the edges of a perforation with trichlor-acetic acid. He applied a 10 to 50 % solution with the cotton-tipped probe at intervals of four to eight days. POLLAK.

28. SEISS refers to the fact that myringitis is a disease which is usually disposed of very briefly in text-books, and the object of the paper is to call attention to an apparent want in modern otological literature in regard to the classification of acute otitis, the prevalent opinion being to classify myringitis under acute otitis. He divides acute myringitis into the simple, desquamative, hemorrhagic, and suppurative varieties. The suppurative variety is, according to the author, more often a primary disease than is generally assumed. FELIX COHN.

MIDDLE EAR.

a.—ACUTE OTITIS MEDIA.

29. DENCH, EDWARD B. The surgical treatment of acute inflammations of the middle ear. *Jour. Amer. Med. Assoc.*, vol. XXX., No. 12.

30. PANZER, B. Purulent extension during inflammatory affections of the middle ear. *Wiener klin. Rundschau*, Nos. 12 and 13, 1898.

29. DENCH recognizes two forms of inflammation of the middle ear, one affecting primarily the atrium, and the other the vault of the tympanum. The inflammation of the atrium is usually catarrhal, and, owing to the small amount of connective tissue within this space, suppurative inflammations are practically impossible. The inflammation in the tympanic vault generally leads to connective-tissue necrosis and the formation of pus; the inflammation in this region therefore constitutes a true cellulitis. While in the catarrhal inflammation antiphlogistic measures usually suffice, operative treatment is imperative even in the incipient inflammations of the tympanic vault. The author generally employs a small knife resembling a tenotome, the blade being about three quarters of an inch in length, instead of the

old form of myringotome. In cases of suppuration of the tympanic vault, a stronger knife, and one having the blade a little curved, is preferable. FELIX COHN.

30. PANZER describes four cases of purulent extension in otitis media which had previously been operated upon. In one case the pus burrowed back toward the occiput, causing elevation of the periosteum, caries of the bone, and exposing the dura. In the second and third cases an abscess descended into the neck with periostitis of the cranial roof, caries, and extradural abscess. In the fourth case a remarkable perforation took place toward the zygoma. POLLAK.

b.—CHRONIC PURULENT OTITIS.

31. KRAUS, E., Paris. A new treatment for chronic purulent otitis. *Allgem. Wiener med. Zeitung*, No. 12, 1898.

32. KRETSCHMANN, Magdeburg. Clinical and pathological contributions on caries of the malleus and the incus. *Festschrift zur Feier des 50 jahrigen Bestehens der medicinischen Gesellschaft zu Magdeburg*, 1898.

33. BURNETT, CHARLES HENRY. Intratympanic surgery especially in chronic purulent otitis media. *Jour. Amer. Med. Assoc.*, vol. xxx., No. 12.

34. STUCKY, J. A. Ossiculectomy in chronic suppuration of the middle ear. *Jour. Amer. Med. Assoc.*, vol. xxx., No. 13.

35. PIERCE, H. NORVAL. Removal of the ossicles, with report of six cases. *Jour. Amer. Med. Assoc.*, vol. xxx., No. 13.

36. WOODS, HIRAM. Three cases of suppurative otitis media; severe systemic and remote disturbances; recovery after mastoid operation and removal of polypi. *Jour. Amer. Med. Assoc.*, vol. xxx., No. 12.

37. BRYAN, J. H. Report of two cases of suppurating mastoiditis. *Jour. Amer. Med. Assoc.*, vol. xxx., No. 10.

31. KRAUS has cured four cases of chronic otorrhœa with the insufflation of traumatol (iodocresyl). POLLAK.

32. KRETSCHMANN'S careful investigations on caries of the ossicles are based on 64 hammers and 41 anvils removed from 70 diseased ears, of which 35 were extracted through the auditory canal and 35 at the time of the radical operation. The anvil was found more frequently carious, and the long process was more usu-

ally affected than the short one. The body of the anvil was found regularly diseased with one of the processes, except in one case (tubercular), where the body alone was affected. The articular surfaces remain the longest uninvolved. The head of the hammer is the portion of that body most frequently affected, especially on its outer and anterior surface. The articular surface usually remained uninvolved. The handle was less frequently diseased, particularly in the region of the short process and the lower part of the neck. Anchylosis of the hammer-anvil joint was present four times. Cicatrization of defects in the anvil were found five times; caries of the ossicles can thus be healed without operation.

Caries of the parts of the ossicles situated in the attic is usually the result of an inflammation in the hammer-anvil depression. This depression, as has been shown by casts, is a space usually shut off from the tympanic cavity. The suppurations in this locality, however, usually originate in the tympanum. The suppurative process often commences insidiously and runs a chronic course, or persists in the depression after the suppuration in the tympanum, and leads to caries of the ossicles. The caries usually begins at the above-mentioned places, which offer, from their relation to the depression or the absence of protecting ligaments, a favorable site for the destructive process.

Caries of the ossicles is recognized from the well-known symptoms (Schwartze, Panse, Grunert). Whether the ossicles alone are diseased or not is usually only shown by the result of the treatment.

Recoveries are often obtained by irrigations with the tympanic canula. When this is unsuccessful and the existence of isolated caries is probable, the extraction of the ossicles is indicated. The results are favorable (55 % cured). Hearing is usually improved. Stacke's operation is reserved for the complicated cases and where the canal is narrow.

Kretschmann has modified his anvil hook. KÖRNER.

33. BURNETT gives a very interesting report of his experience in intratympanic surgical interference, especially in chronic purulent otitis media. As he evidently has had a large experience in that direction, having performed the operation 109 times, a report of his results must be instructive. The operation was performed 43 times for the relief of chronic catarrhal deafness and tinnitus, 26 times for the relief of chronic tinnitus and tympanic vertigo of catarrhal origin, and 30 times for the relief of chronic puru-

lency of the middle ear. The last 30 cases are reported at length, and the results obtained were as follows: Total cessation of discharge in 15 cases, marked diminution in 7, and diminution simply in 8. Total cessation of discharge occurred five times within two months, three times in one month; four times in two weeks, once in a year, and once in a year and a half. The attic alone was affected in nine, the atrium alone in seven, and the attic and atrium together in fourteen cases. In no instance was the stapes resected or removed. The after-treatment consisted in alcohol instillations or alcoholic solutions of boric acid or acetanilid as long as signs of granulations were present. After the disappearance of the granulations, a 2½ % carbolic acid solution or a solution of bichlorid (1:6000) acted best. Hearing was improved in fifteen cases, unaltered in ten; in five instances was unrecorded. FELIX COHN.

34. Thirty-six cases of ossiculectomy in chronic suppurative inflammations are reported by STUCKY, and the following results were obtained. In thirty cases suppuration ceased, and hearing was improved from ten to twenty per cent.; all uneasiness in head and ear relieved. In four cases the suppuration stopped entirely for several months, then returned, the recurrence due to the formation of granulations. In two cases results, so far as relief of suppuration, negative. These cases, however, were afterwards found to be tubercular. In eleven cases the incus could not be found, and only a part of the malleus. In the remaining twenty-five cases the entire remaining portions of the malleus and incus were removed. The greatest amount of necrosis was observed in the incus. FELIX COHN.

35. PIERCE reports six cases in which the tympanic membrane and one or more of the ossicles were removed. Two of them chronic suppurative, three chronic sclerosing, and one chronic catarrhal inflammation. He formulates the following indications for the removal of the ossicles: 1. When the perforation, situated anywhere in the pars tensa, is small, and the membrane thickened, and the discharge copious, offensive, and has resisted continuous treatment by means of gauze drain for one month. 2. Where the perforation is small, the membrane thickened, the discharge scanty, but odorous. 3. When more or less of the pars tensa has been lost, but the discharge continues, evidently coming from the attic. 4. When any of the indications already formulated by Schwartze or Grunert are present (*Arch. f. Ohrenheilk.*,

xxxiii., p. 207). Author further considers operation rational in catarrhal deafness, but not in cases of deafness due to sclerosis.

FELIX COHN.

36. WOODS reports three cases as examples of severe systemic disturbances without very great change in the mastoid bone. In the first case in which the mastoid complication was accompanied by a painless otorrhœa, there were septic symptoms for five days and only about one drop of pus found in the mastoid. In a second case of mastoid inflammation following scarlatina, the process was opened without finding either pus or a carious point in cortex. In the third case reported, symptoms resembling intracranial complications were relieved by thorough curettement of middle ear, which had been blocked by polypi. Author compares these cases to cases of acute cellulitis, in which the constitutional symptoms likewise disappear when the infected area is drained. FELIX COHN.

37. The evil results following the indiscriminate application of poultices and the injudicious use of the air-bag are ably demonstrated by BRYAN. The author reports two severe cases of deep abscesses of neck, extensive caries of the mastoid following the use of poultices and the air-bag in acute suppurating otitis media. In both cases extensive incision of deep abscess and opening of mastoid effected a cure. FELIX COHN.

c.—CEREBRAL COMPLICATIONS OF PURULENT OTITIS.

38. KNAPP, HERMAN. Acute and chronic caries and necrosis of the mastoid; pachymeningitis externa; epidural abscess. *Jour. Amer. Med. Assoc.*, vol. xxx., No. 12.

39. BELL, JAMES. A case of abscess of the temporo-sphenoidal lobe presenting unusual features. Operations. Recovery.

40. GRADENIGO. On the endo-cranial complications of purulent otitis. *Ann. des mal. de l'or., du lar.*, xxiv., 2.

41. THOMAS and CATREIL. Cholesteatoma; cerebral abscess; unsuccessful punctures on the forty-first day of treatment; sudden death on the fifty-fifth day. *Rev. hebdom. de lar., d'otol.*, xix., 9.

42. BOJEW. Several cases of pyæmia of otitic origin. *Rev. hebdom. de lar., d'otol.*, xix., 8.

43. WOODS, R. H. A case of middle-ear disease. *Dublin Jour. of Med. Science*, Feb., 1898.

38. KNAPP illustrates the course of acute mastoid caries in a number of interesting abstracts of case histories selected from his recent practice. The nine cases selected constitute a series of progressive acute and chronic destruction with extension into the cranial cavity. Eight cases in which timely and sufficient operations were performed recovered. One case in which there was no surgical interference ended in death by epidural abscess. The author, before entering into the report of the cases, gives a brief review of the symptomatology of mastoid caries.

FELIX COHN.

39. A case of abscess of the temporo-sphenoidal lobe is reported by BELL. The unusual features of the case consisted in the occurrence of fits of an epileptiform nature two and a half months after the patient had been discharged from the hospital. The convulsions lasted for a period of from four to six weeks and gradually disappeared. FELIX COHN.

40. During the last two years GRADENIGO has observed and operated on 21 extradural abscesses, 9 sinus thromboses, 10 leptomeningitides, 4 cerebral and 2 cerebellar abscesses. The accompanying remarks are brief, but of no especial interest.

ZIMMERMANN.

41. It is not certain whether an abscess was present, as none was found at the operation, and no autopsy was made. The patient died on sitting up suddenly; the abscess had possibly broken into the ventricle. Punctures were made only in the temporal and frontal lobes. ZIMMERMANN.

42. BOJEW considers pyæmia a sign of sinus-thrombosis, though in his 8 cases this was confirmed in only 5 either by operation or autopsy. In the remaining 3 cases the sinus was not exposed in 2; in the third the sinus was exposed, and the jugular vein was ligated, though nothing is stated about the condition found. ZIMMERMANN.

43. At a meeting of the Royal Academy of Medicine in Ireland, held November 12, 1897, WOODS related the case of a man, aged twenty-seven years. A discharge had been present from the ear for seven years. Seven days before he was admitted with symptoms of typhoid fever, the discharge had ceased. Operations revealed septic thrombosis of the lateral sinus, extradural abscess in the posterior fossa, and an abscess in the temporo-sphenoidal lobe containing four drachms of pus. Recovery occurred. ARTHUR CHEATLE.

d.—OTHER MIDDLE-EAR AFFECTIONS.

44. MALHERBE. Some additional cases of aural catarrh treated by the mastoid operation. *Arch. internat. de lar., d'otol.*, xi., 1.

45. GLEASON, E. B. Phenomena observed in twelve cases at various stages of the operation for section of the incudo-stapedial articulation and mobilization of the stapes. *Jour. Amer. Med. Assoc.*, vol. xxx., No. 10.

46. MATTE. Absolute indication for the tenotomy of the tensor tympani in a complicated fracture of the skull. *Deutsche med. Wochenschr.*, No. 5, 1898.

44. To the sixteen cases previously published, MALHERBE adds five more where he believes to have had good results from the mastoid operation. Exact functional examinations are again missing. The less advanced the deafness, the better the results.

ZIMMERMANN.

45. Twelve cases of advanced sclerotic catarrh of the middle ear were selected by GLEASON. In some an attempt was made to mobilize the chain of ossicles by traction in various directions upon the lower portion of the long process of the incus. In others the tendon of the stapedius muscle was severed, and subsequent traction made upon the incus. In other cases the incudo-stapedial articulation was severed and a direct mobilization of the stapes attempted by means of lateral pressure and lever-like movements with a cotton-tipped probe in direct contact with the head of the stapes.

Careful functional tests proved that not the slightest improvement followed the incision of the drumhead and the turning forward of the flap. Nor was any improvement effected by subsequent manipulation of the incus. The section of the stapedius, performed in two cases, was followed by an immediate improvement of hearing. In both cases further improvement followed the incision of the incudo-stapedial articulation and mobilization of the stapes. Tinnitus was relieved in all cases. In five cases only was there any noticeable and practical improvement of hearing. The improvement, however, was not lasting, and invariably disappeared within a few months after the operation.

FELIX COHN.

46. A woman, nineteen years old, fell from a considerable height and sustained a fracture of the skull. Several months

later she applied at the ear-clinic on account of annoying subjective noises in the affected ear. On examination the labyrinth was found intact. From the facial paresis and the line of the fracture in the auditory meatus it could be decided that the facial nerve had been injured at its turn from the tympanum to the mastoid. Thus the stapedius and all the muscles of the face had been paralyzed. The loss of function of the stapedius muscle permitted the unrestrained action of the tensor tympani, with increased pressure within the labyrinth and subjective sensations. The tenotomy of the latter muscle was performed under cocaine anæsthesia, and the annoying subjective symptoms disappeared permanently. NOLTENIUS.

NERVOUS APPARATUS.

47. BING, A. A typical case of Ménière's disease. Recovery. *Wiener med. Wochenschr.*, No. 4, 1898.

48. ALT, F., Vienna. The influence of increased intracranial pressure on the sound-perceiving apparatus. *Monatschr. f. Ohrenheilk.*, No. 3, 1898.

49. ALT, F. A contribution to the pathology of the cortical auditory centre. *Monatschr. f. Ohrenheilk.*, No. 1, 1898.

50. LIEBMANN, A., Berlin. Congenital psychical deafness. *Allgem. med. Central-Zeitung*, No. 31, 1898.

47. Supplementary to the history of the case, BING advises the abandonment of the terms, Ménière's symptoms and Ménière's symptom-complex, and advocates the term morbus Ménière for the apoplectic form. POLLAK.

48. With increased intracranial pressure, interstitial lymphatic infiltration of the auditory nerve was found ; likewise an injury to Corti's organ from depression of Reissner's membrane. The auditory centres may also suffer, especially in ac. and chr. hydrocephalus, from œdema, softening and shrinking of the auditory nuclei. According to ALT, the examination with tuning-forks or the electrical examination of the auditory nerves in brain tumor do not furnish any reliable results. KILLIAN.

49. ALT cites the cases in the literature. Unquestionably the first temporal convolution is in communication with the auditory organ of the opposite side. There is probably also a communication with the ear of the same side. Focal lesions in the left temporal lobe can be diagnosticated. Alt gives the history of a case of this kind. KILLIAN.

50. LIEBMANN divided deaf-mute children in three classes. The first class contains the purely motor cases. The children do not learn to talk because their organ of speech is too clumsy to imitate the words heard. The second class is combined motor and sensory. The speaking knowledge embraces only a few words; these children do not understand an entire sentence. In sensory deaf-mutism the children do not understand speech. The children hear the words and repeat them like an echo, though without understanding. They make themselves understood by gestures.

A boy, six years old, could not understand the simplest words, as papa, mamma, table, etc., and could not repeat a word which he had just spoken. The psychical deafness was caused by high-grade inattention and lack of memory. After five months of treatment the boy possessed a large vocabulary which he understood, and later was able to attend the high school. H.

NOSE AND NASO-PHARYNX.

a.—GENERAL SYMPTOMATOLOGY AND PATHOLOGY.

51. PARK and WRIGHT. The bacteria of the normal nose. *Ann. des mal. de l'or, du lar.*, xxiv., 2.

52. GUDER. The effect of irritations of the nasal mucous membrane on the heart and the pulse. *Ann. des mal. de l'or., du lar.*, xxiv., 1.

53. KRIEG, Stuttgart. Probable diagnosis of diseases of the nose and throat and of the general organism based on the appearance of the nose. *Sammlung zwangloser Abhandlungen*, ii., 3, 1897.

51. According to PARK and WRIGHT, the nasal secretion has not the bactericidal property which Wurtz and Lermoyez believe it to have; this agrees with the views of Klemperer and Wertheim.

ZIMMERMANN.

52. The author concludes that the connection between the nasal mucous membrane and the heart action is not a direct one but a reflex one acting through the trigeminus, as is customary in patients disposed thereto. ZIMMERMANN.

53. KRIEG from twenty-four cases endeavors to show the possibility of making probable diagnoses of nose and throat affection from the examination of the internal organs, and on the other hand from appearances of the nose and throat to diagnosticate affections in distant organs. BRÜHL.

b.—METHODS OF EXAMINATION AND TREATMENT.

54. TAPTAS. Hypnotic suggestion in nasal disease. *Rev. hebdom. de lar., d'otol.*, xix., 5.

55. WAGGETT, E. New instrument—turbinotomy cautery. *Proceedings of the Laryngological Society of London*, Jan. 12, 1898.

56. MYLES, ROBERT C. Surgery of the middle and inferior turbinated bodies. *New York Med. Jour.*, March 19, 1898.

57. AMBERG, E. A new nasal speculum. *Monatschr. f. Ohrenheilk.*, No. 1, 1898.

58. KIRSTEIN. A tongue-depressor. *Berl. klin. Wochenschr.*, No. 12, 1898.

54. A rhinitis with ridge-like hypertrophies of the turbinates, interfering greatly with respiration, was so much relieved after two sittings of hypnotic suggestion as to cause no further annoyance. ZIMMERMANN.

55. WAGGETT showed a galvano-cautery point, practically of the same shape as Jones's turbinotome, a hot platinum wire taking the place of the cutting edge. Hemorrhage is thus avoided in removing hypertrophies of the turbinal bodies. The copper wire should be thick so as to avoid overheating by the current.

ARTHUR CHEATLE.

56. Turbinotomy of the inferior body and bone is done with saw, scissors, and snare successively, that of the middle with MYLES's alligator forceps and the snare. The steps of these two operations are clearly illustrated by six pictures. The operation is indicated in resistant turbinals touching a fairly straight septum in patients of rheumatic tendency or subject to rose cold and hay fever. Four histories of cases are appended. M. TOEPLITZ.

57. This is a modification of Hartmann's speculum.

KILLIAN.

58. This instrument is devised by the author especially to serve in his method of examination—autoscopy of the larnyx.

MÜLLER.

c.—NASAL SEPTUM.

59. MAYER, EMIL. The Asch operation for deviations of the cartilaginous septum, with a report of two hundred operations. *Med. Record*, Feb. 5, 1898.

60. COBB, C. FRED. Fractures of the nasal bones. *Jour. Amer. Med. Assoc.*, March 12, 1898.

59. Among the 200 operations performed in New York institutions, 39 were operated by ASCH and 35 by MAYER. Among 122 cases observed by Mayer 96 were males and 26 females; the average age of all was twenty years. The steps of the operation, the instruments, and splints are well described and illustrated. The lower segment, if it remains thickened after five weeks, is removed by the electro-trephine or galvano-cautery knife. In a case of recent fracture of the nasal bone with deviation of the septum, Mayer compressed and straightened the septum with the nasal forceps and inserted a splint shaped like a truncated cone. Eighty-five per cent. of the 74 cases operated by Asch and Mayer were cured with perfectly straight septums, the remainder without stenosis. Perforations of the septum of the size of a pin's head occurred in two per cent.

M. TOEPLITZ.

60. COBB holds that by the fracture of the nasal bones the septum is also dislocated from its bony attachments, and that by replacing the nasal bones and holding them from the outside in position by a truss, the septum also becomes straight if supported inside. The truss consists of a spring pressing against the nasal bone, attached to a head band, which is secured by a strap crossing the head and another around the chin. Two illustrative cases are appended. M. TOEPLITZ.

d.—ACCESSORY CAVITIES.

61. KUNERT, A. The differential diagnosis between cysts and empyema of the antrum. *Arch. f. Laryngol.*, vii., 1.

62. WINCKLER. The surgery of the upper nasal accessory cavities. *Arch. f. Laryngol.*, vii., 1.

63. MOURE. The treatment of diseases of the sinuses, excepting the maxillary. *Rev. hebdom. de lar., d'otol.*, xxi., 10, 11, 12.

64. MEGJES, Amsterdam. The treatment of empyema of the antrum. *Monatschr. f. Ohrenheilk.*, No. 1, 1898.

65. HERSFELD, J., Berlin. A simple method of closing and keeping open the artificial opening in the maxillary antrum. *Monatschr. f. Ohrenheilk.*, No. 1, 1898.

66. BRINDEL. Inflammation of the sinuses and bronchopulmonary complications. *Rev. hebdom. de lar., d'otol.*, xix., 6.

67. WAGGETT, E. Radical operation for frontal-sinus dis-

ease. *Proceedings of the Laryngological Society of London*, Jan. 12, 1898.

68. SPIESS, GUSTAV., Frankfort-a-M. The surgery of the sphenoidal sinus. *Arch. f. Laryngol.*, vii., 1.

61. The author believes that cysts of the antrum with purulent contents and empyema of the antrum are often confounded. He concludes: (1) That the mere presence of pus in the antrum is not sufficient for the diagnosis of an empyema. (2) The evacuation of pus through a fistula by means of the air blown in the maxillary opening, and the passage of a probe through a fistula for several centimetres toward the region of the antrum, make the diagnosis of a cyst probable; while (3) the diagnosis is assured when the bony walls are distended, with preservation of the contours. ZARNIKO.

62. Grünwald's methods for opening the frontal and ethmoid sinuses give good cosmetic results, but do not give a sufficiently broad view. The methods of Jansen, Kuhnt, and Killian are open to the same objections. The author has therefore combined Killian's with Roser's method; he has also employed Ollier's and Gussenbauer's methods, and has operated on the most difficult cases with success. A method is described to gain a view of the cerebral surface of the frontal wall. It is often difficult to follow the author's description from lack of diagrams, and literature references of the authors quoted are wanting. ZARNIKO.

63. MOURE distinguishes three forms: (1) intermittent mucopurulent secretion; (2) constant purulent secretion with chronic inflammatory swelling and polypi; and (3) granulations and sequestra with the production of fistulous perforations. The treatment is not new. For the mild cases irrigations are employed. In the other cases a free outlet for the pus must be obtained and the diseased mucous membrane directly treated. In the case of the frontal sinus he employs Luc's method.

ZIMMERMANN.

64. Advocates an alveolar antrum canula with valve-like closure. KILLIAN.

65. HERSFELD uses a rubber cork of conical shape with a flattened head to keep open the artificial antral fistula.

KILLIAN.

66. The histories of two cases where an antrum empyema existed with suspicion of phthisis, and one case where both diseases existed. ZIMMERMANN.

67. WAGGETT performed Luc's operation. The cavity was completely cleared of all the mucous membrane, which was throughout polypoid. The drainage-tube was removed on the thirteenth day. No pus was seen after the operation.

ARTHUR CHEATLE.

68. The author has devised an electro-motor probe-trephine to open into the sphenoid cells and which cannot enter too deep.

ZARNIKO.

e.—TUMORS.

69. MARTHA. Statistical investigations on mucous polypi in the nasal fossæ of the child and the adult. *Ann. des mal. de l'or., du lar.*, xxiv., 1.

70. TISSIER. Tumors of the nose and the sinuses. *Ann. de l'or., du lar.*, xxiv., 1.

71. PIERCE, N. H. The so-called bleeding polyp of the septum. *Jour. Amer. Med. Assoc.*, Feb. 19, 1898.

72. NICHOLS, JAMES E. Sarcoma of the nasal passages. *New York Med. Jour.*, Jan. 8, 1898.

73. GLASGOW, W. C. Angioma of the nose. *New York Med. Jour.*, Jan. 8, 1898.

74. SWAIN, H. L. Nasal and other polypi. *New York Med. Record*, March 12, 1898.

75. BALL, J. B. Case of fibro-sarcoma of the nasal septum. *Proceedings of the Laryngological Society of London*, Nov. 10, 1897.

76. HOPKINS, F. E. A case of adeno-carcinoma of the nose. *Arch. f. Laryngol.*, vii., 1.

77. WRIGHT, JONATHAN. Papillary œdematous nasal polypi and their relation to the adenoma and adeno-carcinoma. *Arch. f. Laryngol.*, vii., 1.

69. During four years 133 cases of nasal polypi were observed at Pereire's clinic; of these only 2 occurred in children under fifteen. The latter cases are briefly described. The polyp was situated in the middle meatus. ZIMMERMANN.

70. A comprehensive and complete review of all the published cases, with remarks and references. ZIMMERMANN.

71. CASE 1. A boy, aged six, presented a tumor of the size of a large pea, projecting from the left side of the septum at the junction of the triangular cartilage with the vomer, which had

recurred after operation. It was a fibroma polyposum fungoides teliangiectoides.

CASE 2. A girl, aged fifteen, had also such a tumor of the left side of the septum, which did not recur after second removal and subsequent cauterizations. These tumors are more frequent about puberty. M. TOEPLITZ.

72. CASE 1. Male, aged thirty-nine, presented, October 7, 1893, tumor in right nostril pressing against septum and middle turbinate, the left filled by posterior growth and occluding middle meatus. In naso-pharynx it is broadly attached to the vault and sphenoid body and fills the left choana and most of the right. The right eye is bulging and the right antrum Highmori seems involved. Attempts at removal by scraping, tearing, and snaring failed. Electrolysis reduced pains and exophthalmus. The tumor was a round and giant-celled sarcoma. Aug. 28, 1894, attempt at placing the galvano-cautery snare around the tumor unsuccessful. Seiler's gauze chisel is then worked around the tumor from either nostril and the rest evulsed from the naso-pharynx with large adenoid forceps, whereupon the anterior wall of the sphenoid sinus together with the sphenoid body comes away. The cavity is then scraped post-nasally and through the anterior nares with the sharp spoon. Sept. 12th, free breathing established. October 27th, the tumor is of the same size as before operation. The nose is now split in median line to the tip, the nasal bones are separated from their maxillary attachment, and the posterior nares plugged. The masses are removed from the nasal cavity, and the ethmoidal cells and sphenoidal sinuses are cleared out. Patient made a good recovery. In May, 1894, the tumor had recurred more in the right side. By Dieffenbach's incision the right superior maxilla was exposed, the bone separated and broken down. The eye was removed. The dura mater was found exposed by the tumor extending through the superior orbital plate. Rapid recovery. January 16, 1895, growth had rapidly increased, filling right maxillary cavity, cheek, orbit, and external auditory canal and behind angle of jaw. Toxines of erysipelas and bacillus prodigiosus of no avail. The pharynx was then filled out down to epiglottis and the masses protruded out of the side of the neck. Death, June, 1895. No autopsy.

CASE 2. Aged twenty-seven, after removal of polypi from left nostril, face became swollen and exophthalmus more marked.

Nov. 20, 1895, an incision was made in a line from lower part of nose to the eye. The outer wall of Highmore's antrum removed, the antrum, sphenoidal cells, and orbit curetted. Four days later, erysipelas and abscess; after three weeks otorrhœa. January 15, 1896, recurrence of growth. Death after six weeks.

CASE 3. Aged sixteen. Abscess in left temple near the eye, right eye pushed forward. After subsidence of abscess, swelling in the region of Highmore's antrum, protruding into cheek and mouth. Abscess healed. Offensive odor from right nostril, which was occluded by dense mass, pushing the septum over to the left. Round-celled sarcoma. Operation refused.

CASE 4. Girl, aged seventeen. Feb., 1893, left nostril occluded by dense tumor, pushing the septum over to the right and extending from the vestibule to posterior edge of vomer. Myxo-sarcoma. It is removed through the nostril with snare and sharp spoon, the external nasal wall destroyed, the maxillary antrum exposed, and the ethmoidal cells implicated. Curettement. The patient is free for six months. November, 1893, naso-pharynx is obstructed, recurrence in sphenoidal regions and nasal cavity. After incision in median line, all sinuses, except the frontal, are curetted. The patient is in good condition for a year. Sudden rapid recurrence of large extent, also into both orbits. She died from asphyxia due to extension of the tumor into the larynx. No autopsy. M. TOEPLITZ.

73. GLASGOW'S patient, a female, aged twenty-two, presented a so-called bleeding polypus in the left nostril of the size of a hazel-nut at the locus Kiesselbachii, which was removed with the cold snare, but returned to the same size in five months. Cauterization with chloracetic acid after second removal cured the condition permanently. It was an angio-myxo-fibroma.

M. TOEPLITZ.

74. The frequency of polypi in the nose is due to hypertrophic catarrh and pus, which produces granulation tissue, and, from it, polypi, identical with the œdematous nasal fibroma. The development is minutely described, as it is observed on the middle turbinal from the beginning granulation tissue, while in the septum it becomes cicatricial. The pendulous, white hypertrophies on the inferior turbinate region are denser, containing more fibrous tissue, glands, and blood-vessels. The polypi are due to inflammation and hypertrophy of the mucous membrane, and finally depend upon the constitution of the individual.

They are a symptom, not a disease. In extensive growths the periosteum becomes involved, and later the bone itself, which finally is rarefied. There exists a proliferating ostitis or, in some instances, the opposite, viz., a rarefying ostitis. The inferior end and sometimes the larger portions of the middle turbinate body, therefore, ought to be removed.

M. TOEPLITZ.

75. BALL'S patient, a woman, aged twenty-five years, complained of epistaxis and obstruction of the nose on the left side for three or four months; both symptoms noticed for two or three months on both sides. No pain. On examination each passage found to be blocked almost completely by a smooth pinkish mass presenting in the upper part of vestibule, and attached to cartilaginous septum. Left ala turned up, and growth removed, with certain amount of cartilaginous septum, by Swinford Edwards. Tumor size of walnut.

ARTHUR CHEATLE.

f.—FOREIGN BODIES.

78. CARRUTHERS, S. W. Removal of foreign body from the nose after twenty-three years. *British Med. Jour.*, Feb. 12, 1898.

79. SIMONSON. A case of foreign body in the nose. *Deutsche med. Wochenschr.*, No. 6, 1898.

80. MARKUSE. Foreign bodies in the nose. *Deutsche med. Wochenschr.*, No. 6, 1898.

78. CARRUTHER'S patient was a woman, aged thirty years, who fell down at play when seven years of age, and on rising felt there was a stone in her nose. Symptoms had been present ever since: occasional epistaxis; free muco-purulent discharge which was occasionally fetid, and the feeling of something in the nose, with pain on hard blowing. At eleven years of age a polypus was removed, and again at thirteen years and twenty-seven years. One day, after stooping and blowing, the stone was felt to shift its position more than usual, and was then removed.

ARTHUR CHEATLE.

79 and 80. SIMONSON removed a piece of sponge from the nose of a girl, four years old; MARKUSE, a barley grain from the nose of a patient. In both cases a fetid discharge from the nose was present.

NOLTENIUS.

g.—OTHER AFFECTIONS OF THE NOSE.

81. GOODALE, J. L. An etiological study of atrophic disease of the upper air passages, based upon an examination of 200 cases. *Jour. Amer. Med. Assoc.*, Feb. 26, 1898.

82. HECHT, H. Ozæna. (Göttingen Ear Clinic.) *Münch. med. Wochenschr.*, No. 7, 1898.

83. SCHEIER. Diphtheria of the nose. Reprint of the *Bibliothek der gesammten medic. Wissenschaften.*

84. SCHEPPEGRELL, W. Case of recurrent headache, each attack being relieved by the discharge from the cranial cavity through right nostril. *Jour. Amer. Med. Assoc.*, Feb. 26, 1898.

85. BABER, CRESWELL. Nasal hydrorrhœa. Analysis of liquid. *Proceedings of the Laryngological Society of London*, Jan. 12, 1898.

86. SPENCER, W. G. Trigeminal neuralgia relieved by turbinectomy. *Proceedings of the Laryngological Society of London*, Jan. 12, 1898.

87. WILLIAMS, P. WATSON. Formative osteitis (leontiasis ossium). *Proceedings of the Laryngological Society of London*, Jan. 12, 1898.

88. GRADENIGO. A case of congenital bone occlusion of the right choana. *Ann. des mal. de l'or., du lar.*, xxiv., 3.

81. GOODALE classifies the genuine cases of atrophic rhinitis into the non-fetid, fetid, and pharyngeal atrophy. He arrives at the following conclusion: both fetid and non-fetid atrophies are more than twice as common in females than in males, while pure pharyngeal atrophy occurs with nearly equal frequency in both sexes. Both fetid and non-fetid atrophy begin mostly between the ages of five and fifteen, while the pure pharyngeal form was not found before twenty, and occurred regularly from that age up to seventy-two. In four per cent. of the non-fetid and in twenty-six per cent. of the fetid cases, the atrophic symptoms were increased during the catamenia. In all forms three quarters of the cases showed good health. Distinct hypertrophy of the neighboring portions of the nasal mucous membrane occurred only in isolated instances among the fetid and non-fetid cases, while among the pharyngeal cases it was found in about half of the total number. Hypertrophy of the pharyngeal tonsil occurred in twenty per cent. of the non-fetid, in seven per cent. of the

fetid, and in ten per cent. of the pharyngeal atrophies. Hypertrophy of the faucial tonsils was observed with equal frequency among the three forms, viz., in about twenty per cent.

M. TOEPLITZ.

82. After a discussion of the etiology and especially of the bacteriology of the subjects, two cases are described which were treated with copper electrolysis and the nasal douche. In the severe cases there was no noteworthy result, in the milder case there was some improvement, which persisted after two months.

SCHEIBE.

83. SCHEIER describes a primary and a secondary form of nasal diphtheria. In 262 cases of diphtheria the nose was affected in 50, of which 38 terminated fatally. (It is not stated whether these had been treated with the antitoxin.) The treatment consists in general treatment (serum therapy) and the most careful removal of the membrane and cleansing of the nose. The irrigation should be gently done with a rubber bulb every two to four hours. The removal of the membrane in the 50 cases observed by Scheier was followed by severe hemorrhage, necessitating packing. Especially with the serum therapy active local treatment should be avoided, as the irrigations are very apt to set up an otitis media. During the serum therapy the membrane comes away very soon of its own accord. H.

84. The patient, a sister of a religious order, suffered from agonizing headaches, which occurred in attacks lasting from three to four days, recurring in less than two weeks. During one attack she fell down a flight of stairs, striking the head against a stone jar, became unconscious, and when revived, found the headache disappeared after a discharge of yellow watery fluid from the nostrils, which also returned at the end of each successive attack. Opening of the sphenoid, frontal, and ethmoidal sinuses and catheterization of Highmore's antrum was of no avail. The examined fluid resembled the cerebro-spinal fluid and the contents of the cranial lymphatic vessels. SCHEPPEGRELL believed the condition to be due to a cyst connected with the efferent vessel of the perivascular lymphatics surrounding the vein passing through the foramen cœcum from the nose to the longitudinal sinus. M. TOEPLITZ.

85. BABER'S case was as follows: A married lady, aged forty-two years, complained of a profuse non-fetid watery discharge from the right side of her nose. Five years before, after eight

months' excessive watery discharge following influenza, she had had a polypus removed; the secretion then stopped, but returned at Christmas, 1896, after another attack of influenza. A polypus was removed in May, 1897, but the discharge continued. When first seen by Baber on June 16, 1897, there was no obstruction, very little sneezing, no pain, only the profuse discharge which continued night and day. The right side was much narrowed by deflection of the septum, and the mucous membrane sodden and catarrhal in appearance. No polypus, but a little irregularity on the middle turbinated body. Transillumination showed both infra-orbital regions light, and nothing came out of the right antrum on laying down the head. The fundus was normal in both eyes. No loss of sensation in the right nasal cavity. Spirit and cocaine spray was tried, but without effect; the dripping of watery fluid continued constant, and on one occasion (July 17th) 70 *ccm* were collected in five minutes. On this date the constant current (eight cells) was applied externally to the nose. This stopped the secretion for a few minutes. Patient was ordered to use it for five minutes twice a day. In a week's time (July 24th) she reported that the running was rather less in the mornings.

A small piece of projecting mucous membrane was snared from the middle turbinal, but only proved to be hyperplasia of normal tissue. A 20 per cent. solution of menthol in paroleine was ordered to be sprayed into the nose twice a day, in addition to the constant current applied externally. Sept. 15th, patient reported that a month previously the running began to diminish, and had got so much less that she only used two handkerchiefs a day instead of twelve. Treatment continued. Oct. 5th, no watery discharge at all for last four days. Much less swelling of the mucous membrane. Used spray and galvanism once a day for three weeks. Nov. 3d, no discharge at all since last visit. Treatment omitted. On Jan. 3d, 1898, reported no return of the trouble.

Examination of one ounce of the fluid was sent to the Clinical Research Association for report.

	Per 100 cc.	
Organic solids	0.160	gramme
Containing mucin	0.060	"
" proteids	0.025	"
Undetermined	0.075	"
	0.160	"

	Per 100 cc.
Inorganic solids.....	0.880 gramme
Containing sodium chloride.....	0.770 "
" calcium phosphate, etc...	0.110 "
	0.880 "

Microscopical examination showed the presence merely of a few squamous epithelium cells and a few leucocytes.

Baber thinks that, from the absence of head symptoms, and especially from the beneficial effect of the constant current, the liquid in this case was simply an excessive secretion from the nasal mucous membrane, and not an escape of cerebro-spinal fluid. ARTHUR CHEATLE.

86. SPENCER's case was that of a man, aged forty-six. In April, 1897, after an attack of influenza, he was suddenly seized with severe pains in the face; the neuralgia involving all the branches of the fifth nerve. Opium and morphine in large doses gave some relief. A speculum could not be inserted into the left nostril, on account of hyperæsthesia, until he had been given an injection of morphine. The interior of the left nose showed no definite disease, but on touching the anterior part of the middle turbinal a severe paroxysm of pain and itching was set up; after applying 20 per cent. cocaine this part could be touched without producing the symptoms. The middle turbinal was removed. Nothing abnormal was present in the tissue removed. No pain since operation, but has at times itching in the distribution of the terminal ends of the fifth on the face and at the back of the eye and nose. ARTHUR CHEATLE.

87. WATSON WILLIAMS showed a specimen of the septum nasi and a portion of the frontal and left malar bones from a man, aged forty-six years. There was no history of syphilis, and no known cause for the disease.

Post-mortem examination.—Large, smooth bony thickenings on either side of the nose, and a smaller boss on the left side of the forehead. On removing the cranium pus was found between the dura mater and the bone over the frontal lobe, the pus apparently having come from the left sinus which was full. The frontal sinus on the right side was obliterated by soft cancellous bone. The nose showed that the sphenoidal sinus and ethmoidal cells were entirely obliterated by cancellous bony growths. The

cavity on the left side was almost entirely filled up by growth from the septum. The antra of Highmore were apparently completely filled up by cancellous bony formation. ARTHUR CHEATLE.

88. In a man of eighteen years, post-rhinoscopically, a reddish funnel-shaped membrane was seen to completely occlude the right nasal passage 1 *cm* in front of the choana. The two choanæ were alike, the right half of the soft palate was somewhat dependent. Deafness was present on the right side, due to catarrh of the Eustachian tube; no loss of smell, and no hyperæsthesia. The occlusion was perforated with a trocar, and the opening was packed. Treatment not concluded.

ZIMMERMANN.

h.—NASO-PHARYNX.

89. HESSLER, Prof., Halle. On the time of operation and the various methods of removing the pharyngeal tonsil and the palatal tonsils in acute otitis media. *Monatschr. f. Ohrenheilk.*, No. 2, 1898.

90. MOURE. Adenoids in adults. *Rev. hebdom. de lar., d'otol.*, xix., 5.

91. DENKER. A new instrument for the removal of adenoid vegetations. *Arch. f. Ohrenheilk.*, 1898, vol. xliv., p. 97.

92. ARDENNE. Chronic abscess of the vault of the naso-pharynx. *Rev. hebdom. de lar., d'otol.*, xix., 7.

93. MUSSON, E. E. Observations on some pathological conditions of the naso-pharynx. *Jour. Amer. Med. Assoc.*, March 5, 1898.

89. HESSLER recommends the early removal of the adenoids in cases of acute otitis media, *i. e.*, when the inflammation is abating. KILLIAN.

91. An instrument like a pair of scissors with a web-like arrangement to catch the fragments. The remnants are then removed with the finger. Subsequent irrigation with borated solution for a month. BLOCH.

92. An otherwise healthy man suffered from stenosis of the nose for one year. The nasal passages appeared normal; the septum was slightly deflected. The soft palate, of usual color, was pushed forward. A round, smooth red tumor occupied the naso-pharynx, and was attached above and to the sides. On palpation, greenish pus was evacuated. The abscess-cavity was

enlarged, irrigated, and the patient recovered. On microscopic examination there were no evidences of tuberculosis or bone necrosis, and the abscess was supposed to have formed in an occluded follicle. ZIMMERMANN.

93. The first group of cases comprises 34 patients with hypertrophy of Luschka's tonsil taken from the last 230 cases of the office. Their ages were from fifteen to forty years. The second group of seventeen cases showed a marked change in the ratio between uric acid and urea excreted. The third group were cases of acute follicular naso-pharyngitis concomitant with acute lacunar tonsillitis. In 50 per cent. there was congestion of Luschka's tonsil with follicular exudate, in 40 per cent. of the remaining cases, congestion without it. The three appended cases represented: (1) a purulent inflammation of the naso-pharynx, appearing in a student of the bacteriological laboratory, twenty-four hours after he had broken a test-tube with a culture of streptococci; (2) a purulent inflammation of the naso-pharynx followed by empyema of both frontal sinuses and the left antrum Highmori in a patient just recovered from acute rhinitis, contracted from opening cases of ostrich feathers in a raw state; and (3) acute adenoiditis in a physician exposed to diphtheria or acute pharyngitis. M. TOEPLITZ.

i.—SOFT PALATE, PHARYNX, AND MOUTH.

94. SPENCER, W. G. Separation of old-standing adhesion of the soft palate to the pharynx. *Proceedings of the Laryngological Society of London*, Nov. 10, 1897.

95. KELLY, A. B. Large pulsating vessels in the pharynx. *Glasgow Med. Jour.*, Jan., 1898.

96. RICHARDSON, C. W. Chronic abscess of the tongue. *Jour. Amer. Med. Assoc.*, Feb. 26, 1898.

97. FREUDENTHAL, W. Salivary calculi. *Jour. Amer. Med. Assoc.*, Feb. 26, 1898.

98. PLICQUE. Pharyngeal tuberculosis in children. *Ann. des mal. de l'or., du lar.*, xxiv., 3.

99. GOODALE, J. L. The absorption of foreign bodies by the palatal tonsils in relation to the development of infectious processes. *Arch. f. Laryngol.*, vii., 1.

100. PELTESOHN, F. Angina and rheumatism. *Arch. f. Laryngol.*, vii., 1.

94. A syphilitic middle-aged woman; soft palate completely united to back wall of pharynx. Great pain in ears and over mastoid processes; and collection of muco-pus which could not be expelled through the nose. SPENCER detached the soft palate, which was then drawn forwards and fixed by two silk sutures to the muco-periosteum of the hard palate. Sutures cut out in about a week. Separation then kept up by passing full-sized nasal bougies, and by stretching the soft palate by means of an aneurism needle under cocaine. Pain in ears lost. Breathing through and blowing of nose easy. ARTHUR CHEATLE.

95. KELLY relates four cases. In two, a man aged seventy-five years, and a woman aged seventy-two years, the condition was exactly similar. A large pulsating vessel projected from the angle between the posterior and right lateral walls of the pharynx; it emerged from the posterior wall about the level of the upper border of the epiglottis and ascended vertically, becoming gradually more prominent. When opposite the upper part of the tonsil, where its convexity was most marked and its pulsation best seen, it curved outwards and disappeared in the tissues at the side of the naso-pharynx. The vessel was as thick as a pencil, and extended laterally over a considerable part of the posterior wall of the pharynx. Pressure over the large vessels on the right side above level of the upper border of the thyroid cartilage checked pulsation.

In the third case, a man aged seventy-two, a large vessel emerged from the left half of the posterior wall of the pharynx on a level with the attachment of posterior pillar, and curved upwards and outwards, passing behind the upper part of the pillar.

In the fourth, a woman aged twenty-two, there was marked pulsation behind both posterior faucial pillars. The condition caused no symptoms in any of them. Perry saw Cases 1 and 4, and reported the vessels in both corresponded to the convexity of an abnormal bend of the internal carotid. Kelly thinks Cases 1, 2, and 4 were of this nature, and as a possible embryonic origin has not been made out, he thinks the condition to be a change associated with advance in life.

Reference is made to the importance of the condition as regards tonsillotomy and incising for peritonsillar abscess.

ARTHUR CHEATLE.

96. The first case occurred in a clarionetist, aged twenty-three, with abscess under the tongue, in which the stone was

found in the duct, and after its evacuation another in the substance of the submaxillary gland. The second patient, aged forty-five, presented a steadily growing swelling under the tongue of two and a half years' duration. The removal was declined by the extremely stout and alcoholic patient, who died several weeks later from suffocation. The majority of stones grow around a foreign body. In a third patient, aged fifty-seven, a small piece of wood was found in the centre of the stone. The patient had been in the habit of chewing toothpicks. Stones may be washed out by salivations with pilocarpine. The submaxillary gland is more frequently the seat of calculi, owing to the more adhesive qualities of the mucin contained therein.

M. TOEPLITZ.

97. A girl, aged eighteen, presented in the centre of the dorsum linguæ anterior to the papillæ circumvallatæ an oval elevation, which had been noted since early childhood. It caused no disturbance, and was considered as a cyst. Ten days after the discharge of the patient from treatment, intense earache, soreness in lateral walls of pharynx, pain by pressing upon the tumor set in, which, when opened, evacuated several drachms of very offensive, thin, watery pus. Complete recovery.

M. TOEPLITZ.

98. PLICQUE reviews the two principal forms of pharyngeal tuberculosis in children: the primary, progressive ulcerous, and the secondary form with the formation of a fibrinous pseudomembrane. ZIMMERMANN.

99. The author injected the lacunæ of hypertrophic tonsils with a carmine solution. The tonsils were then removed, fixed in sublimate, and examined in serial sections. The interval between injection and operation varied from twenty minutes to ten days. Conclusions: (1) Absorption takes place normally in tonsils and through the mucous membrane of the lacunæ. (2) The absorbed material passes through the follicular lymph spaces in the direction of the larger connective-tissue bundles. (3) During the process of absorption the foreign particles are subjected to the phagocytic action of the multi-nuclear neutrophiles which are situated near and in the mucous membrane. (4) Bacteria are normally to be found in the lacunæ, though cannot generally be demonstrated in the tonsillar tissue. ZARNIKO.

100. This is a complete and well written review of this subject which has frequently been discussed of late. The following

conclusions are reached: angina lacunaris, acute articular rheumatism, muscular rheumatism, and some of the accompanying skin lesions are allied diseases with a more or less similar etiology. They are caused by microbes, presumably attenuated bacteria of pyæmia. The infection is aided by certain diseased conditions of the nose and the throat. Unfavorable social and hygienic conditions, bad ventilation and drainage, low water-level, diminished alkalinity of the blood, exhaustion, and constipation aid.

ZARNIKO.

BOOK NOTICE.

The Year-Book of Treatment for 1898. A Critical Review for Practitioners of Medicine and Surgery. Philadelphia and New York: Lea Brothers & Co.

This is the fourteenth annual issue of an English review, introduced in this country by the above firm. It is a compilation of the annual progress in therapeutics on 484 small-octavo pages, concisely but well printed, with indexes of authors and subjects. The different chapters are entrusted to men of established reputation. The extracts of the original publications are succinct, but not meagre, and embrace a very wide field, not only remedies and operations, but constant references to diagnosis and indications, and not without fearless criticism; for instance, on page 170 we find the following: "*Asepsis usque ad absurdum!* The latest development of the aseptic craze hails from Breslau, where Mikulicz now operates in gloves, and with a wet towel tied over the lower half of his face, similar precautions being also insisted on for his assistants," etc.

The book should not only be recommended to the general practitioner, but to the specialist, who has a particular need of such an annual reminder of the progress in the principles and applications of the additional means of healing the sick, in order to be prevented from slipping into narrow specialism. Eye and ear surgery have their particular chapters in the book, but very valuable contributions on both are found also in other chapters: for instance, Leutert's excellent article on Lumbar Puncture in the Complications of Ear Disease is in the chapter on nervous disease, page 61; Landolt's article, "Obstruction of the Lachrymal Duct in

New-born Children" (published in the *Annales de Gynécologie et d' Obstét.*), is in the chapter on midwifery. By the way, the reviewer begs to differ with his colleague and friend, Landolt, who "advocates sounding of the duct with a fine probe; on no account should the canaliculus be slit." The probing is not only very troublesome, if at all possible, but perfectly superfluous, as according to the reviewer's experience the lachrymation and inflammation disappear when the tear duct in the natural development of the cavities of the skull attains its proper calibre. The chapter on mastoid disease and its complications is, as in previous years, particularly good. The full extract, or rather the whole, of Prof. Panas's learned paper, "Auto-Infection in the Eye," should not only be read by ophthalmologists, but by the general practitioner, as it gives a very lucid exposition, illustrated by the behavior of so delicate an organ as the eye, of a general principle of pre-eminent scientific and practical importance. Altogether the reviewer's opinion is that the *Year-Book*, or something similar to it, fairly complete, yet not too bulky, should not only be in the hands of, but read by, every practitioner, general or special. H. K.

edies, and instruments, and to discuss in a progressive, yet conservative spirit all questions of present importance.

The ARCHIVES contain exclusively original papers on all branches of Ophthalmic and Aural Surgery, and original reports on the progress of Ophthalmology and Otology throughout the world. The original papers occupy about three-fourths of the space, and their scope embraces all subjects of scientific and practical interest in the departments of Ophthalmology and Otology.

Special attention is paid to the preparation of the Reports on the Progress of Ophthalmology and Otology. These Reports are intended to furnish *complete, systematic, and early reviews* of the current Ophthalmological and Otological literature of the world, and the work of preparing them is divided among a specially selected number of collaborators.

Under the heading of "Miscellaneous Notes" there will be published all kinds of professional news that concerns the Oculist and Aurist, *e.g.*, appointments, honors, resignations and vacancies, new ophthalmic and aural hospitals, prize questions and essays, announcements of Society meetings, etc.

Each volume contains besides a specified table of contents, an index of subjects and authors, both of the original papers and the reports, and a general index of the preceding seven years is added to every seventh volume.

Original papers of value from any source are solicited.

Communications for the English edition of the ARCHIVES OF OPHTHALMOLOGY should be addressed to DR. H. KNAPP, 26 West 40th Street, New York, those for the ARCHIVES OF OTOLOGY either to DR. H. KNAPP, or to DR. U. PRITCHARD, 26 Wimpole Street, W., London, England.

G. P. PUTNAM'S SONS, Publishers

NEW YORK — 27 & 29 WEST 23D STREET.

LONDON — 24 BEDFORD ST., STRAND.

PUBLISHER OF THE GERMAN EDITION

I. F. BERGMANN

20 Schwalbacher Strasse, Wiesbaden.

EDITORIAL NOTE.

In asking for continued support of the ARCHIVES from subscribers and contributors, the Editors offer no new program, but point to the record of the work that has been accomplished during the past twenty-eight years. At the first appearance of the ARCHIVES in 1869, they constituted the only periodical of their class in America, and had only a few predecessors in Europe. The international character of the ARCHIVES was a novel and distinctive feature.

The original program of the ARCHIVES to publish only original papers in semi-annual independent numbers has, in the course of years, been extended by the addition of reviews of the current ophthalmological and otological literature.

With the eighth volume, in 1879, the combined ARCHIVES, issued semi-annually, were divided into two separate journals, issued quarterly, and each of about the same size as the combined journal, and the reviews were converted into quarterly reports, systematic and comprehensive, though concise, on the progress of ophthalmology and otology.

Since that date, the ARCHIVES have developed into an extensive and conveniently arranged storehouse of knowledge for the instruction of the student and for reference by the practitioner and the investigator.

For more than ten years, the valuable material offered to the ARCHIVES has been so abundant that it has not been practicable to utilize for the English edition the full series of papers from the German, or the converse. Many articles had to be abridged, while of others abstracts only could be printed. Any one of our readers could, however, have secured, and can secure in future, from the American editor, or the German publisher, the loan of the original papers presenting the complete text.

It is the purpose of the editors to arrange, in the department of Reports, for the review of every publication which in their opinion contains material that can be called distinctive and important. It is, of course, impossible, within the limits of the ARCHIVES or of any similar journal, to give attention to every publication in their department of science. We may state further that it is not a part of our program to furnish a complete report on the *bibliography*, but only on the **progress** of ophthalmology and otology.

Though the systematic arrangement of the reviews is of importance for reference and comprehensive information, we shall publish, as early after the meetings as practicable, reports of the proceedings of societies, always bearing in mind that the ARCHIVES are not intended to be only a repertory of knowledge, but also a journal of news.

It is natural that the English edition of the ARCHIVES should give the advantage of time and space to Anglo-American contributors over the German, and *vice versa*. It is evident, however, that the association of the two editions lends strength to each, furnishing to the authors a wider circulation for their papers, and to the readers a larger and more diversified field of information.

NOTICE TO CONTRIBUTORS.

The editors and publishers of the ARCHIVES beg to offer some suggestions to authors who propose to favor them with their contributions.

1 As original communications the ARCHIVES can accept only such papers as have never been printed nor are intended to be printed in other journals. If a preliminary communication on the subject of a paper has been published, the author is requested to state this in the letter accompanying his manuscript. It is understood that contributors to these ARCHIVES and editors of other periodicals will make no abstracts of the original papers published in this journal without giving it due credit for the same.

2. Authors will receive gratuitously twenty-five reprints of their articles. If a greater number is desired,—notice of which should be given at the head of the manuscript,—only the additional cost of presswork and paper will be charged to the author.

3. In preparing manuscript for the compositor it is requested that the following rules be adhered to:

a. Write on one side of the paper only.

b. Write without breaks, *i. e.* do not begin a new sentence on a new line. When you want to begin a new line or paragraph at a given word, place before it in your MS. the sign ¶.

c. Draw a line along the margin of such paragraphs as should be printed in smaller type—for instance, all that is clinical history in reports of cases, etc.

d. Words to be printed in *italics*, should be underscored once, in SMALL CAPITALS twice, in LARGE CAPITALS three times.

4. Authors may receive proofs for revision if they will kindly return them without delay. We beg however to remind our contributors that changes in the copy are equivalent to resetting, causing so much additional expense. We therefore request them, to make, if possible, no alterations at all in their MSS., or, at least, to limit these to what is of essential importance.

CONTENTS OF VOLUME XXVII., NUMBER 5.

PAGE

1. Escape of Cerebro-Spinal Fluid through the Nose, in Conjunction with Atrophy of the Optic Nerves, Probably Caused by the Perforation of the Wall of the Sphenoidal Sinus by a Tumor of the Hypophysis. By Prof. **O. Körner,** Rostock, Germany. Translated by Dr. EDW. PREBLE, New York 397

2. Two Cases of Pachymeningitis Externa and Extradural Abscess Occurring in Acute Mastoid Disease. By Dr. **Hermann Preysing** (Assistant). Translated by Dr. E. PREBLE, New York . . 404

3. Two Cases of Mastoid Disease of an Uncommon Character. By **Robert Lewis,** Jr., M.D., New York 409

4. The Onset of Inherited Syphilitic Deafness. By **Urban Pritchard** and **Arthur Cheatle** 415

5. The Most Important Cases of Middle-Ear Suppuration Treated in the Military Hospital at Warsaw in the Year 1896. By Dr. **Th. Heiman,** Warsaw, Russia. Translated and Abridged by Dr. EDWIN M. COX, New York 421

6. On Cartilaginous Interglobular Cavities in the Capsule of the Human Labyrinth. By Dr. **Paul Manasse,** Strassburg. Translated by ADOLPH O. PFINGST, M.D., Louisville, Ky. (With Plates I. and II. of Volume XXXI. of German Edition) . . 438

7. The Affections of the Ear in Acute and Chronic Bright's Disease. By Dr. **J. Morf,** Winterthur, Switzerland. Abridged and Translated by Dr. ARNOLD H. KNAPP, New York 444

8. Chloroma in the Temporal Region. By Prof. **O. Lubarsch,** Rostock, Germany. Translated by ADOLPH O. PFINGST, M.D., Louisville, Ky. 450

PAGE

9. Report of the Seventh Meeting of the German Otological Society at Würzburg, May, 1898. By Dr. **Seligmann**, of Frankfort-on-the-Main. Translated by Dr. JAS. A. SPALDING, Portland, Me. 459

Scheme for uniformity in testing the hearing of the diseased ear. By Barth, Leipzig, 459.

On a uniform nomenclature for the results obtained by testing the functions of the ear. By Bloch, Freiburg, 460.

Determination of the hearing in correct proportions. By Bezold, 460.

Acoustic communications for solving physiological and practical questions in otology; demonstration of apparatus and methods. By Dennert, 460.

On the theory of hearing. By Beckmann, 461.

Otology and deaf-mutism. By Passow, 461.

The development of the labyrinth in the *Torpedo ocellata*. By Hellmann, 462.

On the reflex excitability of the tensor tympani by waves of sound. By Ostmann, 462.

Tuberculous tumor of the auricle. By Strauss, 462.

Otitis media in infants. By Hartmann, 463.

I.—Apparent embolic affection of the ear; II.—Ocular paralyses and middle-ear suppuration; III.—Anchylosis of the stapes, with exhibition of a specimen. By Habermann, 463, 464.

Secondary labyrinthine alterations in primary epithelial carcinoma of the middle ear. By Manasse, 464.

An intratympanic tumor. By Jansen, 464.

I.—Sequestrum containing the facial canal; II.—Acute middle-ear suppuration with rupture through the labyrinth into the cavum cranii. By Panse, 465.

Rupture into the inner ear in acute middle-ear suppuration. By Scheibe, 465.

Demonstration of anatomical and pathological conditions in the ear. By Katz, 466.

I.—Neoplasm on the auricle; II.—Treatment of otitis externa acuta. By Haug, 466.

On the relation of hypertrophied pharyngeal tonsil to tuberculosis. By Brieger, 466.

Melancholia as the result of an otitic extradural abscess. By Biehl, 467.

Tinnitus aurium. By Panse, 468.

Experimental investigations on massage of the ear. By Ostmann, 468.

The operative treatment of stapes anchylosis. By Noltenius, 468.

A case of isolated thrombosis of the bulb of the jugular vein; and a case of sinus and jugular-vein thrombosis. By R. Hoffmann, 468.

On the treatment of stapes anchylosis. By Dundas Grant, 469.

Malignant tumors after chronic middle-ear suppuration. By Kirchner, 469.

Transplantation of skin in the radical operation. By Jansen, 469.

Injuries to the ear from detonating balls. By Wagenhäuser, 469.

Demonstration of instruments. By Beckmann, 469.

10. Miscellaneous Notes 470

11. Contents of the Latest Numbers of the German Edition of these ARCHIVES (*Zeitschrift für Ohrenheilkunde*) 472

ARCHIVES OF OTOLOGY.

ESCAPE OF CEREBRO-SPINAL FLUID THROUGH THE NOSE, IN CONJUNCTION WITH ATROPHY OF THE OPTIC NERVES, PROBABLY CAUSED BY THE PERFORATION OF THE WALL OF THE SPHENOIDAL SINUS BY A TUMOR OF THE HYPOPHYSIS.[1]

By Professor O. KÖRNER, Rostock, Germany.

Translated by Dr. Edw. Preble, New York.

CONSTANT dripping from the nose of a limpid fluid having the composition of the cerebro-spinal liquid, and bilateral atrophy of the optic nerves, together with a striking degree of weakness of the limbs, were the most noteworthy phenomena in the following case, which was observed at my clinic. As I find in literature some eight cases in which "hydrorrhœa nasalis" was associated with bilateral atrophy of the optic nerves, it has seemed to me that the course of these mutually corresponding cases should be given prominence as a particular disease-entity, and that the causation of this peculiar syndrome should be sought for.

Miss F. K., aged thirty-seven years, was brought to the clinic on April 8, 1896. She was said to have been deformed since her tenth year, and for some eight years had swayed and staggered in walking. She had formerly been a tailoress, but had been unable to work for several years on account of weakness of the eyes and hands. Some four months prior to her admission at the clinic, and following a cough and coryza, the limpid fluid already mentioned began to trickle from her left nostril. This nasal discharge persisted uninterruptedly day and night. When she was in the dorsal position the fluid ran into the throat and was swallowed.

[1] From the Clinic of Diseases of the Ear and Throat, University of Rostock.

The patient was small and thin, of slender build, and pale complexion. She had a considerable kyphoskoliosis. Her mental capacity appeared to be slight. She smiled a good deal without apparent occasion, but gave clear and correct replies to simple questions. For the most part she sat quietly, and held a handkerchief or a glass under her dripping nose. She could not walk unaided, and when left unsupported while walking, she lurched toward the nearest object in order to sustain herself. Her movements were not ataxic; it appeared to be only a question of great weakness in her legs.

The limpid fluid dripped continually from the left nostril. This was collected at various times and amounted to about 15 *ccm* per hour. Professor Nasse's examination showed solid constituents to be 1.18 per cent., ashes, 0.75 per cent.; the loss by heating .43 per cent., was probably albumin. Mucin was not demonstrated to a certainty, owing to the slight amount of the fluid tested. The ashes contained a large percentage of sodium chloride. In the right side of the nose nothing abnormal was discovered. In the left side there was a considerable hypertrophy of the anterior extremity of the middle turbinated bone.

With regard to the eyes, there was a slight prominence of the bulb, globe and rotatory nystagmus. The right pupil was of normal width, the left was somewhat dilated. The right pupil reacted well to light, the left hardly at all to direct, but well to consensual light. Slight insufficiency of both interni existed. In the right eye vision was $\frac{5}{5}$, but with the left, the patient could count fingers only when they were held close in front of the eye. Professor Berlin established the presence of pronounced bilateral atrophy of the optic nerve.

The temperature was normal, pulse 90–100, respiration 20.

The patient could be kept under observation for a short time only, so that justice could not be done to the case; many points, therefore, concerning which information was desirable were not investigated, because we were not conversant with the literature of similar cases. It is certain that there was no inflammation of the thyroid gland, for we had been attentive to this possibility; the prominence of the bulbus oculi had for a moment suggested Basedow's disease. We could not give an opinion as to whether or not there was thyroid atrophy. Acromegaly was out of the question, because the hands and feet were very finely formed. The sensibility of the skin and patellar reflexes were tested, and,

to the best of my recollection, were found normal; in the clinical history, a mention under this head is wanting.

Unfortunately our observations could not be completed. In reply to my request to bring the patient to us, the father wrote that she died September 5th, four and a half months after the period of observation. The nasal discharge had increased toward the last, and cough and pulmonary râles had set in. There was no autopsy.

The origin of the fluid remains enigmatical. All that could be seen was that it dripped from the middle turbinated bone. The quality and quantity underwent no change, even after removal of the turbinate hypertrophy. A microscopical examination of the excised tissue showed only ordinary hypertrophy. Puncture of the left antrum through the inferior meatus brought forth no fluid.

According to its composition the nasal fluid could have been a thin, catarrhal secretion—such as occurs in vasomotor coryza,—as well as cerebro-spinal fluid. In the chapter on "Disturbances of the Olfactory Function, of the Sensibility and the Secretion of the Nose," in Heymann's *Handbook of Laryngology and Rhinology*, I have thoroughly discussed the various kinds of watery discharge from the nose—such as are comprised under the term hydrorrhœa nasalis; and will therefore not enter further into this subject.

It seems to me that I came across the only possible explanation of this case in reading a dissertation by Gutsche (*vide infra*). The latter described a tumor which had broken into the sphenoidal sinus. The patient, aged thirty-four years, and apparently in perfect health, experienced for two months before his death a constant dripping of a watery fluid from the left nostril, which persisted until his death. In the recumbent position the fluid ran into the throat. About 250 *ccm* were secreted daily. Death was due to meningitis. The rupture of the tumor into the sphenoidal sinus had paved the way for the escape of the cerebro-spinal fluid. Unfortunately an ophthalmoscopic examination was not made; but in the autopsy the left optic nerve was found compressed by the tumor, and of a grayish hue, while the

right nerve was gray in a small area. Now it seems to me that in my case as well, there is no more approximate solution at hand than the assumption of the extension of a tumor of the hypophysis in the sphenoidal sinus, with escape of the cerebro-spinal fluid; for thereby we may at once comprehend the bilateral atrophy of the optic nerve, which is a frequent symptom of tumors of the hypophysis. The peculiar personality of the patient, and the weakness of the limbs are symptoms which are likewise not infrequent in tumors in that locality. In a survey of the literature, I find in Schuster's Inaugural Dissertation on tumors of the brain (Münich, 1886), a description of a case of sarcoma of the hypophysis with the following remark: "The few days during which our patient was free from pain coincided probably with the escape of fluid through the corroded place in the sphenoid bone." Other accounts of hypophysis-tumors, so far as they are accessible to me, nowhere contain any mention of hydrorrhœa nasalis. However, I found in literature, along with Gutsche's case already quoted, no fewer than eight observations of nasal hydrorrhœa in connection with atrophy of the optic nerves and other symptoms which occur in tumors of the hypophysis. An autopsy was made in only one of these cases (Baxter, *vide infra*), which was limited to the brain, and at which the cause of death was not discovered. It is there stated that there was nothing abnormal in the accessory cavities of the nose. Nothing is said concerning the hypophysis. This negative result of an incomplete autopsy does not weigh very heavily against the positive finding of Gutsche; but it shows that the most careful investigation of every similar case is particularly desirable in the future. I have found in literature the following eight cases which likewise show the complex of symptoms just described.

1. BAXTER. A case of paroxysmal clonic spasm of the left rectus abdominis, with symptoms pointing to the existence of gross intracranial disease. *Brain*, vol. iv., p. 525, (Jan., 1882).

Female, aged thirty-five. At first headache, then a watery dis-

charge from the right nostril, tinged at times with blood. The pain was centred in the right half of the nose and radiated over the temple. On both sides optic neuritis with limitation of the field of vision. Attacks of clonic spasm of the left rectus abdominis. Three years after the commencement of the disease convulsions set in, death following in coma. Autopsy (*v. supra*).

2. GUTSCHE. Zur Pathogenese der Hypophysistumoren und über den nasalen Abfluss sowie das Verhalten des Liquor cerebrospinalis bei einer Struma pituitaria.

For report see the text.

3. HARDY and WOOD. Two cases of nasal hydrorrhœa. *New York Medical Journal*, vol. ii., Sept. 6, 1890, p. 264. Case 1.

Female, age forty-three. Sunstroke in July, 1881. Since that time attacks of violent pain in the vertex of the head. Since September, 1881, intermittent watery discharge from the nose, at first with redness of the conjunctiva and severe lachrymation. During the past two and a half years, there had been a daily nasal discharge, which began when the patient rose in the morning and persisted for three to four hours, being present but rarely at night. Dropping from both nostrils. In October, 1898, the acuteness of vision diminished, and in November there was a transitory central scotoma. Slight swelling of the turbinated bodies. Movements of eye and pupil normal, symmetrical narrowing of visual field, great pallor of the right papilla, and on both sides an atrophic segment of a circle at the lower, posterior margin of the papilla. Portions of the middle turbinated bone were removed, and belladonna and oxide of zinc were given internally, but no permanent benefit was obtained.

4. LEBER. Graefe's *Archiv für Ophthalmologie*, Bd. 29, Th. i., p. 273.

Girl with congenital hydrocephalus, physical development very backward, mental normal. From her fifteenth year disturbed vision, attacks of vertigo, epilepsy, and headache. Bilateral optic-nerve atrophy. Five years later watery discharge from left nostril,

of from 4 to 22 *ccm* hourly. Density, 1008; reaction, alkaline; contained sodium and potassium chlorides, traces of sulphuric acid, and a proteid substance. Later, discharge from right nostril.

5. NETTLESHIP. *Ophthal. Rev.*, January, 1883, p. 1.

Female, twenty-five years, headache (which came on suddenly), weariness, verbal amnesia, muscular weakness—especially on left side; later, exophthalmus with diminished vision. Sixteen months afterwards watery discharge from left nostril, which diminished a month later. Atrophy of both optic papillæ with narrowing of visual field, especially laterally.

6. PRIESTLEY SMITH. *Ophthal. Rev.*, 1883, p. 4. Case I.

Male, twenty-eight years. After smallpox, violent headache and vomiting, followed soon by blindness. Headache persisted. Four years later watery discharge from left nostril. Whenever the discharge subsided severe cerebral symptoms set in (increase of headache, somnolence, lethargy). Improvement when flow returned. These attacks were progressively more severe, and at last convulsions set in. Bilateral optic-nerve atrophy. Density of fluid, 1007. Death two years after the appearance of the nasal discharge. No autopsy.

7. PRIESTLEY SMITH, l. c., Case II.

Male, twenty-two years. During his eighteenth year, headache set in, and also (suddenly) an attack in which he lost consciousness and fell forward. Convergent strabismus then appeared. Disturbed consciousness during several months, delirium, headache, vomiting, blindness. Bilateral optic neuritis, with atrophy of nerve later. For fifteen months total paralysis of lower extremities. Two and a half years after the attack, watery discharge from nose, right side. A few months later, polypus on right side, discharge from left side. In twenty-four hours 300–350 *ccm*. If the flow ceased, patient felt a pain between the shoulders, which radiated toward the base of the brain.

8. MACKENZIE WALLACE. A case of atrophy of the optic nerves with dropping of watery fluid from the left

nostril. "Transact. iii., Session Intercolonial Medical Congress. Sydney, June, 1893. Review in *Centralbl. f. Laryngologie*, Bd. xi., p. 67.

Male, aged twenty. Suffered from blindness and continual watery discharge from the left nostril. Disease had begun three years earlier with diminution of vision, marked headache, and certain seizures during which patient fell as if in a swoon. A year later there began a discharge from the nose, and simultaneously there was a cessation of the seizures, which moreover did not return. Nothing abnormal was demonstrable in the nose or its sinuses. The amount of fluid was 30 *ccm* hourly. Density, 1006. Chlorides and traces of sulphates and potassium present.

The *fundamental features* of the disease, so far as they can be recognized from the nine recorded cases, appear from the following data:

Sex; four males, five females. Age, 20–43, on average, 29 years. Amount of fluid in twenty-four hours, 250–720 *ccm.* Density, average, 1006.

Brain symptoms: headache, in six cases; vomiting, twice. Disturbances of sensorium, five times. Verbal amnesia, once. Weakness of all extremities, once; of one side, once; of both legs, once. General convulsions, in three cases; local spasms, once.

Ocular changes: bulbi prominent, twice; strabismus, twice. Rotatory nystagmus, once. Bilateral atrophy of optic nerves (partly with limitation of visual field), eight times clinically, and once anatomically established.

The disease began with cerebral symptoms six times, with eye symptoms twice, with nasal discharge once.

It was stated in three cases that the cerebral symptoms increased with cessation of the nasal discharge, and decreased when the flow was re-established.

Termination: in five cases unknown, four deaths, recovery once.

Duration of disease in fatal cases, from two months to eight years: average, four years and three months.

Duration of nasal discharge in fatal cases, from two months to two years; average, eleven months.

TWO CASES OF PACHYMENINGITIS EXTERNA AND EXTRADURAL ABSCESS OCCURRING IN ACUTE MASTOID DISEASE.[1]

By Dr. HERMANN PREYSING (Assistant).

Translated by Dr. E. Preble, New York.

Case 1.—H., teacher, aged seventy years, visited the clinic December 29, 1897, on account of severe pain within and behind the right ear, which symptom had been present for two weeks.

For the space of a few days during this period the ear was said to have suppurated, but this symptom had again subsided. Both ears had originally been healthy; patient could not give any particular occasion for the present affection.

The patient was vigorous for a man of his years; there was nothing abnormal to be found in the thoracic and abdominal organs, and he was free from fever. The posterior border of the right mastoid process was sensitive to pressure, but was not distinctly swollen. The membrana tympani of the same side was a little reddened and convex, and the outlines of the malleus were indistinct. A swelling of the postero-superior wall of the auditory meatus was apparent.

Paracentesis, made immediately, revealed a serous collection in the tympanum, but without a trace of pus.

During the following night (December 29th) the patient, whose temperature was still normal, experienced very severe pain which he referred particularly to the anterior aspect of the vertex and to the depths of the right ear. The lower half of the right antrum pit was on the succeeding day still more tender to pressure, and there was pus in the auditory meatus, while the swelling in the wall of the latter had increased. On this account the right mastoid process was at once chiselled open.

[1] From the clinic of Diseases of the Ear and Throat, University of Rostock.

The periosteum was found to be unusually thickened, and the bone was strikingly yellow. In the mastoid fossa numerous apertures of dilated vessels were visible. During the procedure of chiselling and removing the posterior wall of the auditory meatus, an abscess was nowhere encountered. The bony tissue was found to be compact, and was discolored yellow in its deeper layers. The hemorrhage from the bleeding points increased as the bone was more deeply penetrated. In the vicinity of the region of the sinus were a number of small cells filled with granulations, and surrounded by carious bone; in these granulations were embedded small, yellow nodules of pinhead size. The posterior cerebral fossa was slightly perforated by further chiselling. Immediately pus in jets issued from the small opening. The opening was enlarged, and the sinus found to be covered with granulations and pulsating actively. As collapse set in, no further effort was made to lay bare the antrum.

On the afternoon of the same day (December 30th) patient's temperature was normal, he was cheerful and good-humored, while next morning he had toothache in all the lower teeth. Dressings were changed, and no sign of retention found. The tampon from the meatus was somewhat moistened by pus along its middle, but the end which had been in contact with the membrane was dry.

On January 1, 1898, condition was good; on the following day, however, pain reappeared, and on this account a furunculous spot at the posterior upper wall of the meatus was incised.

On January 3d the pain again increased, and redness and œdema appeared in the vicinity of the operation-wound.

On January 7th, eight days after the first operation—the patient was anæsthetized—the old operation-wound was enlarged, and certain cells which were filled with pale granulations, and situated toward the apex, were removed with chisel and curette. The small, yellow nodules were still to be seen in the granulations (anatomical investigation showed ordinary granulation-tissue rich in vessels). The sinus was covered with apparently healthy granulations. It was further laid open by the removal of carious bone, and showed throughout a granulated surface. Pulsation was no longer visible. As there was no fever, and as the tympanum contained no pus, there was no occasion to open the antrum.

After the second operation the pain vanished, the general con-

dition improved, the ear remained dry, and after six weeks of treatment the patient was discharged in the best of health on February 9th. The fundus oculi was normal throughout; in both eyes commencing cataract to be seen (Dr. W. Schmidt).

CASE 2.—F. L., aged five years, was brought to the clinic December 23, 1897. The only history obtainable was that during the previous summer the child had an eruption of crusts and scabs, which occupied the entire surface and lasted for a week. Eight days before admission the patient was said to have had fever, headache, and earache on the right side. Three days before admission her parents noticed swelling and tenderness in the region behind the right ear (the ears had never suppurated).

The child was in poor condition, was badly nourished, with cold, pallid skin; pulse irregular and weak (frequency, 64); temperature in the rectum, 37.7°; mind apparently clear. The surface of the entire right mastoid process was infiltrated; there was no swelling in the jugular region. The right membrana tympani was reddened and convex.

Paracentesis of the right membrane was performed at once with evacuation of a serous exudate in slight quantity (upon the next morning there was pus in the meatus).

As the general condition showed no improvement, the operation of chiselling into the right mastoid process was performed upon the day following the paracentesis. A perpendicular incision was made at the highest level of the infiltration about 1 *cm* behind the concha, and carried down to the bone. An angular incision was then made to the rear. When the periosteum, easily lifted off, was pushed backward, pus gushed forth in abundance from the vicinity of the mastoid process; pulsating blood was mingled with it. The first stroke of the chisel at this spot laid bare some blackish-red granulations. The cranial fossa was laid open in all directions with the bone-forceps exclusively. The bone was softened and hyperæmic in places. No suppuration or granulations. The outer surface of the bone showed small blood-points, and was discolored gray in a high degree. The affected region in the dura was 1 *cm* in diameter, sharply defined, projecting about 2 *mm* above the surrounding level and having the appearance of foul granulations; its centre corresponded nearly to the exit of the mastoid emissary. The surrounding dura was dirty-blue in color and hyperæmic. The entire surface laid open was about 3 *cm* in diameter. In probing the granulated area there was felt

at a slight depth the same resilient resistance and the same cerebral pulsation as on the neighboring dura, where no granulations were present. The pulse during the operation was stronger and more frequent than before (about 76). The antrum was not examined, because the tympanum had contained only serum, and because the diseased bone did not extend sufficiently in that direction.

After the operation paralysis of the abducens was noticed on the right side; the pupils were wide but of the same size, and reacted promptly.

On the day after the operation (December 25th) the general condition was improved. The child coughed a good deal, but there was nothing particular to note in the lungs. The patellar reflexes were present, and there was no paralysis apart from that of the abducens.

On the third day after the operation (December 27th) the dressings were changed for the first time. The wound looked well, and pus was nowhere visible. The granulating spot on the dura was smaller; the granulations themselves were flatter.

On the fourth day after the operation the child was unusually cheerful; she laughed and took nourishment. A slight but distinct protrusion of the bulbus oculi was associated with the abducens paralysis. It was possible to examine the fundus oculi for the first time, and a marked choked disk was found on both sides, especially the right.

On the seventh day after the operation the three corners of the wound were closed with secondary sutures, leaving a small space in the middle.

Recovery was thenceforth uniform. On January 30th (thirty-seven days after the operation) patient was discharged cured. The wound was completely closed, and the osseous defect covered with healthy skin and scar-tissue. Over the defect a distinct pulsation could still be felt. The membrana tympani was closed and the malleus recognizable. Examination of fundus oculi on the day of discharge (Dr. W. Schmidt) showed "on both sides distinct distension and tortuosity of the veins, diminution of vessels in the margin of the papilla, optic disk somewhat protuberant." The abducens paralysis had disappeared.

Remarks.

There existed in both cases pachymeningitis externa and

extradural abscess, in consequence of very brief disease of the mastoid process, which had not led to noteworthy destruction. In both cases the tympanum contained serum, and connection of the disease with the antrum was not demonstrated. The first thought is that these cases might have been examples of bone infection not originating in the mucoso-periosteal lining of the air-cells. This view finds a certain degree of support in the case of the teacher (Case 1) on account of the presence of a probably relapsing furunculosis in the meatus. An infection of bone from this latter source is at least possible. The unusual condition of the bone in this case illustrated that but little known disease—**acute inflammation of the compact osseous portion of the mastoid process.**

TWO CASES OF MASTOID DISEASE OF AN UNCOMMON CHARACTER.

By ROBERT LEWIS, Jr., M.D., New York.

Case 1.—Cholesteatoma, Complicating a Bezold's Mastoiditis, successfully operated upon by the Schwartze-Stacke Method.

The patient, a female, twenty-five years of age. consulted Dr. A. H. Buck on the 28th of February, 1898, and gave the following history:

When three years of age she had an attack of acute catarrhal otitis media independent of any of the exanthemata or other acute disease. The condition lapsed into a chronic purulent otitis media, the discharge being allowed to go on for three years before the patient received any treatment from the hands of the aurist. Then for a year she remained under treatment, but, according to her belief, received no benefit. On this account, and because she suffered so much at each visit of the physician, treatment was discontinued. In time the discharge became less constant, and for some years back it had apparently ceased for a time, to be followed by pain and a renewal of the discharge, with relief from pain in a few days. Then, after another period of several weeks or months, the discharge would again cease.

When seven years of age, the patient swallowed a pin, and in her fourteenth year an abscess appeared about an inch below the tip of the mastoid process. This ruptured, and in the discharge a rusty pin was found. The abscess healed after a time.

On the 3d of December, 1897, she "took cold," as a result of which she experienced severe pain in the ear, as also pains throughout her body. A week later an abscess appeared at the site of the old pin abscess and ruptured. The discharge from this was very offensive and most profuse. In the vicinity of the mastoid, and radiating upwards and forwards, the pain was very intense.

When Dr. Buck first saw the case, on the 28th of February, 1898, there was some tenderness on pressure over the mastoid, and about an inch below the tip of the mastoid process was a small pouting ulcer, from which exuded a thin serous pus. Upon exploration with a probe, the instrument passed upwards towards the tip and into the mastoid for a distance of over two inches. The external auditory canal was much inflamed and stenosed; an ulcer existed on its posterior wall, through which a probe passed directly into the mastoid process.

Dr. Buck kindly referred the case to me. I operated on the 4th of March. The cortex was thin and easily removed; and beneath it, and occupying the whole mastoid process, was a large **cholesteatoma** as large as a large-sized olive. When this had been removed, an opening was found extending through the digastric groove and communicating with the ulcer on the neck. This was opened throughout its entire length and thoroughly scraped.

The mastoid process was found to be converted into a single large cavity, all the partitions being broken down. A spot, which measured about two by three millimetres, was eroded in the floor of the middle cerebral fossa, and a similar spot existed in the bony wall of the sigmoid sinus. The ossicles and membrana tympani had been destroyed. It was necessary for me to remove the entire posterior and superior bony wall of the external auditory canal. After removing all suspicious bone, I was about to make the Panse skin flaps, when my patient showed signs of heart failure. The attempt to make these flaps was therefore abandoned. Simple dressings were applied and the patient was placed in bed. I was surprised and gratified to find that no injury had been done to the facial nerve.

During the next week the patient improved sufficiently to enable me to finish the operation. On the 14th of March she was anæsthetized; the whole surface of the mastoid cavity was curetted, nothing but granulation-tissue being removed. The membranous external auditory canal was divided into a posterior and an anterior flap. The latter, of course, I did not disturb; the posterior one I turned at right angles and united with sutures to the posterior flap of the mastoid wound, and then united the edges of the mastoid incision. Iodoform gauze was inserted into the large cavity made up of the external auditory canal, middle ear, and mastoid cavity. On my patient's recovery from the

effects of the ether, I found that I had not been so fortunate this time in escaping the facial nerve: the bony canal must have been exposed, and in my efforts to scrape away the granulations I must have wounded the nerve.

Since the operation the patient's general health has rapidly improved; she has been free from pain, and the paralysis is very slowly improving. I have hopes, as also has Dr. Auzal, under whose care she now is for the paralysis, that it will eventually disappear. The cavity has become lined with epidermis throughout. I had the usual trouble with the granulations, which sprang up from the walls of this cavity; they had to be cauterized and curetted, and it seemed as if at times no headway could be made against them. I found that aristol, dermatol, and nosophen seemed to irritate the skin granulations; at all events, on one occasion, I resorted to finely powdered boric acid, and found on the next visit a marked improvement in the appearance of the skin surface. At the end of one week, after the use of the boric acid had been begun, the skin had grown over two thirds of its whole surface. In another similar case, which I had under my care a few years ago, I found after trying many remedies and after many weeks of treatment, that there was one small spot which resisted all attempts to coax it to skin over, and it was not until I used an ointment of ichthyol that I succeeded in causing it to become permanently healed.

Case 2.—Tuberculous Extra-dural Abscess. Operation. Death.

The patient, a female, twenty-four years of age, gave me the following history:

From the time she was four years of age, she had had (following an attack of measles) an almost constant discharge from the left ear, at times profuse, then again scanty. During the past few months, the discharge has been very offensive and profuse. Three weeks ago, she began to suffer from a dull aching pain in the temporal region, which has steadily grown worse, and has extended so as to involve almost the entire left side of the head. At times it has been so unbearable that her physician could give her relief only by the administration of morphine. Two weeks ago, a paralysis of the facial nerve occurred.

On examining the ear, I found the canal to be filled with a very offensive and cheesy discharge. On cleansing the ear as thoroughly

as possible, the inner third was seen to be filled with a polypus. This was removed under cocaine anæsthesia. The membrana tympani and the ossicles were found to be totally destroyed, and dead bone was readily felt in the epitympanic space, and in the aditus ad antrum.

An operation was advised as imperative, but to this the patient would not submit. She was accordingly made as comfortable as possible with anodynes.

Twelve days later I was again requested to call, and found her suffering intensely and in a very weak state. An operation was again advised as the only possible means of affording relief.

The next day the patient gave her consent. The mastoid was opened in the usual way; on removal of the cortex, very offensive cheesy masses were encountered; these extended into the antrum and the epitympanic space. All suspicious bone, including the tip of the mastoid process and the upper posterior wall of the external auditory canal, was removed, and the exuberant granulations in the middle ear were destroyed. Exploration with the probe revealed the existence of an opening in the tympanic roof, and through this the instrument was passed a distance of over an inch into the middle cerebral fossa. The original incision was then extended in a vertical direction upwards, and with a half-inch trephine (its vertical pin being placed about one inch above the middle of the external auditory canal). I removed a button of bone. Then with the rongeur forceps, I extended this opening downwards and backwards as far as the opening which I had made in the cortex of the mastoid process. At the same time I cut through the tympanic roof. By this means free access was obtained to the superior surface of the petrous portion of the temporal bone. When I lifted up the dura I encountered an abscess of the same cheesy consistency as that which I had found in the mastoid process. It extended inward along the superior surface and close to the posterior border of the petrous portion of the temporal bone. (The contents of the abscess were examined the next day by Doctor James Ewing, who reported the presence of numerous tubercle bacilli.) The abscess wall was thoroughly scraped, and as no further sinuses were found, and the dura seemed to be firm and non-inflamed, although thickened, no further operative interference was thought to be necessary. No sutures were used; the wound was packed with iodoform gauze.

On the following day, the patient was found to be in a comfort-

able condition and free from pain. Forty-eight hours later, a tendency to drowsiness became manifest. It was necessary to awaken her whenever it was thought best to administer nourishment, or whenever it was desired to obtain an answer to a question. This drowsiness rapidly increased, so that, on the third day following the operation, it was decided to search for a possible brain abscess. Her temperature at the time stood at 100.8 F.; there had been no chills.

At five, P.M., on the 7th of January, three days after the first operation, she was again placed on the operating table. After consultation, we decided that it was preferable to use ether as an anæsthetic. The dressings were removed, and I was about to make a further exploration of the wound, which was clean and healthy, when the patient suddenly stopped breathing. The head was at once lowered, and artificial respiration was employed. In a few moments the patient gave a sigh and respired, but only this one voluntary effort was made. Strychnine, in combination with atropine, was administered hypodermatically, and oxygen inhalations were also employed. The faradic current was applied over the pneumogastric nerve. But the moment artificial respiration was discontinued, the patient became more and more cyanotic, and the heart more and more feeble. The cyanosis would immediately disappear and the heart-beats grow strong, as soon as artificial respiration was resumed. This was continued for about two hours without a change. The fact that the pupils were widely dilated made it evident that a source of increased intracranial pressure existed, and accordingly I concluded that no harm would result from an exploration of the brain, and possibly I might succeed by this means in reaching the source of pressure. I therefore incised the dura and introduced an aspirating needle in various directions into the brain tissue, which seemed to be somewhat softened, but I failed to discover any pus. Some fluid, evidently from the lateral venticles, was removed. This was followed by a contraction of the patient's pupils to normal proportions, and also by spontaneous breathing, which lasted, however, only for about four minutes. The rate of the spontaneous respirations was about five per minute; then the breathing again ceased, and artificial respiration was again resumed.

I was inclined to explore the cerebellum, but as this would make necessary further incisions and trephining, I desisted. About 10.15, P.M., her heart commenced to grow weak, and

in another fifteen minutes it stopped beating. The patient was kept alive for nearly five hours by means of artificial respiration.

Unfortunately an autopsy was not allowed. Since the operation, I have wondered whether death might not have been due directly to the ether narcosis. It was my first impulse, when I began to operate in this case, to use chloroform instead of ether, but finally decided against the use of the former.

THE ONSET OF INHERITED SYPHILITIC DEAFNESS.

By URBAN PRITCHARD and ARTHUR CHEATLE.

THE modes of onset in this disease receive but slight description by authors, yet on careful investigation into the history of each case, interesting facts may be elicited which we venture to think are of importance not only in rendering classification possible, but also in helping to throw some light on the pathological process.

Broadly speaking the modes of onset may be divided into two main groups:

(i.) Without giddiness.

(ii.) With giddiness.

The first is certainly the more usual; the history being that deafness came on gradually, first in one ear, the other, sooner or later, following suit without giddiness, the eye symptoms closely preceding the aural. As a rule, when the patient presents himself, other signs of inherited syphilis (teeth, eyes, etc.) are well marked, so rendering the diagnosis perfectly easy; but occasionally these other signs are but slight, or even altogether absent, the diagnosis resting on an insidious internal-ear deafness coming on between the ages of eight and twenty-five years, which history we think is pathognomonic of the disease, all other possible causes having been excluded. The eye symptoms do not always precede those of the ear, for we meet with cases where the reverse has occurred; this reversal of the eye and ear symptoms must always be present in one's mind if mistakes in diagnosis are to be avoided.

With regard to the pathology of this group: a more or less slow process must be present in the labyrinth, which process does not affect the equilibration-portion, being confined entirely to the purely auditory portion of the nerve and its terminals. A chronic ostitis has been described as occurring in inherited syphilis, leading to the gradual and more or less complete occlusion of the cavities of the internal auditory meatus and bony labyrinth; such a process would seem to account for the symptoms. The symptoms closely resemble those which occur, in one form at all events, of labyrinthine disease due to tertiary acquired syphilis; and Politzer states, in reference to this acquired tertiary disease, that "recent investigations show, without a doubt, that in the old cases an osseous growth from the periosteum takes place owing to the chronic inflammation of the lining of the labyrinth."

It may be that the cases in group I have identically the same pathology as in the tertiary acquired form—in other words, the disease is a tertiary form occurring in inherited syphilis. That inherited syphilis may take on a typical tertiary form, as seen in the acquired form, is amply shown by the ulceration of the throat, which is not unfrequently seen in children suffering with the inherited form.

The second group, according to our experience, is decidedly uncommon. Politzer quotes Kipp, who described cases combined with parenchymatous keratitis and iritis in which the symptoms were sudden deafness, vertigo, disturbances of equilibrium, subjective noises, naso-pharyngeal catarrh, and sometimes also catarrh of the middle ear. The following cases illustrate this group; it will be seen that the onset may be acute, subacute, or chronic:

CASE I.—M. M., a boy, aged fifteen years, was brought on account of deafness in the right ear on September 16, 1896; the history being that six weeks previously he had been suddenly attacked with severe giddiness and vomiting, the former lasting a week, the latter two days. On the third day deafness was noticed in the right ear, and this deafness had remained absolute ever since. The father was doubtful as to whether he had had

syphilis. The patient was the eldest of three; he had suffered with "bad eyes" a short time previously; but this trouble was stated by an eminent ophthalmic surgeon to have been more of an ordinary phlyctenular than of a syphilitic nature. For four or five years the boy had suffered with general enlargement of lymphatic glands, especially of those in the neck, for which he had undergone various treatments without much benefit.

A 15-inch watch was heard normally on the left side, but not at all on the right.

The tuning-fork tests demonstrated internal-ear deafness in the affected side.

Blistering behind the ear, and a mixture containing pot. iod. and arsenic, were ordered.

He was seen periodically during the following three months; no real improvement occurred.

On January 13, 1897, ulceration and swelling of the left tonsil and posterior faucial pillar being found, mercury and pot. iod. with a nitrate of silver paint and Condy's Fluid gargle were ordered. Under this treatment the throat rapidly cleared up, and the general enlargement of the glands greatly diminished.

This mode of onset is exceedingly rare in the inherited but comparatively common in the secondary stage of the acquired form. It resembles what may be called a fulminating Ménière's attack, and can best be accounted for by a sudden and great increase of tension affecting the whole of the labyrinth, and destroying at once the terminals of the labyrinthine nerve endings. An exudation identical with that which occurs in the eye seems to us to be the most probable explanation.

CASE 2.—E. D., male, aged twenty-eight, presented himself on account of extreme deafness; the history being that at the age of eighteen years the deafness had become complete in two months during marked attacks of giddiness.

Signs of old interstitial keratitis were present in each eye; and the left upper central incisor was notched.

In this case the symptoms were those of subacute Ménière's disease; an exudation being perhaps present which was not at first of sufficient severity to destroy at once the labyrinthine nerve endings, but ultimately, either by the constantly increased tension, or by changes in the effusion itself, producing profound alterations.

CASE 3.—A. G., a boy aged eleven years, was first seen on

December 14, 1896. Deafness in both ears was first noticed in the preceding August, associated with attacks of headache and giddiness which were worse on getting up in the morning. Occasionally vomiting occurred after the attacks. His mother had often seen him staggering in his walk towards the left side. Humming, "like an engine at work" was complained of in the right ear. When giddy he sometimes fell forwards, striking his nose or forehead, the ground appearing to rise up and strike him; objects round him appeared to be moving towards one side or the other, most frequently from left to right. He had had two or three attacks during the preceding month.

His mother had never any miscarriages or stillbirths. The patient was the second of four children, the other three being perfectly healthy. No symptoms of disease in infancy. On examination he was a bright healthy-looking boy, relating his symptoms quite accurately. He had never had "bad eyes" and there was no sign of inherited-syphilis beyond very slight pegging of the left central incisor tooth.

The membrane appeared somewhat depressed. Nose and naso-pharynx normal.

A two-foot watch could not be heard on the right side and only on touch on the left.

Tuneing-fork tests demonstrated marked internal-ear trouble.

Giddiness could be elicited by turning the head sharply to the left. Blistering behind each ear alternately and dilute hydrobromic acid in half-drachm doses three times a day were ordered.

December 24, 1896.—One giddy attack during the week. The left ear showed slight improvement, the watch being heard one inch instead of on touch.

December 31*st.*—One giddy attack during the week.

February 11, 1897.—Giddiness has ceased, but patient more deaf.

March 8*th.*—No giddiness, but very deaf, shouting being necessary.

April 8*th.*—Blistering has been kept up all this time. Ordinary loud conversation heard at one foot on the left side, not at all on the right.

May 13*th.*—Keratitis present for the first time, so clearing up the true nature of the case. Blistering still.

April 21, 1898.—Came up for examination after having been in the country for the last five months. Blistering has been con-

tinued up to a month previously. The left ear had markedly improved, low conversation being heard at two feet, the watch at two inches. The right side: shouting heard close to auricle, watch not heard.

Slight occasional vertigo complained of. The active eye trouble ceased. Milder counter-irritation behind ears ordered.

This is an exceedingly interesting case from several points of view. The ear trouble preceded that of the eye by one year and nine months. The only sign of inherited syphilis was the slight pegging of the central incisor. The onset resembled a case of chronic Ménière's disease, the vertiginous attacks extending over a period of one year and four months, the deafness not then being absolute. Blistering certainly produced improvement, arresting the trouble in the right ear, while marked improvement occurred in the left. We think an exudation of a mild degree will most readily account for the trouble.

With regard to the theory of an exudation into the labyrinth corresponding to that which occurs in iritis, Politzer states, in reference to recent labyrinthine affections in acquired syphilis, that it has not been proved that there is a plastic exudation as in iritis, although he quotes a case recorded by Moos (*Virch. Arch.*, vol. lxix., p. 313), where a syphilitic man died who had suffered with intense subjective noises, attacks of vertigo, and later on with considerable deafness, death occurring a year and a half after the onset. At the post-mortem examination the following condition of the labyrinth was found. "Thickening of the periosteum of the vestibule, the foot plate of the stapes raised and immovable. The connective tissue between the membranous and the osseous labyrinth infiltrated with small cells and hyperplastic material. Corti's arches and cells especially considerably infiltrated, the Zona pectinata and the periosteum of the lamina spiralis ossea less strongly infiltrated; the ampullæ and the semicircular canals were alike infiltrated; the auditory nerve normal." Such a condition, we venture to think, points strongly to there having been a plastic exudation corresponding to that which takes place in the iris.

The last case we relate has very much the same history as Moos's, although one is inherited and the other acquired syphilis.

To sum up, then, there are two main forms of onset in inherited syphilitic deafness:

(i.) *Without giddiness*, which runs a subacute or chronic course in which we think the trouble is limited to the auditory nerve and its terminals, leaving the equilibration mechanism intact, and in which a periostitic or ostitic thickening takes place, this condition having its counterpart in one form of the tertiary acquired.

(ii.) *With giddiness*, which may run an acute, subacute, or chronic course; involving the whole of the labyrinthine nerve endings, in which increase of tension due to an exudation, as in the eye, will best account for the symptoms. The resulting deafness being due: in the acute form to an immediate destruction of the labyrinthine nerve endings by pressure alone; in the subacute and chronic cases to a constantly recurring increase of tension and to changes in the exudation itself acting on the labyrinthine nerve endings, this second group having its counterpart in the form seen in the secondary acquired.

THE MOST IMPORTANT CASES OF MIDDLE-EAR SUPPURATION TREATED IN THE MILITARY HOSPITAL AT WARSAW IN THE YEAR 1896.

By Dr. TH. HEIMAN, Warsaw, Russia.

Translated and Abridged by Dr. Edwin M. Cox, New York.

THE cases described in this paper have been drawn from the Warsaw garrison, as well as from several other localities. The proportion of fatal cases has been rather high, and in many of the cases the ear disease was secondary to some other trouble. I shall content myself with describing some of the more interesting and typical cases which I have had the opportunity to observe. I shall add a few critical remarks.

Case I.—**Acute Otitis Media on Left Side—Cerebral Abscess—Operation—Death after Four and one-half Weeks.**

S. P., twenty-five years old, had a left-sided acute inflammation of the middle ear on January 12, 1896, up to which date he had had no such trouble. I saw him in my hospital first on February 3d. There was then a muco-purulent discharge from the ear; the membrana tympani was red, swollen, and had a small perforation; the Eustachian tube was free. Hearing was diminished. The right ear was entirely healthy, and the general condition was satisfactory. On February 18th, the temperature rose suddenly to 39°.2 C., the pulse to 96, and the discharge from the ear was much increased. There was localized pain above the left auricle. After three days all symptoms had abated. On February 28th, the temperature again rose to 38°.5 C., and the patient complained of sharp pains in the ear, and began to look pale, but after two days there was a remission of symptoms. On March 14th, there was again a rise of temperature and some inflammatory in-

filtration in the region of the mastoid process ; and on the following day fluctuation was made out, for which an incision was made down to the bone, and a quantity of thick yellow pus evacuated, after which the temperature fell to normal, and the infiltration disappeared. The wound healed normally and the discharge from the ear stopped. On March 30th, the temperature rose to 38°.3 C., and the pulse was 66 ; there was vomiting and great dizziness, but no headache. The pupils were of normal size and reacted normally to light ; the patient was, however, apathetic and stupid. During the next few days the vomiting was not repeated, but on April 3d there was more vomiting, and constipation became marked ; the pupils were dilated, and reacted only weakly to light ; there was choked disc and increase of the knee-jerk. After twenty-four hours there was some improvement. On April 9th, there was diffuse headache and general weakness, with pallor and apathy. On April 13th, the headache had become a distinctly localized frontal pain, made worse by percussion. The speech was affected, and patient left out words and sentences, and in the sitting or standing position the power of speech was completely lost. On April 18th, temperature was 37°.2, pulse 54. On this day the patient vomited suddenly three times, and was unconscious for ten minutes ; changes in position caused dizziness. Knee reflex almost gone, skin reflexes very weak. Pupils contracted, reaction to light slow. Answers questions satisfactorily, but leaves out some words. Cannot name familiar objects when they are shown to him, but can repeat the names after hearing them. Speaking tires him, and he is drowsy. Moderate paresis of the left facial nerve. April 20th : temperature 36°.6, pulse 62. Names familiar objects incorrectly, *e.g.*, calls sugar bread, etc. Admits that he recognizes objects but cannot name them. Can read print and manuscript.

April 21st, **operation** for supposed abscess of the left temporal lobe of the brain. Chloroform. Curved incision from in front of the ear, over it, and down over the mastoid region. The dura was exposed over a wide area, and was found not to pulsate. Its external surface seemed healthy. Incision in the dura was made in the same direction as the bone opening, and at the depth of 3 *cm* an abscess containing about forty grains of thick yellow pus was found. The walls of this abscess cavity were smooth and it extended downwards. The cavity was treated by packing with iodoform gauze, and the wound sutured at its upper angle. An

incision over the mastoid region showed the bone to be somewhat softened, and the cavities full of granulation tissue, but without pus. After operation the patient was in a semi-unconscious condition. Temperature 37.°6 C., pulse 78. On April 22d, patient can name many objects correctly, and can read print easily. When he cannot name an object he uses circumlocution. Complains of some headache.

April 26th to May 4th, patient remained in a satisfactory condition, and seemed to be progressing favorably.

On May 5th, profuse purulent discharge appeared, coming from the brain surface and the depths of the wound. Patient is again pallid, weak, and somnolent. Some vomiting. The aphasic symptoms again became marked. The pupils became unequally dilated, the left being the narrower.

May 18th, patient was chloroformed, and deep in the temporal lobe an abscess containing about 40 *gm* of pus was evacuated. Patient became steadily worse, and on May 19th died comatose, with high temperature and rapid pulse.

Autopsy, next day, showed purulent infiltration of the pia mater on the left side, with a canal leading into the abscess cavity in the brain substance. The left hemisphere in its lower portion is swollen, the superior longitudinal sinus contains dark fluid blood, and there is much pus in the third temporal convolution. Some prolapse of the brain had occurred, and the cerebral tissue beneath it was softened. Cross-section of the temporal lobe showed an abscess cavity the size of a pigeon's egg, with smooth walls and a delicate capsule. It contained greenish pus. The surrounding brain substance was softened, pale, and œdematous. There was pus in the posterior horn of the lateral ventricle and in the fourth ventricle. The inferior surfaces of the cerebellum and of the pons were also covered with pus.

Lateral sinus empty and its walls thickened. There was a small area of softening in the posterior wall of the sigmoid groove. The middle and internal ear was healthy, the left drum-membrane somewhat thickened. The pus contained streptococci. Nothing abnormal in the other organs.

This case is the ninth case of brain abscess from ear disease seen by the writer, in six of which the diagnosis was

confirmed either by autopsy or operation, and in one of these six the abscess was in the cerebellum.

We may consider the present case one of acute brain abscess from ear disease, with the abscess dating from February 18th, at which date there began the rise of temperature and the increase in the amount of discharge. In making our diagnosis we must also remember the character of the fever, the peculiar pallor of the patient, the varying weakness, with periods of excitement and apathy, to which the patient was subject, and the vomiting, digestive disturbances, and aphasic symptoms. The slowing of the pulse is also of importance. The localization of the abscess might be made out from the fact of ear disease, and from the speech disturbances. The symptoms of brain abscess began at the time when the suppuration in the ear had stopped. Such abscesses following acute inflammation of the middle ear are not common, and therefore such cases are noteworthy. The disturbances of speech were dependent upon the pressure of the pus collection upon the conducting fibres, since operation, and even changes of position affected the ability to speak. The spot of softening in the sigmoid groove, perhaps, furnished the channel for infection from the ear to the cranial cavity. Although this case seemed to be one which should have recovered, the second accumulation of pus and the occurrence of leptomeningitis prevented such a favorable result.

Out of more than one hundred cases of brain abscess from ear disease which have been operated upon, about 50 per cent. have recovered, but unfortunately among this percentage there have been several recurrences with new complications, and in some cases epilepsy, aphasia, or persistent headaches have remained. When we also consider that there is a number of unreported fatal cases, it is evident that the mortality is not a small one.

The manner of opening the abscess is of importance, and the old method of simple puncture is dangerous. The incision should be free, and as v. Bergmann was the first to demonstrate this can be done safely. The cavities should be opened as freely as pus cavities in other parts of the body,

and treated upon the same principles. The danger of hemorrhage in consequence of such a free opening need not be considered, since the tissue about the abscess is usually softened and anæmic, but sometimes a large vessel will be torn. Simple puncture of an abscess does not insure against the occurrence of hemorrhage.

Case 2.—Chronic Suppurative Otitis Media—Periostitis of Temporal Bone—Symptoms of Abscess of the Brain—Recovery.

D. L., twenty-four years old, came to the hospital January 28, 1896, with a chronic right-sided middle-ear suppuration. Examination showed free suppuration, the drum-membrane was reddened and had a small perforation in its lower segment. In the mastoid region there was an incised wound with pale granulations. Hearing in the right ear is much reduced; in the left ear, normal. Patient is pale and weak; no fever; pulse 64. February 3d, severe general headache began, the pupils were contracted, but after a few hours these symptoms disappeared. On February 6th there was a repetition of the headache and some vomiting. Percussion does not increase the headache, and there are no painful spots. Temperature 36°.5, pulse 42. Discharge from the ear has stopped, and the patient felt much better. February 16th, more headache and repeated vomiting. The headache was frontal. During the vomiting the right pupil was markedly dilated; consciousness was entirely retained, and there was no tenderness upon percussion. Changes of position cause dizziness. In the fundus of the eye small hemorrhages are visible, and the papillæ are ill-defined. There is also paralysis of the right facial nerve, increase of the knee reflex, diminution of the skin reflex, and weakness of the left extremities. February 20th: temperature 36°.2, pulse 120. All these symptoms disappeared under the use of tincture of iodine, but in laughing there was some deviation of the right angle of the mouth. On March 7th all the symptoms returned and blepharospasm was added. From March 28th to April 4th patient had headache and vomiting, and part of the time dilated pupils, strabismus, choked disc, and diplopia. April 7th, vision in left eye much diminished. A mixed antisyphilitic treatment was begun, and on April 14th vision in the right eye became decidedly better, and the choked disc had disappeared. Four months later the patient was well but totally blind.

At first this case presented symptoms which seemed to

point to the presence of a large abscess in the temporal lobe, but later such symptoms as hemorrhages into the retina, and the absence of all symptoms at times, made this diagnosis doubtful. The real disease may have been a gumma at the base of the skull in the region of the optic nerves, although acute atrophy of the optic nerves is rare in syphilis. The patient was entirely free from symptoms at times, and at others all were well developed. In cases of brain abscess the patients are never free from some symptoms, but simply have periods of exacerbation and amelioration, and at all times appear very ill. Such cases warn us to be cautious in our diagnosis of brain abscess from ear disease, since there is considerable risk connected with opening the skull, and inflammatory complications are not uncommon. A case much like the one just described occurred in a young officer, twenty-two years old, with a syphilitic history, and a chronic ear suppuration with total destruction of the drum-membrane. He had sudden vomiting, dizziness, and very great pain in the right occipital region, but no fever.

Counter-irritation locally and the internal use of potassium iodide caused all symptoms to disappear promptly. Two days after this all symptoms except vomiting recurred, and I supposed that there was an epidural abscess, but the patient was put upon antisyphilitic treatment, and in a very short time was entirely restored, and remains so.

Case 3.—Chronic Suppurative Otitis Media—Epidural Abscess—Septicæmia—Recovery.

J. N., soldier, aged twenty-two, came to the hospital, December 30, 1895, on account of a left-sided ear suppuration, which had existed for several years. There was a profuse purulent discharge, the drum-membrane had a large, old perforation with callous borders, the mucous membrane of the tympanum was pale, red, and swollen, and the mastoid was tender on palpation. Hearing much reduced on the diseased side. No fever, and general condition good. January 4th there was some fever and headache upon the left side, and an unusual amount of discharge from the ear. There was some rise of temperature from this date until February 26th.

On January 11th there was a well-marked chill, and the headache and tenderness of the mastoid disappeared. Consciousness and muscular action were undisturbed. January 22d, there was pain in the left wrist-joint, and in the left occipital region. Under chloroform a T-shaped incision was made in the mastoid region, and the whole lateral wall of the mastoid from tip to base was chiselled away. The opening reached as far forward as the mastoid antrum, and far enough back to freely expose the lateral sinus. All the bony parts in this region were infiltrated with pus, and from within the cranium there flowed about 20 *gm* of yellow, odorless pus. The dura seemed normal and pulsated at only one spot. A puncture where it did not pulsate brought only blood and cerebro-spinal fluid, and a needle in the sinus also brought only blood. The wound was treated by packing. Two days after operation there was a chill and great general weakness. The wound looked pale, and its edges relaxed.

January 26th, slight chills, but a better general condition. January 29th, very free discharge from the wound, cough, but no interference with motion of head. February 2d, chill, and February 4th, pain in the hip and knee without objective symptoms. Consolidation in the right pulmonary apex.

Between this date and February 27th several joints became inflamed, but did not suppurate; but from the latter date improvement began, both general and local, and by March 29th the wound was entirely healed. The discharge from the ear stopped entirely, and all joint symptoms slowly disappeared.

REMARKS: This case was evidently one of epidural abscess, with septicæmia or septico-pyæmia, but the presence of the abscess was only discovered at the time of operation, and it must be considered as the cause of the general infection since the pain in the left occipital region was present for a long time before the general symptoms. The evacuation of the abscess made the whole course of the disease less severe, but the general infection ran its course. When cases like this one are operated upon, and have, in addition to the local symptoms, signs of general infection, it is a good plan to puncture the lateral sinus, in view of the possible presence of a thrombus which, if found, may necessitate opening the sinus freely. Sometimes there is a thrombus at some other point than the field of operation, and in that case the diag-

nosis may be very obscure. The result of the puncture of the sinus is important from a prognostic point of view. I have become more and more thoroughly convinced that all cases like the one under consideration must be treated as radically as possible, and that if we may hope to save them we must find the focus of infection and remove it. Unfortunately in some cases it is impossible to supply conditions favorable for the cure of a focus of infection in the cranial cavity, and bad results follow. Although it is a fact that in many cases simple chiselling away of the mastoid will relieve the symptoms, we cannot be sure that such a procedure is radical, and it will often prove necessary to open the cranium and expose or even open the lateral sinus. This can be done without much increasing the risk to the patient, and it may prove of great value. There need be no fear of infecting the sinus by puncture. During recent years I have discarded the use of irrigation of the wound at the time of operation, as I have become convinced that in this way the period of healing is shortened. When there is much discharge, however, the dressing must be changed frequently. Partial suture of the wound is also serviceable.

CASE 4.—**Acute Suppurative Otitis Media—Epidural and Temporal Lobe Abscess—Recovery.**

T. N., soldier, twenty-three years old on May 1, 1896, had an acute right-sided middle-ear inflammation. The drum-membrane was reddened, swollen, and perforated in its upper half. The right ear had much diminished hearing. Until May 9th, there was nothing noteworthy in the case. On May 20th, patient began to have pain in the right side of the head, and œdema of the right temporal region. The amount of the discharge was increased and the temperature was 38°.2 C., the pulse 90. A few days later fluctuation was discovered above the auricle and about 25 *gm* of pus evacuated; the bone was denuded of periosteum. The course of the wound was entirely normal until June 14th, when there was sudden and violent headache, dizziness and vomiting. Temperature 38°.8 C., pulse 80. The right pupil was dilated. The symptoms soon disappeared but all recurred in a few days. In the area of denuded bone above the auricle a small spot of softening was found, and through this a small open-

ing into the skull was made with a chisel. About 30 *gm* of pus was evacuated, and the dura found to pulsate. The cavity was treated by packing, and the wound partly sutured. June 19th, temperature 39°.9 C., pulse 96, and patient feels well. Profuse purulent discharge. The cavity eventually entirely healed. The discharge from the ear stopped eight days after operation, and after ten days the perforation in the drum could no longer be seen.

REMARKS: In this case there was an epidural abscess in the middle cranial fossa without previous involvement of the mastoid. Although there was no demonstrable connection between the sub-periosteal abscess and the collection in the cranium, the latter was undoubtedly the consequence of the former. The case is a typical one of subdural abscess in which the diagnosis was not difficult, although the sudden cerebral symptoms seemed to indicate a suppurative leptomeningitis. I believe that this would have occurred if the pus focus had not been evacuated in time, and I am furthermore of the opinion that nearly all cases of diffuse meningitis following otitis with a circumscribed lesion, result from such subdural abscesses.

CASE 5.—Acute Suppurative Otitis Media—Epidural Abscess—Recovery.

A. S., aged twenty-three, entered hospital May 23, 1896, with a left-sided purulent otitis media of three months' duration.

The discharge was profuse, the drum-membrane perforated, and hearing on the left side much diminished. On May 19th, the discharge increased, there was diffuse headache, and some tenderness on percussion of the mastoid. No fever. On June 1st, the headache was distinctly left-sided, there was some dizziness, and the discharge from the ear continued profuse. Vomiting occurred a few times and the pupils were contracted. June 6th, the mastoid was chiselled away and the cranium opened.

The mastoid cells were full of pus and granulation tissue; the dura looked normal and pulsated. A needle puncture brought out a syringe-full of slightly turbid fluid containing a few pus cells. The pain next day was gone, but it soon returned, and a few days later during the dressing of the wound there was a flow of about 30 *gm* of thick pus from the depths of the wound. The subse-

quent course of the wound was normal, and in six weeks it had entirely healed by granulation, except a small communication with the tympanic cavity, and this too was entirely healed in the course of a few weeks.

REMARKS: The persistent left-sided headache, the transitory tenderness of the mastoid, the simultaneous increase in headache, and the amount of discharge, the vomiting, and the dizziness all pointed toward the existence of an epidural abscess, but this was not in evidence at the time of operation for the collection of pus was probably situated posterior to the opening in the skull, and its escape temporarily blocked by the dura mater. It is also a possibility that in this case we had to deal with an intradural abscess well localized. Such abscesses, however, usually cause a rapid leptomeningitis. In our case the operation was necessary and life-saving.

CASE 6.—**Chronic Suppurative Otitis Media—Septico-Pyæmia—Recovery.**

T. E., twenty-four years old, entered hospital March 24, 1896, with a left-sided middle-ear inflammation which had existed since childhood, but had had an exacerbation of three weeks' duration.

His temperature was 39°.5, pulse 86, and there was severe headache, and tenderness all over the head. The mastoid and region of the jugular vein were tender and swollen, and movements of the head painful. Pupils dilated, reacted to light, consciousness undisturbed. Free discharge from the ear, drum-membrane pale, thickened, and perforated. Next day temperature was somewhat higher.

March 27th, **operation** was done in the usual way upon the mastoid. The posterior and lateral parts of the mastoid and the upper posterior wall of the auditory canal were chiselled away.

The tegmen was sound, and the carious head of the malleus was removed. When the sinus was exposed it seemed abnormally resistent and it was punctured, but only dark fluid blood was withdrawn. During the next few days there was some fever and the patient was occasionally delirious, and during the two weeks following the operation there were several chills. It was not until May 31st that the patient was cured, and at the time he was in a very much emaciated condition.

This case was more one of a general septic infection than anything else. The chills, the irregular rise of temperature, with remissions, the occasional diarrhœa or constipation, etc., all indicated such a condition. The operation does not seem to have had any effect upon the course of the disease, and the patient might have recovered without it, but it was probably of use in lessening the intracranial pressure, and in providing a certain amount of drainage for any infectious material. The case also illustrates the uncertainty of a diagnosis of sinus thrombosis, for all signs pointed towards it, yet it was not discoverable.

CASE 7—**Acute Suppurative Inflammation of the Outer and Middle Ears—Septico-Pyæmia—Recovery.**

D. P., twenty-two years old, admitted to hospital September 2, 1896, with a purulent discharge from the left ear of two weeks' duration. The drum-membrane was pale, thickened, and perforated, and hearing much diminished. No fever. September 5th, patient had pain in the left side of the head, the discharge increased, and the mastoid region became swollen. The walls of the external auditory meatus were much swollen.

September 11th, the **usual mastoid operation** was done, since all symptoms had increased. The mastoid cells were full of granulation tissue and some pus, and all such tissues and material were scraped away down to normal bone. The wound was treated by packing. The course was normal up to October 25th, by which time there was only a small fistula remaining, but on that date the patient began to have headache, dizziness, nausea, and some fever, and the discharge from the fistula became profuse. There was also pain and swelling in some of the large joints.

Another operation was done with the idea of exposing the sinus, and during its course the vessel was wounded, so that the operation had to be suspended. However, after a few days, with symptoms of chill, fever, and pain in the joints, all conditions began to improve, and in about six weeks the wound was entirely healed.

REMARKS: We may see from this case that the sinus may be opened under aseptic precautions without danger, but I do not agree with Leutert in saying that opening the

sinus is entirely harmless. The danger of forming an artificial thrombosis has been overestimated, for Eberth and Schimmelbusch have shown how difficult it is to produce a thrombus artificially, and when the attempt is made, the thrombus is small and limited to the site of the traumatism, and consists of a mass of blood-cells. A thrombus due to infection is another matter, and its formation requires a previous inflammation of the whole vessel-wall, by which the bacteria gain access to the interior of the vessel and exercise their influence upon the blood for a considerable period. A thrombus may also be formed from a slowing of the blood current, with some predisposing condition in the blood. We may be certain that an aseptic puncture or injury of the uninflamed sinus wall will not cause thrombosis, but if there is inflammation present, such a formation is certain to appear.

I can introduce at this point **two fatal cases of thrombotic pyæmia,** which I operated upon but did not treat afterwards.

CASE 8.—The first patient was a soldier, twenty-two years old, with a chronic suppurative otitis media, in the third week of which a typical pyæmic fever with chills developed. He was somnolent, had pain in the occipital region, his spleen was enlarged, and there was great prostration and some delirium. The conditions persisted for a week, and then I **operated** upon his mastoid, and found it full of pus and granulation tissue. The dura did not pulsate, and the sinus was slit open, and found to contain a yellowish-red thrombus, which, however, did not obstruct the whole lumen. The operation had no effect upon the course of the pyæmia already developed, and large abscesses formed in various parts of the body. The patient finally died from hemorrhage from a large vessel in the floor of a gluteal abscess cavity.

At the **autopsy,** the left lateral sinus was found completely obliterated by a dense, partially organized, reddish, shining thrombus. The rest of the body showed the ravages of the pyæmia.

CASE 9.—The other patient was also a soldier, aged twenty-three, with a chronic suppurative otitis media. I saw him first in the third week of the disease, and at the time he looked pyæmic.

Examination showed that he had all the signs of an intense pyæmic infection, and although the prospects were very bad, the operation of exposing the sinus was undertaken. The sinus was gray, covered with a layer of pus, and when opened was found filled with a friable, yellowish pus thrombus, which was removed with the spoon as far as the torcular one way, and the jugular vein the other. The treatment of the abscesses in other parts of the body was postponed. The patient died in three days. At the autopsy more thrombi were found in the sinus and in the jugular vein; there was pus in many joints and other evidences of general infection.

Both these cases are examples of pyæmia developing from sinus infection, and it seems as if the first one ought to have recovered if the infection had not already got into the joints, since the thrombus in the sinus was already partly organized, and thus prevented any further dissemination of infection. The fatal hemorrhage undoubtedly came from some large eroded vessel. When we compare such cases with cases without thrombus, no matter how apparently very bad, we are convinced that most of the former end fatally, while in the latter the chances of recovery are good. The supporters of the view that an otitic pyæmia can develop without the involvement of a sinus explain the occurrence by the direct transmission of the infectious germs through the vessel-walls. Many observers believe that cured cases of otitic pyæmia did not originate in sinus thrombosis, but such an origin without thrombosis is probably rare. *Those who believe in the occurrence of pyæmia without thrombosis base their views upon the following facts:*

1. Osteomyelitis in bones causes pyæmic infection by transmission of the germs through the minute veins, and there is no reason to suppose that the process, when it is in the mastoid, is any different. 2. When there is a thrombus in the sinus, the neighboring bone is usually healthy, a fact which shows that the thrombus is secondary. 3. In many such fatal cases of pyæmia no thrombus is found at autopsy. 4. Many cases of pyæmia have recovered after a simple chiselling of the mastoid or opening the sinus. Leutert, however, denies that there is an analogy between the mastoid and other bones.

It is not always possible to say, from a macroscopic examination, whether the bone is the seat of inflammation, since the redness disappears after death, but the microscope affords us some information upon this point.

Moreover, osteomyelitis does not always cause thrombosis in the neighboring section of sinus. The thrombus, when present, is almost always in the bulb of the jugular vein, and small fragments of a degenerated thrombus may very easily be overlooked.

My own experience causes me to make a distinction between pyæmia with and pyæmia without thrombus, but I do not deny that absence of a thrombus in the sinus necessarily means that there is not a thrombus somewhere else. From the therapeutic point of view the thrombus in the lateral sinus is the most important, since here it is commonest, and here it is accessible to surgical treatment. In my opinion, when puncture with the needle gives a negative result, there is no thrombus present, and that in the beginning stages of a septicæmia, or septico-pyæmia, there is no thrombus. The comparatively favorable course of the cases of pyæmia without thrombosis seems to depend upon the fact that when the bacteria and their toxic products enter the blood current in such cases, they are scattered very quickly through the circulation, and unless the quantity is overwhelming, the white cells and the serum have a chance to neutralize or destroy them ; if, however, there is a thrombus present, when the infectious elements enter the vein from the osteomyelitic bone, they find a favorable ground in which to grow, and also a slowed or stopped blood current which prevents the serum and leucocytes from acting to any extent. The pyæmic process is made still more active by the dissemination through the body of infectious emboli. Sometimes cases of pyæmia with thrombus are very mild at first, and the course is much like that of intermittent fever, and some cases of pyæmia without thrombus that give very severe symptoms at first. Sometimes the joint lesions occurring in the course of a septico-pyæmia such as we are describing will resemble very closely those of rheumatism.

I should like to introduce here the histories of three cases seen in the year 1895.

CASE 10.—**Fatal Acute Abscess in the Temporal-Sphenoidal Lobe.**

Patient had an acute otitis media which lasted three weeks, and did not suppurate. The patient was discharged with normal hearing. Two weeks later he died and the

Autopsy showed an unencapsulated abscess in the right temporal lobe as large as a hen's egg. There was a carious spot in the tegmen tympani 6 *mm* in diameter. The tympanic cavity and the mastoid showed no signs of disease.

CASE 11.—**Acute Otorrhœa, Pachymeningitis, Purulent and Superficial Softening of Cerebellum.**

Patient was brought to the hospital on account of severe dyspnœa and dysphagia, and an acute otitis media on both sides which had existed a week. In nine days all the symptoms had disappeared, and the patient felt well. On the tenth day he suddenly began to vomit, and soon became unconscious and died.

The **autopsy** showed a superficial softened area in the right lobe of the cerebellum, and a purulent inflammation of the dura covering it. There was pus in each tympanic cavity and some thickening and redness of the mucous membrane.

CASE 12.—**Acute Otorrhœa, Thrombosis of Lateral Sinus, Inflammation of Tentorium and Cerebellum.**

Patient admitted with an acute suppurative otitis media of one week's duration. There is occipital headache. Next day symptoms are better, and during the following four days the patient felt very well. On the fifth day the temperature rose above 40° C., and the pulse was 120. In a few hours a rapid pulmonary œdema developed, and the patient died in ten minutes.

Autopsy showed a suppurative inflammation of the surface of the cerebellum and of the tentorium, and a broken-down thrombus in the right lateral sinus. There was pus in the right tympanic cavity.

Remarks: Case 10 is remarkable in that there was a large otitic brain abscess, without any symptoms pointing towards it. The exact cause of the circumscribed carious area in the tegmen cannot be given. It is quite possible that the brain abscess had its beginning in a previous attack of otitis.

In Case 11 there was nothing to point towards any brain involvement. The sudden end might have been from a rupture of a brain abscess, but the autopsy did not reveal this. The dysphagia was probably caused by pressure in the region of the pons.

Case 12 was one of thrombotic pyæmia not diagnosticated during life. The ending of this case also resembled the symptoms of a ruptured brain abscess. It is remarkable in this case that the mind should have been clear until death. The localized inflammation in the dura is rare.

From my experience with the class of cases under discussion, I have come to the following conclusions:

1. There is much lacking in our knowledge of the complications which may arise in such cases.

2. Free opening of the abscess has a favorable influence upon the disease.

3. When there is otitic disease with constitutional symptoms, an operation upon the mastoid is indicated.

4. Opening the cranium is important, even if no inflammatory products are found, since pressure is thereby relieved.

5. If the probability of a thrombosis is present, a small aspirator must be introduced into the sinus so that we may decide if any more radical measures are necessary.

6. There is no danger of any further infection in puncturing the sinus under proper precautions.

7. Clinically, there are two forms of pyæmia, that with, and that without, thrombosis.

8. The thrombotic form of the disease is a sequel of the other form.

9. The thrombotic form almost always ends fatally, the non-thrombotic rarely so, with proper treatment.

10. It is often difficult to choose the best moment for operating, especially when the symptoms are severe. Severe symptoms usually mean immediate operation.

As an appendix to this paper I should like to describe

CASE 13.—**A Cerebral Abscess of Nasal Origin.**

The history of the case was, that the patient came to the hospital on account of headache and an intermitting fever. He was given quinine. After six days, he began to have sharp pain in

both ears. He soon felt better, and was well enough to talk and to smoke a cigarette. However, one evening he suddenly had violent headache, vomited once, lost consciousness, and in two hours was dead.

The **autopsy** showed the dura all over the anterior fossa much thickened, especially so over an area about 4 *cm* in diameter, and between it and the bone there was a layer of pus. In the right frontal lobe there was an abscess as large as a pigeon's egg, with its cavity almost empty. There was a small opening between the surface of the brain and the abscess, and the neighboring brain tissue was œdematous. Ears normal. Frontal and maxillary sinuses were filled with odorless pus. All the bones were normal, as were the teeth, and there was no discoverable connection between the cranial cavity and anything outside. The bacteria were streptococci and the diplococcus of Fränkel.

Remarks: The case has more anatomical than clinical interest. Just what symptoms the patient showed when he was admitted to the hospital are not certain, and headache and an intermittent temperature were the only things observed in the hospital. The autopsy, however, showed an inflammation in the nasal cavities, which had extended to the frontal sinuses, and had caused suppuration. The bursting of the abscess was of course the cause of the sudden death. The non-involvement of the bones is somewhat unusual. Such abscesses of nasal origin are exceedingly rare. The infection may be acute or chronic, and may be transmitted through a defect in the bone, natural or pathological, or through the ethmoidal veins. Frontal abscesses rarely cause localizing symptoms, and then only by transmitted pressure. The treatment of such cases is in an un satisfactory state.

ON CARTILAGINOUS INTERGLOBULAR CAVITIES IN THE CAPSULE OF THE HUMAN LABYRINTH.[1]

By Dr. PAUL MANASSE, Strassburg.

PRIVATDOCENT AND FIRST ASSISTANT OF THE UNIVERSITY EAR CLINIQUE.

Translation by Adolph O. Pfingst, M.D., Louisville, Ky.

(*With Plates I. and II. of Volume XXXI. of German Edition.*)

ON examining a pathological labyrinth I found in the cochlear capsule numerous peculiar, ramifying, large cavities, firmly imbedded in the bone, always in the vicinity of the cochlear turns, and filled throughout with hyaline cartilage. This led me to re-examine serial sections of two other labyrinths, and I found in them the same cartilaginous cavities.

In reviewing the literature I find occasional mention of such cavities, but no detailed account or description.

The technique followed in my research was as follows: The petrous bones were fixed in Mueller's fluid and subsequently in alcohol, decalcified in 5–10 per cent. sol. of nitric acid, hardened in 50–80 per cent. alcohol, with a small quantity of soda added to neutralize the acidity, dehydrated in absolute alcohol and imbedded in celloidin. The labyrinth was divided with a razor through its middle before imbedding it, so as to insure thorough impregnation of the tissue. Sections were stained in hematoxylin and hematoxylin and eosin. Twenty-four specimens from subjects of different ages, up to seventy-two years, were examined.

[1] From the Pathological Institute at Strassburg, Germany.

In every portion of the bony labyrinth—around the cochlea, vestibulum, and the semicircular canals—small, round, oval, and fusiform cavities were noticed. The more elongated ones often possessed lateral branches which communicated with similar spaces, forming apparently a complete circle. In some specimens the clefts were separated from one another, being surrounded by compact bone. The walls of these little cavities were of dense bone. Their interior was usually irregular, being studded with round, sharply defined elevations of bony tissue. Each elevation contained from one to three lacunæ with bone corpuscles. While the little osseous elevations varied considerably in size none were sufficiently large to obstruct the lumen of the cavity. The narrow spaces contained a homogeneous hyaline substance which readily took the hematoxylin stain. The larger ones, which were the most numerous, also contained a hyaline matrix, embracing a number of large, round, or oval encapsulated corpuscles—evidently cartilage cells. There were no blood-vessels within the cavities, but they were separated from the cartilage spaces by a ridge of bone of considerable thickness. I found, in other words, two systems of canals in the osseous labyrinth—(a) a system of blood-vessels, and (b), a system of cartilage-bearing spaces, each with a distinct bony wall. The chain of cartilage spaces was often broken, being replaced in parts by bone. A well-defined line of demarcation was visible between this compact bone and the osseous wall surrounding the blood-vessels. In the dense portions of bone triangular spaces similar to ordinary lacunæ were observed. These seemed to have been produced by a compression of the described spaces—whose osseous nodules could be outlined even in the compact bone. In other portions of the bone the change from a spongy to a more compact structure was more abrupt. The spherical bodies became more and more numerous and closely crowded, and the interspaces correspondingly smaller. The nodules finally coalesced to form dense bone in which cavities were only exceptionally found. The process, in brief, was an ossification of the cartilage within the anastomosing system of canals previously mentioned.

The relative position of the cavities to the spiral canal of the cochlea varies, some being parallel, others at right or oblique angles to it. Those situated at right angles sometimes perforated the bony wall and reached the periosteum of the spiral, where they spread out in a small circular zone. In such cases there seemed at times to be an entire absence of bone on that side of the canal, the hyaline cartilage apparently lying in contact with the periosteum.

Usually, however, a thin lamella of bone, marked on the side next to the cartilage by the same round elevations already mentioned, intervened.

To determine whether the cartilage contained in the ramifying canals was true cartilage, or cartilage in the state of ossification, the tissue had to be examined without decalcifying. To accomplish this, thin sections were sawed from the bone and fastened to a cover-glass by means of hot balsam. The tissue was then reduced by grinding it upon a fine stone. In these specimens, the tissue surrounding the cartilage cells, which in the decalcified specimens appeared homogeneous, was made up of large and small spherical bodies (Fig 3). Their formation was due to a deposit of granular lime salts.

In reviewing the scant literature on the subject under discussion, I found that Böttcher[1] speaks of calcified cartilage cells, observed by him in the petrous bones of full-grown cats and dogs. Politzer[2] found cartilage in the laminæ spiralis ossea. Gottstein[3] noticed similar tissue, undergoing ossification, in the cochlea of a child one year old. In a recent publication Habermann[4] described small macroscopic areas of cartilage in the bone below the ampulla of the posterior semicircular canal, containing large cartilage cells.

Cartilage spaces were discovered by Moos and Steinbrügge[5] in a carious specimen. The walls of the labyrinth were unusually transparent, and contained numerous normal

---

[1] *Verhandl. d. k. Leop. Carol. deutsch. Acad. d. Naturf.*, Bd. 35, 1873, S. 64.
[2] Lehrbuch. 1887, p. 457.
[3] *Archiv für Mikrosk. Anatomie*, viii., p. 148.
[4] *Archiv für Ohrenheilkunde*, Bd. 42. Heft 2.
[5] *Zeitschrift f. Ohrenheilkunde*, x., p. 94.

cartilage cells. These authors were inclined to look upon the condition, as a beginning of caries. In portions of the same specimen they found more compact bone structure, containing some ramifying passages, which were also thought to be the result of caries.

While this exhausts the literature on our subject proper, it might be of interest to note some of the changes which take place in the development of bone at other parts of the body. No mention has been made of the occurrence in fully developed bone, of cartilaginous cavities surrounded by spherical osseous walls. Gegenbauer[1] described such histological conditions, in the periosteal development of bone in the fœtus. The bone was composed of a multitude of closely crowded spherical bodies, with interspaces of various sizes. The tissue contained bone corpuscles. Gegenbauer called these osseous bodies *globuli*, and the spaces between them *interglobular cavities*.

The latter, he believed, formed a communicating system filled with a protoplasmic fluid. Identical conditions were found in the bone of young deer by Lieberkühn,[2] who considered the bony spheres as bundles of connective tissue invading the bone. Waldeyer[3] also attributed this formation to an ossification of invading connective tissue bundles. In a more recent publication, Gegenbauer[4] opposed the view of Lieberkühn and Waldeyer, claiming that the round bodies were distinct spheres. He had often seen them, most distinctly in the periosteal portion of a bone of an infant three months old. The cuts (Taf. iv., Fig. 13) accompanying his publication resemble so closely the conditions found by me in the labyrinth, that the terms globuli and interglobular cavities suggested by Gegenbauer, seem to express admirably the structural arrangement of the osseous labyrinth.

The conditions in Gegenbauer's case differed from mine, inasmuch as he found osteoblasts, where I found cartilage cells.

---

[1] *Zenaische Zeitschrift*, Bd. i., p. 353.
[2] *Arch. f. Anat. u. Physiologie*, 1864, p. 600.
[3] *Archiv f. Mikroscop. Anatomie*, Bd. i., p. 372, 1865.
[4] *Zenaische Zeitschrift*, Bd. i., p. 244, 1867.

A diversity of opinion seems to have existed among former authors as to the formation of the globuli ossei. Such bodies have been described by Brand and Reichert,[1] H. Mueller,[2] Kassowitz,[3] and Tschichtowitsch.[4] The description of Kassowitz and one of his illustrations (No. 17) correspond strikingly with what I found in the labyrinth. He, however, found cancellous bone where I found compact bone with blood-vessels. This difference is plausible when we consider that Kassowitz and others observed the interglobular cavities only in enchondral ossification while in the labyrinth they were present at all ages. It seems, therefore, that **the labyrinth capsule occupies a peculiar histogenetic position. Interglobular cavities occupied by cartilage are present until late in life while in other bony structures they are only met with in bones of the fœtus or very young children.**

The osseous globuli and their inter-spaces in the labyrinth evidently have some connection with the process of ossification, though the exact part which they play has not as yet been determined. In normal enchondral bone-development they are present at the stage in which the medullary cavities have made their way into the calcified cartilage and opened partially the cartilaginous cavities. Between the narrow cavities lined with osteoblasts and that portion of the cartilage into which the cavities have not penetrated, a thin lamella of bone, sending irregular projections into the cartilage, is found at this stage. At present the most generally accepted view is that advanced by H. Mueller and others, that in normal enchondral bone-formation the globuli ossei are formed by the extension of narrow cavities into the calcified cartilage, and that bone-formation takes place from the marrow. Some authors, among them Kassowitz and Tschichtowitsch, pretend on the other hand that the globuli originate in the cartilage into which no marrow cavities have entered.

While I have not made a study of the embryonal ossification of the human labyrinth, I believe that the globuli ossei

[1] Cited by H. MUELLER.
[2] *l. c.*
[3] *Die Normale Ossification, etc.* Part i., p. 177.
[4] *Virchow's Archiv*, Bd. 148, p. 140.

of the adult's labyrinth develop from cartilage cells and their surrounding matrix, and not, as in the usual process of ossification, from the marrow. The cartilage cells with their surrounding capsule are not always imbedded in a hyaline matrix, as in normal cartilage, but are surrounded by a narrow area of bone. From this ring of bone a narrow osseous strip extends to one of the osseous globuli lining the cartilage spaces. It seems that the cartilage cells are about to coalesce with the osseous lining of the cavity containing them. In fact some of the cartilage cells take on the characters of osseous globuli. Some of the globuli ossei also retain some of the characters of the cartilage cell. These facts justify the belief expressed above that the globuli ossei of the labyrinth and the bone corpuscles of the interglobular cavities are formed from the cartilage cells contained in the interglobular spaces.

Description of Illustrations.

FIG. 1.—From cochlea of man forty-seven years old. *J.* Interglobular cavities containing cartilage.

G. s., Ganglion spirale.

P. a. i., Porus acusticus internus. *S. w.*, Cochlear turn. Zeiss, A, A, Oc. 4.

FIG. 2.—From cochlea of an adult. Interglobular cavity, highly magnified. Zeiss, D, D, Oc. 4.

(*a*) Osseous pedicles.

(*b*) Cartilage cells with osseous surrounding.

FIG. 3.—Ground specimen (not decalcified). Zeiss, D,D, Oc. 4.

Kz. Cartilage cells.

K. k. Granules of lime salts in matrix.

THE AFFECTIONS OF THE EAR IN ACUTE AND CHRONIC BRIGHT'S DISEASE.

By Dr. J. Morf, Winterthur, Switzerland.

Abriged and Translated by Dr. Arnold H. Knapp, New York.

DIEULAFOY was the first to draw attention to the frequent combination of disturbance of hearing with chronic nephritis. He and his pupils were enabled to collect 35 cases of aural complications in 72 patients with acute and chronic Bright's. These cases however were not sufficiently examined as to the aural symptoms and an exact localization of the lesion is not possible. Hence the generally accepted belief that ear symptoms in chronic nephritis are the prodromata or symptoms of uremic poisoning.

I have collected 53 cases out of literature, which with my own 3 observations make 56 cases. In all of these there can be no doubt of the connection between the aural disturbance and the nephritis.

The aural changes due to nephritis may be divided in two groups. The first group contains those disturbances due to pathological processes in the ear, macroscopic, microscopic, or revealed by the functional examinations; in the second group belong the cases where no tissue changes can be found to account for the functional disturbance.

The first group includes only affections of the middle and the inner ear. The middle-ear diseases are present in three forms: inflammatory, inflammatory-hemorrhagic, and hemorrhagic. It is difficult to estimate the labyrinthine affections as there are no autopsies on record.

The pathological changes in the temporal bones of neph-

ritic middle-ear disease differ but little from the changes found in other middle-ear affections. In the purulent forms there is an unusual tendency to necrosis and caries of the surrounding bony walls.

Inflammatory changes in the Eustachian tube and the naso-pharynx are often present at the beginning of the otitis, but they are sometimes absent.

Hemorrhages are usually very abundant, and occur in the middle-ear spaces. No hemorrhage into the labyrinth has thus far been proven at autopsy.

In the cases of the second group we have neither an otoscopic nor a functional examination to guide us in localizing the lesion. Various theories have been suggested to explain these cases. Field suggested that the increased arterial pressure causing distension of the labyrinthine vessels, with increased pressure within the labyrinth, excites or paralyzes the sound-perceiving elements in the cochlea; the intermittence of the sound disturbance being due to the varying pressure. This theory, however, cannot explain those cases where there is no hypertrophy of the left ventricle or where the heart activity is weakened. Opinions differ at present as to the effect of increased pressure within the labyrinth.

Rosenstein was the first, as far as I know, to consider the possibility of an œdema of the auditory tracts causing disturbance of hearing in nephritic patients. He cites the case of a woman, twenty-nine years old, suffering from intermittent fever with irregular febrile attacks. The attacks were accompanied with general dropsies, which disappeared. The hearing gradually failed. The urine was scanty, contained albumen and casts. The hearing was restored on the diminution of the dropsy, to fail again when the general œdema increased. The patient died with symptoms of œdema of the lungs. At the autopsy nothing could be found to account for the loss of hearing. The difficulty of recognizing, macroscopically, œdema of the brain is well known. Other authors favor the assumption of a transitory œdema as causing transitory functional disturbance in parts of the brain. The following observation of mine has bearing on this point. It was a case of bilateral nervous deafness whose cause was

hydrocephalus or convulsive seizures in early youth. The sudden increase of the deafness and the constant, intense headache at one stage seemed to be dependent on the nephritis and the œdema, as treatment of the latter brought back the hearing to its former degree and caused the disappearance of the tinnitus.

It is well known that nervous symptoms are prominent in uremia, and various cases have been published showing that the auditory nerve and its central tracts may be involved. The following case may also be taken as proof for this statement. The case was one of bilateral nerve-deafness following the use of quinine for malaria. At the onset of uremic symptoms caused by the chronic interstitial nephritis the loss of hearing became suddenly almost complete, with nearly constant tinnitus. In this case the œdema was very slight, in distinction to the preceding case. On suitable treatment directed against the kidney lesion the hearing returned to its former state. Notwithstanding hypertrophy of the left ventricle the arterial pressure was not raised, and it can hardly be assumed that unusual distension of the labyrinthine vessels could have caused the aural symptoms.

There are cases where the loss of hearing with the changed condition of the urine are the only signs of an existing nephritis. It is probable that it is then a symptom of chronic uremia. This is illustrated by a case where the result of treatment again showed the relation between the aural lesion and the nephritis. Besides slight visual disturbance, the loss of hearing was the only symptom which led me to examine the urine and discover the kidney disease. I am inclined to regard the anæsthesia of the auditory nerve and the tinnitus as symptoms of chronic uremia, confirmed by the slight diminution of vision, without ocular changes, which could be regarded as a uremic amblyopia.

In regard to the frequency of ear disease in nephritis, we have only the statistics of Dieulafoy. He found disturbance in the ear in 50 per cent. of nephritic cases, and slightly less frequent than the eye symptoms. The forms of the nephritis in which the aural complications occur are, according to Dieulafoy, in 16 cases:

Chr. parenchymat. nephritis.....	4 cases.
Chr. interstitial nephritis.....	4 "
Nephrite mixte[1].....	7 "
Ac. nephritis.....	1 case
	16 cases.

In 24 of the 56 cases collected by me, the special form of nephritis was mentioned as follows:

Ac. nephritis.....	4 cases.
Chr. parenchymat. nephritis.....	9 "
Chr. interstitial nephritis.....	11 "
	24 cases.

In the other cases, the term chronic nephritis was used.

In enumerating the symptoms we must distinguish between those symptoms due to previously existing pathological changes and the true nephritic symptoms which are joined to or modify the former.

The usual auditory symptoms are, subjective noises and a loss of hearing. Auditory hyperæsthesia was observed in one case. The subjective noises are of all kinds, duration, and intensity; though in general they seem to be worse at night. The deafness may vary in degree and duration.

The ear may become affected in any stage of the nephritis, though usually it follows an exacerbation of the kidney trouble in the form of diminished secretion of urine, increase of albumen, the appearance of œdema, or uremic attacks. The subsequent course of the aural lesion is directly influenced by the course of the nephritis. In 15 cases of nephritis, Pissot saw the ear become affected 11 times on the aggravation of the kidney lesion. According to the French writers, the ear became affected which was on the side where the facial œdema was most marked. The quantity and quality of the discharge in chronic purulent otitis are influenced by the œdema.

Voss remarks that in the late forms of scarlet-fever otitis there is one variety which is much more dependent on the nephritis than on the scarlet fever itself. The connection

[1] Transitional group from the parenchymatous to the interstitial varieties.

indeed is so intimate that the progress of the nephritis may be followed by the course of the otitis. Deafness and pain in one or both ears may follow, or even precede, a diminution of urine and the accompanying fever. There may be signs of a subacute otitis, which disappear again, or there may be an exudative otitis, and later otorrhœa. The discharge varies directly with the intensity of the albuminuria.

We have seen that the ear symptoms may be the only signs of a nephritis beyond the changes in the urine. In a short time, however, other symptoms, like œdema, uremia, visual disturbances, etc., make their appearance. Visual disturbances are often associated with the ear symptoms.

The diagnosis of a nephritic affection of the ear is confirmed when in addition to the nephritis a direct connection of the latter with the aural disturbance is ascertained. The diagnosis is easy when, with alarming symptoms of nephritis, one or both ears become acutely affected without any other known cause, or when variations in the course of the nephritis are associated with changes in the aural affections. The cases where the changes in the ear are the only symptoms are the most difficult to diagnosticate. Usually one is aided by the appearance of other symptoms. At any rate, in disturbances of the auditory organ without known cause, it is well to examine the urine.

As regards the second group of cases, an exact localization of the lesion is not possible. Nevertheless, there are a number of facts which indicate that we have to deal with the auditory nerve and its peripheral and central distribution. My three observations seem to me to permit only this explanation.

According to Gradenigo, affections of the auditory trunk are characterized by diminished, or lack of, perception for the middle tones, while in labyrinth affections the perception of the high tones is interfered with, and the middle and the low tones are well heard.

In those cases where hearing is diminished, but the functional examination proves negative, he believes our examination methods are at fault owing to insufficient delicacy, and advises examination with the galvanic current. In

affections of the auditory trunk, the nerve is said to have increased electrical irritability. As cerebral apoplexies are not rare in chronic nephritis, especially of the interstitial variety, it is possible for the auditory tracts to become interrupted by hemorrhage.

The prognosis, of course, depends on the nephritis, and, especially in the cases of the second group, it is not bad if the patient does not succumb to the kidney trouble or to some intercurrent disease before the ear trouble is healed. The ear trouble, nevertheless, is to be regarded as a complication which can be of grave import, especially in the purulent affections of the middle ear. The hemorrhages are always ominous, as they are usually soon followed by death. It is difficult to say what influence a nephritis may have on a previous ear trouble. I think on the whole that the influence can be said to be unfavorable.

The affections of the second group usually recover, while those of the first of course leave sequelæ.

The therapeusis consists of combined treatment of the kidney and ear trouble. The cases of the second group get better of themselves when the nephritis improves, while those of the first group require treatment just as the usual ear troubles do.

The complete literary references on the subject can be found in the *Zeitschrift f. Ohrenheilk.*, vol. xxx., pp. 342, 343.

CHLOROMA IN THE TEMPORAL REGION.

By Prof. O. LUBARSCH, Rostock, Germany.

Translated by Adolph O. Pfingst, M.D., Louisville, Ky.

THE infrequency of the occurrence of chloroma and its constant association with derangement of the hearing prompts me to report a case in which I recently made the post-mortem examination.

The condition was found in a boy six years old, in whom death took place about three months after the beginning of the trouble. A clinical account of the case has previously been published by Professor Koerner.[1]

Autopsy.—Near the middle of the vertex of the skull a nodule as large as a pea was found, lying partially in a corresponding depression in the bone. A portion of the node was discolored—yellowish green. The internal surface of the skull, after removal of the dura, presented a depression of the inner table at a point corresponding to the external depression. The dura was anæmic, and, parallel with the longitudinal sinus, there were a number of injected blood-vessels, between which some irregular red streaks were present. Numerous yellowish and grayish-red, button-like masses were also scattered along the longitudinal sinus. Near the apex of the frontal lobe a larger mass, about the size of a pigeon's egg, was found beneath the dura.

The pia mater, the brain substance, and the ventricles showed no abnormities. Upon removing the brain the transverse sinus on each side was seen bulging into the cranial cavity. The sigmoid sinus contained but a scant

[1] *Zeitschrift f. Ohrenheilk.*, Bd. 29; these Archives, xxvi., No. 3.

amount of fluid blood, a portion of it being replaced by long cords of greenish material, tightly adherent to the sinus wall. Upon removing the dura the same kind of material was found adhering to the external surface of the sinus. At points it perforated and entered the wall. The material varied in color from a light, yellowish green to a dark grass-green.

The tegmen tympani of the temporal bone was very thin. The internal auditory canal contained yellowish-green nodes, similar to those previously described, enclosing the facial and auditory nerves. Similar tissue was also present in the pterygoid processes of the sphenoidal bone.

Externally, in the region of the mastoid, an artificial opening (mastoid operation) led into the healthy-looking antrum.

A number of growths of the character of those previously described, and ranging in size from that of a pea to a cherry, were also found in the orbital cavity, especially in the fat surrounding the optic nerve, pushing the eyeball forward. Both temporal muscles were invaded by the same tissue, transverse section of the muscles showing well-defined, green areas intermingled with muscular tissue. All of the tumors had a firm consistence, and, upon section, a homogeneous appearance. They were not very vascular.

The rest of the body showed but unimportant abnormities. On the inner surface of the pleura grayish-pink and dark red hemorrhagic areas were visible. The lungs, upon section, presented areas differently colored from gray to dark red between normal lung substance. The darker areas contained little air; the others were well inflated. The bronchial glands were enlarged. The pericardium contained bloody masses similar to the pleura. Both ventricles of the heart were dilated and filled with light-colored liquid blood. Other organs were markedly anæmic, otherwise normal. Lymphatic glands, especially of the neck, were considerably enlarged.

Microscopically the peculiar new formation corresponded to the class of tumors described in publications of other authors as *chloroma*. The mass of the tissue was made up

of small round cells, with large nuclei and scant protoplasm —lymphocytes. Between the cells a delicate reticulum could be demonstrated (Biondi's method). In the dura the cells were frequently arranged in layers. But few cells with lobulated nuclei, as O. Schmidt described them, were found. Granule-cells with affinity for acid stains (eosin), as they have been observed in similar tumors, were present in but small numbers. They were most abundant in the cavities of the mastoid, and the marrow of the bones. Spindle-shaped cells, and large connective-tissue granule-cells (mast-cells), as Doch described them, were not found at all. On the other hand, some peculiar cells were found in the masses of tissue in the transverse sinus, the dura, and the ear. They contained, (*a*) large round cells with two cystoid nuclei, and (*b*) cells containing 4 to 5 nuclei.

The tumors were all poorly supplied with blood, though the blood-vessels were unaltered. The growths in the dura and the sinuses were pretty sharply defined, while those in the bone, the orbit, and the muscles infiltrated the surrounding tissue. This was especially the case in the muscles, where groups of cells were found lying between the primitive muscular fibres. The fibres of the muscular tissue were unaltered.

Especial attention was given in the examination to the organ of hearing, as the literature on chloroma enters but little into this field, notwithstanding the frequency with which the hearing is deranged in this affection. While the internal auditory canal contained a quantity of tumor substance, none had penetrated the internal ear proper. A number of the mastoid cells had been invaded, but not a trace of the pathological structure could be found in the tympanum. In regard to the cavities in the mastoid filled with chloromatous tissue, some doubt may be entertained as to whether they were really the mastoid cells. In the larger ones, where portions of the epithelial lining remained, it was evident that the growth had entered mastoid cells. In the smaller cavities, however, most of which were completely filled with chloromatous tissue, it was difficult to identify them as mastoid cells for want of normal structures. We could with

a reasonable certainty consider those which, beside tumor mass, contained a finely granular material, as mastoid cells, the granular matter resulting from an alteration in the normal cell contents due to the preparation of the specimen.

The condition of the bone around the infiltrated cavities differed somewhat in parts. Here and there normal osteoblasts were present, while in some portions numerous Howship's lacunæ containing osteoblasts were found. Outside of the changes mentioned the marrow of the mastoid and petrous bones, as well as that of the rest of the skull and also of the ribs, had undergone pathological changes which could be attributed to the chloromatous process. Instead of finding normal tissue in the marrow-spaces, they were filled with cells identical with those described in the chloroma of the dura. In parts they were larger and contained more of the acidophile granules. Layers of osteoblasts were also seen arranged over the bony trabeculæ.

In considering the cause of the defect in the hearing noted during life, the change on the interior of the bone could hardly be taken into account. On the other hand, the tumors in the internal meatus enclosing the auditory nerve undoubtedly played an important part in the disturbance of function.

The microscope showed that while the diseased tissue had not penetrated the nerve fibres proper, these had undergone marked degeneration (Weigert's stain).

As but a few cases similar to the one cited have found their way into literature, a *brief discussion of the pathology of these tumors* may be of interest. Considering the origin of the green pigment which characterizes the growths, K. Huber (1) and Chiari (2) classify it with the pigments of fatty tissue, and claim to have found it in the form of minute molecules in and between tissue cells. Von Recklinghausen (3) holds that a parenchymatous pigment, similar to the one present in old green pus, is the cause of the discoloration, as no pigment granules were observed by him. In the opinion of Waldstein (4) the pigment is a derivative of blood pigment. My experience would contradict the view of Huber and Chiari, as I was at no time able to find pigment granules.

Several of the cells were observed to contain small, fat globules, but they were found just as frequently in non-pigmented tumors, while in some of the highly pigmented nodes they were absent. The possibility of a fatty pigment can be excluded in our case. In the cases of Huber and Chiari, the oil globules which they observed had probably nothing to do with the pigmentation of the tumors. Another factor that would contradict their theory is that during the preparation of the tissue the hardening solution (formol) removed the fat from the tissue and left the pigment intact. Dock was able to demonstrate the presence of green pigment in tissue that had been preserved in absolute alcohol for a year. Waldstein's idea of the origin of the pigment in the blood was based upon the observation that pigmentation was always most marked where other evidences of hemorrhage were present. In my case I found the most pigmented masses along the sinuses; in fact, a diffuse green coloration of the sinus walls was observed in the vicinity of the chloromatous tissue.

While this in a measure would support Waldstein's view, it cannot be looked upon as proof positive. As to v. Recklinghausen's suggestion of an identity of this with the parenchymatous pigmentation, he himself has shown and emphasized the frequent occurrence of green pus without the presence of chromogenetic species of bacteria. A circumstance that could be mentioned in support of v. Recklinghausen's theory is the one alluded to by Dock (5), that in cases of marked leucæmia the leucæmic tumors have been observed to have a decided green color. In several cases of lymphatic leucæmia which I have seen a marked green discoloration of the enlarged glands was noted. In one case, a woman, fifty-five years old, several of the glands of the neck which were enlarged had a yellow interior and well-defined wedge-shaped and crescentic areas of green in the periphery. In the other case, a woman, seventy-one years old, the same condition existed in the abdominal lymphatic glands. The discoloration could not easily be mistaken for post-mortem changes, as the absence of all other signs of decomposition and the decided difference between the grass green of chlo-

roma and the dirty green of decomposition would exclude such a possibility. The appearance of pigmented areas in leucæmia, pseudo-leucæmia, and chloroma, as well as other features which they have in common, leaves little doubt that the three conditions are closely allied to one another. If we should accept the theory of v. Recklinghausen of a parenchymatous pigmentation it would be based merely on assumption, for the character and origin of parenchymatous pigmentation have never been satisfactorily explained. O. Schmidt (6) suggests the possibility of a change in form of the leucocytes which make up the lymphoma being accountable for the pigmentation, and claims to have seen a marked variation in their size and shape in the pigmented tumors. This view, while it appears plausible, does not agree with my own observations. I could find no variation in size or shape in the cells of the pigmented and non-pigmented areas. It was impossible to recognize with the microscope the areas in leucæmia which to the naked eye had a decidedly green cast. From a bacteriological standpoint my researches all gave negative results, though I made extended and careful experiments, including methods for anaërobic culture.

Authorities do not agree as to what class of tumors chloroma belongs. Huber looks upon it as periosteal sarcoma, while v. Recklinghausen places it in the same category with leucæmic and pseudo-leucæmic lymphomas. Huber's theory can hardly be accepted from the simple fact that sarcoma is by far the most frequent form of tumor originating in the bones and their membranes. Not only do many other varieties of tumor develop in bone, but, as we know, nearly every inflammatory process of the bone is accompanied by hyperplasia of the periosteum. While in our case the layers of osteoblasts in the mastoid and petrous bone could be used as an argument in favor of Huber's theory, this was the only feature that would lead to a diagnosis of sarcoma. There was not a gradual change in the shape of the cell from the spindle-shaped connective-tissue cell to the small round cell of chloroma to indicate that the dura was the base of origin of the neoplasm. There was, on the contrary, a sharp line of demarkation between the normal and pathological tissues.

The tumors were so much like lymphomas and lymphosarcomas in their histological make-up that but for their green color (macroscopic) the possibility of any condition but lymphoma would never have been entertained. Dock has shown that leucæmic blood can exist along with chloroma. Whether or not in our case the blood was leucæmic could not be determined, as it had not been examined during life. After death the blood showed a considerable increase in white corpuscles over normal, which, however, could have been a transitory increase—leucocytosis. O. Schmidt reported a case of chloroma and lymphoma occurring in an individual in which there was no leucæmia. In his case as in ours green masses were found side by side with non-pigmented enlarged lymphatic glands.

Chloroma, lymphosarcoma, and tumors of this kind which seem to have a toxic or infectious origin should hardly be placed in the same category with sarcomas and other autogenous tumors. The former are merely a manifestation of a general diseased condition of the organism. Though they may develop in large numbers in the body, each tumor must be looked upon as a primary condition and not as a metastatic formation depending on the dissemination of some primary autogenous growth. While they usually have a predilection for lymphoid tissue, they have been found in other parts of the body. Their predilection for lymphoid tissue, however, accounts for the development of chloroma in the cancellous tissue of the mastoid whose mucous membrane is characterized by its follicular structure.

As I have placed lymphosarcoma and chloroma in the same class of tumors, it would be of interest in considering the etiology of chloroma to mention the view recently advanced by Cordua, Ricker, and others of the close relation existing between lymphosarcoma and tuberculosis. Paltauf opposes this view, and is inclined to look upon the cases of Cordua (7), Ricker (8), and others, which had the clinical and anatomical characteristics of pseudo-leucæmia, as tuberculosis of lymphatic tissue running an atypical course. Weisshaupt (9) is also of the opinion that tuberculosis and pseudo-leucæmia are, from an etiological standpoint, inde-

pendent of each other, though he admits that some cases of tuberculosis of the lymphatic tissue resemble pseudo-leucæmia very much in their clinical course and in the pathological changes. It would be difficult indeed to decide positively in favor of one or the other of these theories. If in cases of pseudo-leucæmia the post-mortem examination reveals distinct evidences of tuberculosis of the lymphatic gland, the diagnosis of tuberculosis is certain. Not so, however, in the cases of Ricker and Paltauf, where the histological changes in no way resembled those of tuberculous glands, and where but isolated tubercle bacilli could be found. Paltauf and Ricker speak of cases of lymphatic enlargement in which the microscopical changes are characteristic of lymphosarcoma, yet isolated tubercle bacilli could be demonstrated in the tissue. They consider them as an atypical form of tubercular glands. While this view would appear plausible, a case which came under my observation, where the same pathological changes had taken place, however, without the presence of tubercle bacilli, leaves some doubt in my mind whether the diagnosis of tuberculosis was justifiable. Not only were the lymphatic glands enlarged at various parts of the body, but tumors were present in the lungs, liver, and spleen, a number of which had undergone cheesy and calcareous degeneration. Large sarcoma cells, similar to those described by Paltauf and Ricker, were easily recognizable. Giant-cells were not found. Some parts of the tissue were typical of simple lymphoma. In the search for the bacillus of tuberculosis, I examined pieces of every diseased portion of tissue carefully, the research extending over the course of a year. Results were all negative. This case could not possibly be considered as an atypical form of tuberculosis. It could perhaps be an intermediary condition between those atypical cases of tuberculosis which run a course similar to lymphosarcoma or pseudo-leucæmia, and some forms of lymphosarcoma. At any rate, a close etiological relation between them is probable. The generally accepted belief that hyperplastic lymphatic structure is brought about by bacterial or other poisons would be confirmative of the existence of a close etiological

relation. We know now that hyperplastic tonsils are often due to tubercular infection. I was myself able to find them quite frequently in enlarged tonsils. The poisons of many other species of bacteria have a similar effect upon lymphatic tissue, though the tubercle bacillus has most readily been demonstrated in this connection, and I therefore venture the opinion that the tubercle bacillus and its products are important etiological factors in lymphosarcoma and allied processes. This was impressed upon me in the case of chloroma, subject of my report, in which the microscope revealed the presence of tubercle bacilli in the faucial tonsils and several enlarged lymphatic glands of the neck, but at no other parts of the body. A number of more remote glands were enlarged, but contained no bacilli. One of them contained a miliary tubercular node without bacilli. O. Schmidt found in his case a number of such nodes in the chloromatous tissue of a rib, but attached no importance to it at the time. While we may not be ready to accept at once the suggestion of an identity between the etiological elements of tuberculosis and lymphosarcoma, the fact remains that a close relation exists between the two, which should lead to further research in this direction. In cases of chloroma a thorough search should be made for the bacillus of tuberculosis, with especial attention to the faucial tonsils, which furnish the avenue of entrance to the tubercle bacillus more frequently perhaps than is suspected.

1. K. Huber. *Arch. d. Heilkunde*, Bd. 9.
2. *Zeitschrift f. Heilkunde*, Bd. 4.
3. v. Recklinghausen. *Tagebl. d. Versamml. d. Naturf.*, 1885.
4. Waldstein. *Virchow's Archiv*, Bd. 91.
5. Dock. *Amer. Jour. of Med. Sciences*, Aug., 1893.
6. O. Schmidt. *Dissert.* Göttingen, 1895.
7. Cordua. *Arbeiten a. d. patholog. Instit. z. Gœttingen*, 1893.
8. Ricker. *Arch. f. klin. Chirurgie*, Bd. 50.
9. Weisshaupt. *Arbeiten a. d. patholog. Instit. z. Tübingen*, vol. i., 1891.

REPORT OF THE SEVENTH MEETING OF THE GERMAN OTOLOGICAL SOCIETY AT WÜRZBURG, MAY, 1898.

By Dr. SELIGMANN, of Frankfort-on-the-Main.

Translated by Dr. Jas. A. Spalding, Portland, Me.

Bezold opened the meeting Friday, May 27th, in place of the President, Siebenmann, who was unable to attend owing to illness. Bezold remarked that whilst our knowledge of the normal anatomy of the ear has attained a high degree of development, the surgery and the pathological anatomy of the ear are still advancing towards new triumphs. Great honor is due in the latter respect to v. Troeltsch, in whose actual workshop we are this day assembled. It was a good omen that the Society was meeting in the pathological laboratory at Würzburg, and in the name of the Society we will place to-day a laurel wreath on the grave of that great aurist, v. Troeltsch.

BUSINESS MEETING.

The Society now numbers 173 members; during the year one has died (Moldenhauer, of Leipzig), and 31 new members have been admitted.

Hartmann gave a brief account of the meeting at Moscow, at which he regretted to find but a handful of members of the Otological Society. He hoped that the International Otological Congress, to take place in London in 1899, would be better patronized by German aurists, and especially that the Society would participate in the exhibit to occur in connection with the Congress.

SCIENTIFIC SESSION.

Barth, Leipzig: **Scheme for Uniformity in Testing the Hearing of the Diseased Ear.**

Various conferences have shown to the satisfaction of the committee that nothing can be accomplished without further discussion by word of mouth and by letter amongst a much larger number of practical otologists than has hitherto been available.

It was voted to print the results of the conferences and forward them to the members for further discussion at the next yearly meeting.

BLOCH, Freiburg: **On a Uniform Nomenclature for the Results Obtained by Testing the Functions of the Ear.**

The author proposed to follow Prout and Knapp's suggestion of using h (Horologium) for the watch, and V (Vox) for voice; to place the result for the right ear above a horizontal line, and for the left ear beneath the line; and additionally to test separately for a high, and a low, whispered voice. Rinne's, Weber's, and Schwabach's tests were to be noted by placing in front of the horizontal stroke the fork employed, above it the result of Rinne on the right ear, and beneath it that on the left ear, behind the stroke the result of Weber's test, and next to it Schwabach's, the latter for one fork with the number of seconds by which the tone is heard longer or shorter than normal.

(A detailed report of this scheme will appear in a later number of these ARCHIVES.)

BEZOLD: **Determination of the Hearing in Correct Proportions.**

BEZOLD succeeded in determining by an apparatus constructed by Edelmann that the dying away of all forks takes place in one and the same manner. If we assume normal hearing as 1, and total deafness as 0, we have only to divide the elongation by the amplitude; the inverted result shows the hearing for the fork in question. The only necessity for making this test precise is that the sound from the fork shall die away very slowly.

DENNERT: **Acoustic Communications for Solving Physiological and Practical Questions in Otology; Demonstration of Apparatus and Methods.**

Experiments with harmonics deserve to be carried out constantly, because of value in both the above points of view. The author muffled resounding tuning-forks until only the noise of a blow upon them was audible. With this noise alone he could cause other forks of the same pitch to vibrate. This proves the identity of noise and tone. Further experiments on co-vibration with forks in various media revealed fixed adequate relations.

But the muscles of the ear, being organs of unstable equilibrium, must possess some accommodative power. The degree of muffling in fluids depends on the pitch of the tone, the pressure to which the liquid is subjected, and to its adhesion. These facts ought to be useful in judging such symptoms as diplacusis, and in deciding on the treatment.

BECKMANN : **On the Theory of Hearing.**

Waves of sound more probably enter the labyrinth through the round than the oval window. The writer cannot agree with the selective action on waves of sound ascribed by Bezold to the structures of the tympanum. The purpose of these is double, depending on whether the parts are at rest or in vibration. In the former case they protect the labyrinth. The vibrations after attaining the labyrinthine fluid facilitate the reception of sound. At the same time the tympanic apparatus serves as a damper. With lifted damper the patient can no longer isolate echoing or mingled tones. Some of the lower noises in the ear may depend on loss of damping,

PASSOW : **Otology and Deaf-Mutism.**

The exaggerative employment of speaking exercises in deaf-mutes, without choice of material, has led to many errors, and to a prejudice on the part of the teachers against the method. Only children with a remnant of hearing should be exercised in this manner. At the same time local treatment of the ear should be instituted. Passow succeeded in obtaining governmental inspection by skilled aurists, in all these institutions. He found at his first visit many idiots in the schools, and numerous cases of deafness due to ceruminous plugs, enlarged tonsils, and suppuration. The author was of the opinion that aurists and teachers in deaf-mute institutions ought to meet together to discuss the differences of opinion in regard to the best methods of teaching.

In the discussion, BEZOLD remarked that in one institute of 80 children, 27 were enabled by instruction to enter ordinary day schools and to study with the other pupils. He thought that the aurist should make the diagnosis and leave the question of proper instruction to the teachers.

MANN thought that children somewhat deaf were often incorrectly sent to deaf-mute institutes.

BARTH wished the topic set aside for special discussion at the next meeting, and SCHMIDT suggested publication of the topic in journals devoted to school hygiene.

HELLMANN: **The Development of the Labyrinth in the Torpedo Ocellata.**

We are first struck with the disproportionate thickness of the semicircular canals and the ductus endolymphaticus in comparison with the cochlear portion of the labyrinth. Moreover, the outer semicircular canal opens into the anterior, and thus communicates with the vertical.

The development begins with the formation of an ear furrow from the ectoderm in the form of invagination of the epithelium. Folding of the middle edge over the furrow produces an ear sac, the opening closes, and we have an aural vesicle with a minute orifice outward. The outer wall of the vesicle reveals a shallow furrow, above which originates the posterior semicircular canal, beneath, the outer canal. The anterior canal originates from a pocket in front. At the inner end of the vesicle arises the recessus labyrinthi, at the posterior end the long ductus endolymphaticus. The development as a whole resembles that in higher animals.

OSTMANN: **On the Reflex Excitability of the Tensor Tympani by Waves of Sound.**

The physiological significance of the intrinsic muscles of the ear has not yet been accurately determined. Previous experiments tend to show that the tensor is a protective apparatus against too powerful waves of sound. This idea is contra-indicated by the experiments of Hensen and others. Ostmann has proved that the reflex contractions of the tensor observed by Hensen in curarized animals lie in the same category with Bernard's experiments on frogs, and are consequently not reflex convulsions produced by waves of sound. Ostmann has lately studied in animals the action of the tensor on the *Mt*, and discovered in dogs poisoned with strychnia reflex contractions to waves of sound. A long series of experiments proved that the tensor, by virtue of its natural tonic tension, as well as when in a condition of contraction, is a protective apparatus against too powerful vibrations of sound.

STRAUSS: **Tuberculous Tumor of the Auricle.**

The patient, a woman of twenty-five years, had exhibited the tumor for twenty years. From red moistened patches developed nodules which gradually became confluent. The tumor grew to be 8 *cm* long and 17 *cm* in circumference. The microscopic preparations confirmed the diagnosis by abundant giant cells in a granulation tissue.

SATURDAY MORNING, MAY 28TH.

HARTMANN: **Otitis Media in Infants.**

This was a continuation of Hartmann's efforts to show that otitis media in infants is largely dependent on their nutritive condition. The difficulties of determining whether a disturbance of nutrition is due to the otitis, or to a primary affection of the digestive canal were discussed, and a large number of temperature- and weight-charts exhibited, with the aim of showing the influence of the otitis on the nutrition. With the appearance of the otitis the defecations changed for the worse, and the weight decreased. A causal connection seems assured in cases in which repeated exacerbations of the otitis ensued with disturbances of nutrition, the latter disappearing after paracentesis.

Conclusions.—It would seem as if otitis media of infants were connected with disturbances of nutrition, expressing themselves in altered digestion and decrease in weight; that with evacuation of the secretion by paracentesis digestion may become normal, followed by an increase in weight; increase in temperature occurring in the course of an intestinal disease in infants may be due to otitis media; finally, in all cases of increased temperature and decreased weight with intestinal affection in infants, the ears should be subjected to a careful examination.

HARTMANN exhibited a nasal forceps which differs from those of Grünwald in that one blade is perforated. By this device the portions seized are divided more accurately and more smoothly.

HABERMANN: **I. Apparent Embolic Affection of the Ear.**

A man of fifty-three suffered one night from an attack of hemiplegia, which in a few weeks disappeared, with exception of a slight weakness. Four years later a relapse, with frequent attacks of tinnitus, vomiting, and deafness. Whisper not heard on the side affected. The field of hearing embraced forks from c^1 to c^7. The affection is probably of embolic nature, possibly in the brain along the course of the auditory nerve.

II. Ocular Paralyses and Middle-Ear Suppuration.

Acute middle-ear suppuration, ceasing in ten days, but relapsing in three weeks with persistent headache. Mastoid fistula many years before. Sudden paralysis of the abducens. The dura was exposed, found to be hyperæmic, but was not opened. Habermann was of the opinion that the abducens had been reached by extension of the inflammation into the petrous and sphenoid

bones. The paralysis became permanent, but the other symptoms disappeared.

The discussion brought out various instances of similar paralysis; KATZ observing it in a meningitis due to extension of the suppuration through the internal ear.

JANSEN thought that the paralysis was due to a serous meningitis, which might be cured by puncture. The serous meningitis might be dependent on sinus thrombosis or epidural abscess.

MANN had observed this paralysis in a perisinuous abscess. Pressure alone can also excite paralysis, and this can occur in the simplest manner in case of the abducens.

BRIEGER had seen a latent meningitis, the only symptom being the abducens paralysis, and KILIAN the same symptoms follow suppuration of the nasal accessory cavities accompanied with orbital cellulitis.

JANSEN thought that the disease could more probably be referred to the pia mater.

HABERMANN ended the discussion by saying that suppuration of the accessory cavities could be excluded, and that he had forgotten to mention that he had seen abducens paralysis on the side opposite the ear affected.

III. Anchylosis of the Stapes, with Exhibition of a Specimen.

The case was due to suppurative rhinitis, with excessive thickening of the tympanic structures, exostoses on the stapes, and osteophytes on the promontory, together with high position of the internal jugular extending to the lower semicircular canal.

MANASSE: **Secondary Labyrinthine Alterations in Primary Epithelial Carcinoma of the Middle Ear.**

Two cases of carcinoma of the ear preceded by suppuration and terminating in carcinoma. In addition to carcinomatous masses (horny carcinoma) and formation of cicatricial tissue, there were discovered hyaline degeneration in the cochlea and canals, partly in the form of cells with hyaline, and partly as free hyaline drops. As the latter alterations affected the periosteum and neighboring tissue, the author regarded them as a stage of chronic internal periostitis of the petrous bone caused by the neoplasm.

JANSEN: **An Intratympanic Tumor.**

A tumor without secretion grew inside of two years in the upper quadrant of the *Mt.* As there was suspicion of malignancy the tumor was extirpated. Various experts to whom the tumor

was handed differed in their diagnosis. It may have been a thyroid-like structure, or an epithelial tumor originating from the *Mt* or its blood-vessels.

MANASSE, in the discussion, thought that the growth was an adenoma.

PANSE: Exhibited Specimens.

I. Sequestrum Containing the Facial Canal.

II. Acute Middle-Ear Suppuration with Rupture through the Labyrinth into the Cavum Cranii.

SCHEIBE: **Rupture into the Inner Ear in Acute Middle-Ear Suppuration.**

CASE 1.—*A Diabetic Man of Fifty-six Suffered from Influenza; Acute Middle-Ear Suppuration; Repeated Paracentesis Necessary.*

Incisions permanently closed in ten weeks. A fortnight later relapse of the middle-ear inflammation, but without suppuration. Death in three weeks from meningitis. The specimen showed various stages of osseous affection, rarefying osteitis, softening, and necrosis.

CASE 2.—*Cholesteatoma; Rupture into the Horizontal Semicircular Canal.*

The exact time of rupture cannot be determined by symptoms. The rupture in acute suppuration varies from that in chronic, in that the former does not utilize the connective tissue but only the bone. There is no precise surgical method, and it must always remain expectant.

Discussion.—JANSEN: Rupture offers distinct symptoms. Through the canals we have vertigo, vomiting, disturbances of equilibrium, and nystagmus; through the cochlea, great deafness. Nystagmus alone justifies the diagnosis. Rupture may take place indirectly into the upper semicircular canal through a subdural abscess. In chronic cases the point of rupture is invariably the horizontal canal. The operation should consist in removing the horizontal or even the vertical canal with narrow chisels or with the electro-motor drill. The more violent the attack the more marked the disturbances of equilibrium. Proliferations into the aqueductus cochleæ may excite serous meningitis, but they can be removed by an operation.

HABERMANN remarked that rupture into the horizontal canal is frequent but operable. SCHEIBE is afraid of splinters of bone entering the labyrinth. PANSE has seen pressure on the canal produce nystagmus and vertigo.

KATZ: **Demonstration of Anatomical and Pathological Conditions in the Ear.**

1. *Normal Furrows and Openings in the Anvil.*

A dry anvil showed deep and spout-like furrows, especially at the long process. It would seem as if such furrows would easily give rise to caries of the anvil under proper conditions.

2. *Tensor Tympani, Mucous Folds, with Formation of Lacunæ and Isolated Granulations.*

The horizontal mucous fold belonging to the tensor, and not generally exhibiting any opening, forms normally a chamber, in which we may have retention of pus and granulations, as various preparations proved. Owing to this fold it is better to divide the tensor from in front than from behind whenever indicated at all.

3. *Coloboma on the Stria Malleolaris of the Mt.*

Elevation of the cutis by round-cell infiltration in the abundant subcutaneous tissue; the proliferation occurred between the cutis and the membrana propria.

4. Specimen showing the occurrence of *Ganglion Cells in the Region of the Inner Auditory Cells in New-born Mice.*

Cells in the cochlea near the inner auditory cells, which resemble the olfactory cells discovered in the olfactory region by Golgi. They are not seen in the outer auditory cells.

5. *Osmium Preparations of the Same Region in the Cat.*

Flattened internal auditory cells with fibres extending downward and of a doubtful nature.

HAUG: **I. Neoplasm on the Auricle.**

Elephantiasis of the auricle. Microscopic examination showed lymphangioma with transformation into sarcoma.

II. Treatment of Otitis Externa Acuta.

The author formerly employed acetated clay, but now relies on an alcohol bandage, with which in two or three days he often gets marked improvement. A strip of gauze is inserted into the meatus, alcohol dropped upon it, and then an impermeable bandage applied. This should be changed daily.

Discussion: HOFFMANN had employed the same treatment in Jena.

BRIEGER: **On the Relation of Hypertrophied Pharyngeal Tonsil to Tuberculosis.**

The author describes the results of the histological examination of the pharyngeal tonsil in 78 cases. The possibility of foreign-body tubercles occurring in the pharyngeal tonsil must be kept in

mind. In the five cases where histologically the presence of tuberculosis was proven, the picture furnished was a clear one. In every case cheesy degeneration was present, but tubercle bacilli could not be found. The tubercles were situated in the various layers of the tonsil; the rest of the tissue was not changed.

In 20 cases the entire or a part of the pharyngeal tonsil after excision was introduced into the peritoneal cavity of the guinea-pig. In one case the result was positive; in another, doubtful.

Injections of tuberculin caused a general reaction in a number of children with adenoids, but this is not conclusive.

The long-supposed relation between hyperplasia of the pharyngeal tonsil and tuberculosis, based on clinical observations, requires a more critical investigation. A similar connection seems to exist only for the cervical glands and tuberculosis. Primary tuberculosis of the lymphoid tissue at the roof of the pharynx may serve as a factor in the development of lupus of the face, for in lupus of the mucous membrane the naso-pharynx is more frequently involved than the nasal cavities. It is remarkable that a large number of cases of facial lupus present a shape of the palate which is typical of children suffering from adenoids.

It is very difficult to decide whether the tuberculosis of the pharyngeal tonsil in a given case is the primary and only localization of tuberculosis. In the author's cases the tuberculosis of the pharyngeal tonsil ran a latent course and appeared to be the primary lesion, though on more careful examination other manifestations of tuberculosis were found. A hereditary taint was always present.

The danger of a meningitis from a latent pharyngeal tonsillar tuberculosis scarcely exists, nor is it likely that an infection of the lungs can take place unless by way of the lymphatics. An extension to the middle ear, however, is to be feared. As regards operative treatment, the danger of a general tuberculosis from opening up of the blood-vessels is not sufficiently proven.

Owing to lack of time all further discussion of papers was voted to be omitted.

BIEHL: **Melancholia as the Result of an Otitic Extradural Abscess.**

Six weeks after the beginning of aural suppuration lasting a week, melancholia was observed, with ideas of persecution and suicide. In the intervals new suppuration and mastoiditis. Suppuration beneath the periosteum; fistula; dura exposed to the an-

trum, with granulations. The melancholia ceased on the day after the operation.

PANSE: **Tinnitus Aurium.**

The writer described his manner of registering cases of tinnitus. The patient's description of the noise, contents of the tympanum, the side affected, rhythm, pitch of the tone, influence of movement of the body, of alcohol instilled into the meatus, of pressure on the tragus, inflation, and so on. Next came the hearing tests, determination of the pitch of the subjective noise by comparison with tones greatly separated in the scale, the difference between which is gradually abbreviated to one octave. The nearest *c* is then used to note the pitch of the subjective noise.

OSTMANN: **Experimental Investigations on Massage of the Ear.**

The first part of this paper has already appeared in these ARCHIVES, and the second will appear later. The present part discusses massage as electrically applied, and suggests the possibility and dangers of using inadmissible force on the *Mt.* This sort of massage should only be used in cases of impeded conduction from rigidity of the ossicles with simultaneous rigidity of the *Mt.*

AFTERNOON SESSION.

NOLTENIUS: **The Operative Treatment of Stapes Anchylosis.**

CASE 1.—*Bilateral Tinnitus with Stapes Anchylosis.*—In one ear permanent recovery by massage after Delstanche's method. In the other ear no change. In this ear operation to remove the hammer and anvil. The crura of the stapes broke, and pressure on the plate caused it to sink into the vestibule. No immediate reaction, but later serous exudation, infiltration of the whole region about the ear, and paralysis of the facial nerve. The tinnitus disappeared permanently.

CASE 2.—*Essentially the same, but a total failure from the operation,* which resulted in stenosis of the meatus. The lateral wall was chiselled away in both cases.

R. HOFFMANN: **A Case of Isolated Thrombosis of the Bulb of the Jugular Vein,** and **A Case of Sinus and Jugular-vein Thrombosis.**

The diagnosis in the first case was proved by the post-mortem examination. Both cases were operated on.

DUNDAS GRANT: **On the Treatment of Stapes Anchylosis.**

The observation of the so-called paracusis of Willis (*i. e.*, improvement of the hearing in shaking carriages, and so on) suggested the idea of transferring similar vibrations to the vertebral column. These were produced by an electro-motor, and applied twice daily for five minutes at a time. Two patients were permanently and greatly improved in hearing by this method.

KIRCHNER: **Malignant Tumors after Chronic Middle-Ear Suppuration.**

Whilst chiselling for chronic middle-ear suppuration, the surgeon came upon an indefinable mass with undiscoverable limits. An autopsy, two months later, showed the entire temporal bone transformed into a soft substance, easily cut with a knife. The microscope revealed sarcoma.

JANSEN: **Transplantation of Skin in the Radical Operation.**

Jansen now employs the flap suggested by Koerner, and tries to make it as long as possible by prolonging the incisions into the auricle and excision of the angle of the cartilage in front of the antitragus. In spite of this, gangrene of the flap cannot always be avoided. If the recovery is retarded, thin skin-flaps may be used. This may be done before or after the flap operation, if there is but little bleeding, with the result of obtaining full recovery in six or seven weeks. Good results have also been observed in empyema of Highmore's antrum.

WAGENHAUSER: **Injuries to the Ear from Detonating Balls.**

The custom prevailing in Tübingen of throwing detonating balls produced in one instance rupture of the *Mt* with a high degree of permanent deafness.

BECKMANN: **Demonstration of Instruments.**

1. Scissors for the total removal of the inferior turbinates.
2. A catheter with strong curvature of the long beak.

BEZOLD closed the session with thanks for the interesting papers presented.

MISCELLANEOUS NOTES.

APPOINTMENTS.

The following gentlemen have been appointed members of the staff of the Throat Hospital, Golden Square, London: H. TILLEY, M.D. (Lond.), F.R.C.S.; ST. CLAIR THOMSON, M.D. (Lond.), M.R.C.P., F.R.C.S.; F. POWELL, M.D. (St. And.); C. HEATH, F.R.C.S.

THOMSON, ST. CLAIR, M.D., F.R.C.S., has been appointed Surgeon to the Royal Ear Hospital, London.

SPICER, FREDK., Jr., M.D. (Durham), M.R.C.S., has been appointed Honorary Surgeon to the Metropolitan Ear, Nose, and Throat Hospital, Grafton Street, Fitzroy Square, London.

ROYAL EAR HOSPITAL.

Her Majesty, the Queen, has given a donation of twenty-five guineas to the new Building Fund of the Royal Ear Hospital, of which institution she has for fifty-seven years been the Patron.

BEQUEST.

The late Miss Day, of Oxford, has bequeathed £500 to the Eye and Ear Hospital, Portsmouth.

LARYNGOLOGICAL SOCIETY, OF LONDON.

OFFICERS FOR THE ENSUING YEAR.

President, H. TRENTHAM BUTLIN, F.R.C.S.; *Vice-Presidents*, J. W. BOND, M.D., A. BRONNER, M.D., F. DE HAVILLAND HALL, M.D., SCANES SPICER, M.D., T. J. WALKER, M.D.; *Treasurer*, W. J. WALSHAM, F.R.C.S.; *Librarian*, J. DUNDAS GRANT, M.D.; *Secretaries*, HERBERT TILLEY, M.D., WM. HILL, M.D.

ANNOUNCEMENT.

SIXTH INTERNATIONAL OTOLOGICAL CONGRESS.

The Sixth International Otological Congress will be held in London, on August 8, 9, 10, 11, and 12, 1899. *President*:—

Dr. URBAN PRITCHARD, Professor of Otology at King's College, London. The meetings will, by permission, be held at the Examination Hall of the Royal Colleges of Physicians and Surgeons, Victoria Embankment. The subject chosen for special discussion is "Indications for Opening the Mastoid in Chronic Suppurative Otitis Media." A large and influential **British Organization Committee** has been formed, the Treasurer being Mr. A. E. CUMBERBATCH, 80 Portland Place, London, W., and the Hon. Sec., Mr. CRESSWELL BABER, 46 Brunswick Square, Brighton. The International Otological Congress, which assembles every four years, met last in Florence, where a very successful gathering was held under the Presidency of Professor Grazzi.

ORGANIZATION COMMITTEE.

URBAN PRITCHARD, President-Elect.

London: J. B. BALL, CHAS. A. BALLANCE, J. W. BOND, W. C. BULL, A. H. CHEATLE, Sir W. DALBY, G. P. FIELD, DUNDAS GRANT, F. G. HARVEY, W. HILL, T. MARK HOVELL, PERCY JAKINS, H. MCNAUGHTON JONES, R. LAKE, EDWARD LAW, L. A. LAWRENCE, F. MATHESON, STEPHEN PAGET, H. PEGLER, BILTON POLLARD, W. R. H. STEWART, GEORGE STOKER, ST. CLAIR THOMSON, H. TILLEY, E. WAGGETT, G. C. WILKIN, EDWARD WOAKES, P. M. YEARSLEY.

EDGAR BROWNE, Liverpool; ADOLPH. BRONNER, Bradford; F. W. BENNETT, Leicester; H. BENDELACK HEWETSON, Leeds; C. J. LEWIS, Birmingham; W. MILLIGAN, Manchester; WALTER RIDLEY, Newcastle; J. M. E. SCATLIFF, Brighton; GEO. STONE, Liverpool; H. SECKER WALKER, Leeds; P. WATSON WILLIAMS, Clifton.

THOMAS BARR, Glasgow; A. H. BENSON, Dublin; T. WALTON BROWNE, Belfast; KIRK DUNCANSON, Edinburgh; C. E. FITZGERALD, Dublin; MACKENZIE JOHNSTON, Edinburgh; A. BROWN KELLY, Glasgow; JOHNSTON MACFIE, Glasgow; P. MCBRIDE, Edinburgh; A. W. SANDFORD, Cork; E. B. STORY, Dublin; H. R. SWANZY, Dublin; LOGAN TURNER, Edinburgh; R. H. WOODS, Dublin.

J. W. BARRETT, Melbourne; F. BULLER, Montreal; J. J. CURSETJEE, Bombay; W. K. HATCH, Bombay; T. HOPE LEWIS, Auckland; T. M. NAIR, Madras; W. C. SCHOLTZ, Cape Town.

A. E. CUMBERBATCH, *Treasurer.*
E. CRESSWELL BABER, *Hon. Sec.*

Contents of the latest numbers of the German edition of these Archives. (Zeitschrift für Ohrenheilkunde).

Vol. XXXIII., No. 1. Issued July, 1898.

I. O. Körner. Hydrorrhœa nasalis, probably caused by a tumor of the hypophysis cerebri, perforating the sphenoidal cavity. (Appears in this number.)

II. H. Preysing. Two cases of pachymeningitis and extradural abscess from acute mastoiditis. (Appears in this number.)

III. P. Manasse and A. Wintermantel. Report on 77 radical operations, Strassburg University ear-clinic.

IV. Report on the dispensary department of the Strassburg ear clinic during the years 1896 and 1897.

V. Thos. Barr. Case of labyrinth necrosis. (Translated from the English edition.)

VI. A. Barkan. Chronic middle-ear suppuration; brain abscess, meningitis; operation, death. (Translated from the English Edition.)

VII. Seligmann. Report on the seventh meeting of the German Otological Society at Würzburg. (In this number.)

Systematic report on the progress of otology during the second quarter of the year 1898. (Will appear in our next issue.)

Short notes of societies, and book reviews.

Vol. XXXIII., No. 2. Issued September, 1898.

VIII. Edward Hartmann. Two new cases of osseous anchylosis of the stapes. (From Prof. Siebenmann's ear-clinic in Basle.)

IX. L. Treitel. Carcinoma of the ear.

X. Fr. Bezold. Method (Schema) of examining the hearing power of diseased ears.

XI. Bezold and Edelmann. Recording the vibrations of tuning-forks, and testing the acuteness of hearing according to correct proportions.

XII. F. Siebenmann. On resection of the cartilage; a new modification of Körner's method in cholesteatoma operations.

Minor reports.

CONTENTS OF VOLUME XXVII., NUMBER 6.

PAGE

1. A Contribution to the Surgery of the Temporal Bone. By Dr. **Robert Sattler,** Cincinnati, Ohio 473

2. Purulent Thrombosis of the Lateral Sinus. Epidural Abscess. Extensive Subperiosteal Abscess with Œdema of the Scalp, Face, and Neck. Operation. Recovery. By **John Dunn,** M.D., Richmond, Va. 494

3. Purulent Mastoiditis Complicated by Epidural, Subpetrous, and Post-Œsophageal Abscesses; Death Presumably from Internal Hemorrhage. By **John Dunn,** M.D., Richmond, Va. . . . 498

4. A Contribution to the Clinical Stages and to the Technique of the Operation for Sinus Thrombosis. By **Fred. Whiting,** M.D. . 506

5. Systematic Report on the Progress in Otology during the Second Quarter of the Year 1898. Arranged by Dr. **Arthur Hartmann.** Translated by Dr. ARNOLD H. KNAPP 544

6. Report of the Transactions of the Section on Ophthalmology and Otology of the New York Academy of Medicine. Otological Meeting of Nov. 21, 1898. By Dr. **W. B. Marple,** Secretary . 571

   E. Gruening: Extensive Suppuration in the Mastoid and Surroundings, which had Developed after a Perforation of the Drum Membrane in Acute Otitis Media had Closed and the Patient Appeared Cured 571

   Arnold H. Knapp: Bezold's Mastoiditis without Perforation of the Drum Membrane. Recovery after Operation 572

   Frederick Whiting: A Contribution to the Clinical Stages and to the Technique of the Operation for Sinus Thrombosis. . . 572

   Discussion: Drs. ABBE, RANDALL, KIPP, BACON, SHEPPARD, and LILIENTHAL.

   Herman Knapp: Two Cases of Otogenous Pyæmia. The One Fatal; Autopsy. The Other Ending in Recovery 576

7. Book Review 577
   A Manual of Otology. By Gorham Bacon.

8. Miscellaneous Notes 581
   Appointments.
   Obituary.
   Announcement.

9. Contents of the Latest Issue of the *Zeitschrift für Ohrenheilkunde* (German Edition of these ARCHIVES) 583

10. Index of Authors and Subjects of Vol. XXVII. 585

ARCHIVES OF OTOLOGY.

A CONTRIBUTION TO THE SURGERY OF THE TEMPORAL BONE.

By Dr. ROBERT SATTLER, Cincinnati, Ohio.

I.—INTRODUCTION.

NOW that it is generally recognized that the same principles which guide the general surgeon in his discovery and treatment of other focal bone-lesions must also be applied to the concealed and treacherous lesions of the temporal bone, aural surgery has scored many brilliant triumphs and made rapid advances.

This discovery is not one man's, nor does it belong to one country. It was foreshadowed for years by a growing dissatisfaction with, and an open, defiant criticism of, the inadequacy of the older surgical methods practised for the relief of the graver complications of middle-ear disease. Their technique was recognized as faulty, the instruments as cumbersome. They failed of purpose, almost invariably, in those uncommon complications,—sinus thrombosis, cerebral and epidural abscess, cholesteatoma, etc.; and succeeded only in such cases in which there was almost a certainty of diagnosis of an incarceration of pus, of bone caries or necrosis, because unmistakable local and constitutional symptoms were present. But even in these, eminently more favorable cases for surgical treatment, in which the main object was accomplished and a free opening in the bone for pent-up pus was made and maintained, and, in addition, granulation tissue, ulcerated or sequestered bone were removed, it was not always successful. In many cases experience taught that, in spite of what was done with the greatest thoroughness, only the more prominent symptom-

atic indications were met, and a fatal termination resulted because hidden foci of disease exciting insidious complications were overlooked.

In Germany, lasting credit will surround the names of Schwartze, of Halle, and his followers among aural surgeons, but an equal share belongs to the general surgeons, Bergman, Küster, and others. Of Macewen, Lane, and others in England, and of a long list of names in this country, distinguished mention must be made for prompt recognition of the teachings of the German surgeons, and for having been among the first to put to practical tests a truth which at that time and even long before was recognized, but acted upon only in exceptional cases;—**that, as other focal lesions of bone, the most inaccessible regions of the temporal bone should receive the same treatment by the same methods applicable to similar processes elsewhere, viz., complete exposure of the diseased areas for exploration and inspection, followed by such surgery as the special indications or needs may call for.**

Even greater distinction belongs to German surgery. The suggestion to replace the old-fashioned drills, trephines, etc., for the simpler instruments of chisel, gouge, and mallet, was first made and generally adopted for the surgical treatment of these cases in Germany.

The introduction of these surgical appliances in exchange for those formerly employed, aided by modern aseptic and antiseptic accessories, marks the real advance of aural surgery for this important region. It enlarged the scope for rational surgical interference. It led to the invention of new methods and to an increasing perfection of technique, to meet special needs in certain cases.

The most convincing proof, however, of the practical value of the simple proposition referred to, and the surgical methods which it suggested, was evidenced by its immediate and almost general recognition. As already stated, there were ill-defined visions of its approach for many years among progressive general and aural surgeons. It required, however, a master mind to prepare it, after ripe personal experience and practical tests, and recommend it as a safe,

rational, and eminently practical discovery. A flood of literature since then in Europe and this country has done little more than to confirm what was so fully and clearly explained by the earlier advocates of these more rational surgical methods.

The promulgation of the simple proposition that a focal bone-lesion here, as elsewhere, can only be treated by thorough exposure of its seat, and that in some cases this is expedient even for accurate diagnosis, has become a recognized truth.

With insignificant restrictions, this sounds the key-note for successful surgical interference, and must be accepted as a secure guide in the management of these cases. Here, again, it was Schwartze (to whom aural surgery is mainly indebted for so many valuable discoveries and suggestions) who pointed out that the radical methods practised for this region by the general surgeons could not and would not be accepted by aural surgeons. The complicated structure of the temporal bone, the passage through and close proximity of important nerve-trunks and blood-vessels, not to mention the physiological significance of the organ of hearing in its innermost recesses, combine to demand for the surgery of this region, special qualification, skill, and painstaking care.

Familiarity with the practical surgery of this region, and an early conviction of the truth and superior advantages of the discoveries referred to, lead me to report, in brief, a series of cases illustrating rare expressions of disease, and uncommon experiences in the management of grave complications of middle-ear disease, for which surgery was necessary. This will include uncontrollable neuralgic affections of the mastoid, chronic empyema and Bezold's disease, medial perforation,—dural dissection and abscess,—sclerosis, and rarefaction of the temporal bone.

II.—UNCONTROLLABLE NEURALGIA OF THE MASTOID.

The fierce and inveterate outbursts of neuralgic suffering of this region were first accurately described by Schwartze. He, as well as Knapp and Matthewson, in this country, also

suggested and practised a simple but almost uniformly successful surgical method for its relief.

For all cases in which a purely neurotic origin can be assumed, the operation of opening the mastoid (Schwartze) *affords almost certain relief.* It is not even necessary in all cases to penetrate to, expose, or break down the deeper pneumatic cells of this locality. In a certain limited number only, in which the intense suffering is associated with remote sequences of former lesions of the middle ear and its accessory cavities, may it become expedient or necessary to expose the deeper cells, and, in exceptional cases, even to open the mastoid antrum.

If surgical intervention for the relief of this inveterate expression of neuralgia had not disclosed that in the larger number of cases absolutely no morbid changes are present, and in a certain smaller number traces only of former pathological processes are found, we could consider them all under one group, for clinically they correspond exactly. For the reason stated, *two classes must be considered.*

The first, or larger group, includes the purely neurotic cases. Surgical interference here secures prompt relief, but fails to disclose any apparent or discoverable lesion of the bone, periosteum, middle ear, or adjacent pneumatic cavities.

In these cases, we are constrained to admit, in the absence of every tangible evidence,—except hysterical, neurasthenic, and other abnormal emotional manifestations, the result of an overwrought nervous system due to various causes,—a neurotic origin.

The second and smaller group comprises those cases in which the neurotic factor is less dominant. Surgical interference leads to the discovery that a former, and in most instances remote, pathological process has been present and left its traces. These, however, remain as latent during the acute outbreaks of suffering as they were before.

This feature which both classes have in common must be emphasized. At the time of occurrence of the neuralgic paroxysms, it is impossible to discover in the cases belonging

to either group any local or other adequate cause for the intense pain.

Surgical intervention is generally successful in both, and in those of the first or purely nervous group almost uniformly so. The same certainty of relief, however, cannot be counted upon for those of the second group. The reason for this is evident.

Surgery for the purely nervous cases proves itself in our hands a powerful measure of suggestion. The local injury and actual inflammatory disturbance which it creates, together with the dominant idea of expectancy that relief from suffering is at hand, generally result in its prompt cessation. We have simply substituted for the psychical or central suffering referred to this region, of seemingly interminable duration and unbearable intensity, a real or actual one, inflicted by the carefully guarded traumatism of the operation, of the same nerve-trunks at their peripheric termination, but with a prospect of a more definite duration, and certain relief. The patient's attention is forcibly directed from the pernicious habit of self-contemplation and a review of personal sufferings, and more effectually shielded from the meddlesome sympathy of his friends and relatives.

Surgery is successful in these cases, as the rest-cure proves itself for similar neurotic disturbances,—confirmed neurasthenia, hysteria, etc.,—in which the combined moral management of an intelligent physician and specially trained nurse, aided by enforced isolation and a prolonged rigid and irksome régime, brings about a favorable termination.

For such cases, this is not alone the most rational, but the only successful course of management. This by no means excludes the assumption that the operation may exert its beneficial effects by relieving local morbid changes, so slight as to elude discovery,—such alterations bringing about an imperfect communication, or even a complete shutting off, between the deeper and superficial cells, or between the latter and the mastoid antrum.

Referring to certain cases met with among the second group, such an explanation is suggested, and it may apply

with equal force of argument to the purely neurotic ones without any tangible local evidence whatsoever.

It is the purpose here, mainly, to refer to those cases in which surgical intervention disclosed positive changes which, however, in every instance under my observation had to be considered of remote origin, and, it must be added, were not suspected until the operation led to their discovery.

Clinically, there is a close resemblance between the cases of either class. To describe the one also describes with but slight differences the other.

It is certainly superfluous to multiply reports of the purely neurotic cases of the first group; they have been repeatedly mentioned by others and are thoroughly understood. Mention is made only of one typical case to supplement what may have been omitted in this brief clinical description.

The *conspicuous clinical symptom is pain.* In duration and in severity it is far in excess of that which accompanies even the most violent seizures of intercostal and trigeminus neuralgia.

The attack may be insidious in origin, or occur with lightning-like; rapidity in duration, it exceeds other neuralgic paroxysms, lasting without cessation for days and weeks, with occasional short remissions, without fever or other constitutional disturbance. The most exquisite surface tenderness over the entire mastoid region, auricle, and external auditory is present, without redness or swelling,—in other words, the characteristic feature is the absence of active inflammatory or other evidences on the part of the auditory canal, middle ear, its accessory cavities, the bone or its covering. The external auditory canal is abnormally sensitive. The slightest contact or the most delicate manipulation attending the introduction of a speculum for necessary inspection of the drum and middle ear can be made only amidst protestations of the greatest suffering.

During the height of the attack surperficial and deep-seated neuralgic spots, or "point-pains," are present. The tip of the mastoid and the deeper recesses of the external auditory canal are generally referred to as the localities of the most intense pain.

The conspicuous feature is their uniform resistance to treatment of every kind, except surgery. In most instances, every local and internal remedy, except the crowding with narcotics or chloroform anæsthesia, is defied, and amelioration or cessation of suffering comes about only after tedious, unrelieved pain has completely exhausted the patient's strength and obtunded his sensibilities.

A danger always in lurking evidence is that the acquisition of the morphia habit may add a hopeless complication in these unhappy cases.

As already stated, the following brief description of a typical case is given simply to supplement a necessarily brief report of the clinical history.

CASE I.—The patient was the wife of a fellow-practitioner. She had been for years a great sufferer from neuralgia in other parts of the body, but for severity and unendurable distress, the most violent attacks of intercostal, ovarian, and trifacial neuralgia to which she had been subject could not be compared to the insufferable and prolonged pain which localized itself in and about the ear, and which had persisted for weeks in spite of every method of treatment. Her husband assumed that catarrhal changes of the middle ear might account for the pain, and had resorted to inflation and also to the most active anti-neuralgic remedies, but the suffering became so severe that morphia had to be used to obtain relief. This had to be kept up so long that it was evident that the habit if not already established would soon be.

At this stage of her suffering he brought her to me.

The examination of the ear was negative. Functional tests normal. I could not even satisfy myself that catarrhal changes were unduly pronounced. Examination by the aid of the catheter disclosed nothing abnormal. The catarrhal changes of the fauces and nose were not more or less pronounced than we see in neurotic subjects. The most exquisite sensitiveness, without redness or swelling, was found over the entire mastoid region, with points of excessive pain when parts over the tip of the process and in the external canal were touched.

A free opening of the cortex over the entire mastoid region was made. The cells (which contained neither serum nor inflammatory exudate) adjacent to the surface were broken down and

the whole region converted into one large cavity without penetrating to the deeper cells of the mastoid antrum.

The healing and subsequent course offered no features of interest. Relief was complete and morphia was gradually discontinued, and the suffering, which had lasted for many weeks, was arrested completely by the simple operative interference resorted to.

Taking up the special purpose to refer to the more uncommon cases of the second group in which the operation reveals more tangible evidence of former pathological changes, *it must at the outset be stated that whatsoever such changes proved to be, they were only disclosed at or during the time of the operation which was undertaken as an empirical measure after all other methods of treatment had been exhausted.*

The discovery of the various changes about to be mentioned is the more surprising because there were no clinical or other evidences which suggested even their probable existence.

A strong neurotic element was also in marked evidence in these cases. *Like those of the first group there is an absence of every local disturbance of the bone, periosteum, middle ear, or adjacent cavities.*

It must furthermore become evident that the morbid changes discovered at the time of an operation (opening of the mastoid) for the relief of pain must be considered sequences or markings of remote former pathological processes. This is certainly upheld by the cases under my observation. In not a single instance did the history suggest or refer to any other than a very remote antecedent lesion, and at the time of the uncontrollable outbursts of suffering there was absolutely no evidence of a more recent one. My experience forces me to assign these pathological findings to three divisions:

I. **Hyperostosis or sclerosis** of the cortical region of the mastoid, eburnation, with partial or complete obliteration of the pneumatic spaces and antrum.

II. **Rarefaction of the superficial and deeper cells, with atrophy of the cortex and desiccation or atrophy of the lining membranes of the cells.**

III. **No apparent lesion of the cells, but the presence of desiccated bone or other products in the antrum or posterior pneumatic cells,** affording sufficient evidence to warrant the assumption that free communication between the superficial and deeper cells had thereby been interrupted or even completely shut off, resulting in a derangement of their physiological purposes, and causing as a possible remote sequence the excessive pain.

Mention is first made of two cases of *hyperostosis with ivory-like hardness of the bone*, not suspected until the operation, which was undertaken for the relief of uncontrollable pain, revealed it.

Prompt relief was afforded in one case, but in the second was incomplete.

CASE 2.—Mrs. M. S., æt. forty, Chillicothe, O. Has passed through a long period of ill-health. For years she suffered from almost constant headache and neuralgic paroxysms. When she first consulted me it was to seek relief from persistent vertigo and tinnitus. She had unmistakable catarrhal disease of the nasopharynx and middle ear. Inflation with the catheter and the ordinary local treatment relieved her. She suffered so much from headache, with every indication that it was reflex or of pelvic origin, that she was referred to a gynecologist. Oöphorectomy was done, and for several months after recovery she was more comfortable, but tinnitus and vertigo, the latter, in part at least, unquestionably of aural origin, continued, and for almost eight (8) months she suffered excessively from pain in the left mastoid region. There was neither redness nor swelling. The drumhead, aside from catarrhal changes, showed nothing abnormal except a localized cicatricial change, the probable site of a former perforation. She stated that during her early girlhood she frequently suffered from earache and discharge, but for many years had not experienced any trouble of this kind. Local and general treatment was tried, but failed to afford more than temporary relief. Assuming that an obscure lesion of the middle ear and antrum might possibly explain the symptoms, surgical treatment was proposed to open and explore the cells and antrum. The operation disclosed complete solidification of the temporal bone, with increase in thickness and hardness.

After hemorrhage of the soft parts was arrested, further opera-

tion on the bone was bloodless. The cells, even the posterior ones, were found completely solidified, and when the antrum was finally reached, at an abnormal depth, it was found contracted so that the bulbous end of an ordinary probe could hardly enter it. It was empty, and as the hearing of this ear was fairly good, and no positive evidences of disturbance of the ossicles or middle ear existed, it was not thought advisable to explore this region. The opening into the antrum was enlarged, so that it helped to form the bottom of a large oval opening, which extended to the tip of the mastoid. The bone was so much hypertrophied that a large quantity of it had to be removed.

The violent neuralgic seizures disappeared for two years, but since then have returned with lesser frequency and intensity, but with exquisite local sensitiveness of this region. The deep concavity of the external opening is closed by a smooth scar.

CASE 3.—Sister C., æt. twenty-one, a teacher in one of the largest educational convents of Cincinnati, had always enjoyed excellent health, was physically well developed, and had no menstrual irregularity. About four months ago she began to suffer from what she supposed was earache, but without discharge of any kind from the ear.

Her duties had for several months been onerous, and she was under a great nervous strain. The pain in the left ear, "in the bone behind the ear," became more and more violent, and anodynes internally and externally failed to afford relief. She was so exhausted in consequence of unrelieved suffering and the long-continued use of morphia, that I was called to see her in consultation. Careful examination failed to disclose tangible local reasons for the excessive pain; the meatus was dry and free from discharge; the drumhead was intact, aside from sclerotic changes, and the mark of an old perforation in or near Shrapnell's membrane. Inflation was readily accomplished, and hearing power was not impaired. There was no displacement of the auricle or redness or swelling behind it. The pain was excessive, and radiated from a spot over the tip of the mastoid into the external auditory canal to another deep in the ear. The most exquisite local sensitiveness was present. After again trying local remedies and failing preliminary to the operation, which was at once suggested as the surest means for relief, this was made.

It disclosed a thickened cortex and obliteration of the superficial and middle cells. The bone was hard, white, and almost

bloodless. Fearing a possible accumulation or other lesion of the antrum, this was explored, found empty and small, though not abnormally contracted. The bone was thoroughly excavated, and as much of the hyperostosed area removed as was deemed expedient. Recovery was satisfactory. The pain completely disappeared and she soon resumed her duties.

A neurotic factor was present in both cases, and an unmistakable hysterical element in addition in Case 3. This one would certainly have been classed with the purely neurotic cases had not the operation disclosed marked sclerosis of the bone.

In commenting further on cases of excessive suffering, in which hyperostosis and other morbid changes were suspected and found,—caries of the attic and antrum, sequestration of the ossicles, etc.,—more explicit mention will be made of the morbid anatomy of bone-hypertrophy and its sequences, so far as these are concerned with known pathological processes before operative intervention was resorted to.

It remains in the cases under consideration, however, an open question whether the abnormal thickening of the cortical regions of the bone, as well as the contraction or complete obliteration of the pneumatic cells, can be considered a local factor of causation of, and especially whether these changes are concerned with, the excessive pain.

In this connection we can instance that local thickening, or bone-sclerosis, occurs not infrequently as the result of mysterious chronic non-inflammatory disturbances in which absence of pain is also a characteristic feature. Again, in other localized hypertrophy of bone, due to known acute and chronic inflammatory changes, pain is a conspicuous attendant.

We have only to instance as belonging to the former,—non-inflammatory, painless lesions,—the numerous freaky manifestations of congenital and late syphilis and those rare cases of hyperostosis cranii or leontiasis ossea (Virchow); among the latter,—the inflammatory lesions with pain,—the manifold expressions of osteophytes, hyperostosis, and exos-

tosis, as the result of syphilis, the rheumatic and gouty diathesis, etc.

So far as this concerns or applies to the long bones, the sternum, and some of the bones of the cranium, this cannot be denied, and the statements made apply to both non-inflammatory thickening without pain as well as to the same with pain.

Another question, and this touches upon the physiological purposes of the pneumatic spaces of the skull in general, is whether chronic pathological changes of low grade (which, it is reasonable to assume, must derange the physiological purpose, whatever this may be) do not furnish another cause for the increased growth of bone of the walls of the cavities. My own conclusions, based upon a limited experience with the surgery of the other pneumatic cavities, especially the frontal and maxillary sinuses, rather incline me to the opinion that latent chronic changes of these localities, and of the temporal bone in particular, must be mentioned among the very uncommon causes for pathological changes (especially hyperostosis with contraction, and atrophy with rarefaction of the cells, etc.). A lesion of the pneumatic spaces of the temporal bone, which we know must in so many cases be insidious in origin and latent in its course, because of the concealed location and resistance offered by the bony encasement of its walls, can only disclose its presence by indefinite clinical manifestations, and in some cases by an entirely latent course.

Eventually, such a process, already indefinitely prolonged, is imperceptibly arrested. Hyperostosis or sclerosis of the walls, with contraction or obliteration of the lumen of the cavities, results as a final termination. Why this should be attended in some instances by excessive pain, and not in others, cannot be explained until more complete clinical studies and pathological examinations furnish us with more reliable data. As already stated, a neurotic factor is of dominant evidence in most cases, and was present even in the two cases just mentioned. Whether the two, sclerosis and excessive pain, sustain a relationship of cause and effect can only be answered, by saying that it is not improbable on the support furnished

by cases under my observation; the other conclusion, that it may, after all, be the neurotic element alone which is responsible for the pain, and that the local changes disclosed at the time of an operation undertaken as a measure of suggestion and rational empiricism are only accidentally associate, but not directly causative factors, is thereby not denied.

The following brief histories recite morbid changes which are the opposite of those just mentioned and which belong to the second division of this group of cases. The pathological alterations which were discovered in these cases refer to atrophy, or rarefaction, of the cortical area, dilatation, in some instances to enormous dimensions, of the air-cavities of this region, with atrophy or xerosis of their lining membrane.

CASE 4.—A. G., æt. twenty-six, Huntington, W. Va. A delicate woman, whose appearance suggested ill-health and a frail physique, came to me with the history of excessive and prolonged neuralgia of the mastoid on both sides. During girlhood and early womanhood she had repeated and violent suppurative inflammation of the drum cavity in both ears. For five years she had suffered excessively from violent outbursts of pain, at times on one, and then on the opposite, side, lasting for weeks, necessitating morphia in such quantity that she became addicted to its use. When I first examined her there was an absence of all local inflammatory disturbance, both drums were retracted and perforated in several places, and showed the destructive changes which had so often invaded this cavity. There was no discharge; but in the right ear, in which the suffering had been most violent, it was thought that the probe introduced into the middle ear through the perforations detected a slight offensive cheesy substance. There was neither swelling, redness, nor tenderness except during the paroxysms of suffering. Suspecting a cholesteatomatous blocking-up of the attic and antrum, an operation to explore these cavities was at once undertaken.

The operation, first performed on the right ear, disclosed an exceptionally thin and brittle cortex, with enormous rarefaction of the cells, even to the very tip of the process, and adilated antrum partially filled with desiccated epidermis cells and caseated pus. The remarkable feature was the dry and lead-colored changes of the lining of the cells and antrum.

The method (Schwartze's) of opening the cells and antrum was now supplemented by the complete removal of the posterior wall, and a large open cavity, which embraced the dilated cell-area and antrum, exposed for subsequent treatment and drainage. The hearing, considering the changes, was exceptionally good, and as, on careful exploration, there was no evidence of caries of the ossicles or a lesion of the attic, further surgery in this region was deferred. The meatus was split after the suggestion of Stacke, and the wound closed and drainage effected through the ear. The other ear was subsequently treated in the same manner—with this exception, that the method of Küster was adopted. In both ears the operation brought immediate relief from the excessive suffering. Hearing was slightly reduced as the result of the operation in the left ear, but more so in the right. During the intervening two years she improved in health, and only had a recurrence of neuralgia in the right ear once since the operation.

This case and one other, in which the dilatation of the cells was abnormally great and the cortex of the bone very thin, led me to infer that these pathological changes are also indirectly concerned with the pain, for the relief of which symptom alone, without other evidence, the operation was undertaken.

Rarefaction of the walls of the cell-cavities of this region is not an uncommon disclosure of surgical treatment if practised for other chronic, and even in some sub-acute, lesions, the character of which is known. This is so well established that further reference to it is unnecessary.

Dilatation of these cavities, however, such as was found in some of my cases, is a different affair. It recalled to mind other experiences undertaken with a definite purpose to seek pus or other pathological changes, and which proved to me how rapidly dilatation of the cells of this region can take place, if filled, as a result of a *low grade of sub acute inflammatory activity, with spongy granulation tissue.* That the same result must take place more markedly after a longer or almost interminable period in the chronic cases, is evident.

These two cases are briefly mentioned because of their bearing on this point.

CASE 5.—In this case, a young German in the Betts Street Hospital of Cincinnati, during his convalescence from an attack of typhoid fever, developed acute otitis media, left side. He was much emaciated and feeble. The pain in the ear was excessive, and followed by a purulent discharge which lasted about eleven days and then ceased. Shortly after this he began to suffer with pain in the mastoid. He was at this stage of his trouble transferred to my service. There was no discharge. The drumhead was still reddened and the site of the perforation distinctly visible. Inflation was readily done and there was no fluid in the middle ear. There was no displacement of the auricle, only slight swelling over the mastoid, but no redness. On firm pressure the pain excited was severe, but moderate on slight pressure. He complained constantly of deep-seated distress, and exacerbations of greater pain occurred from time to time.

The mastoid was opened; the first few chips of bone removed showed us a thin cortex, through which granulation tissue was extruded with a small quantity of serous fluid, but no pus. When the opening was enlarged the pent-up contents of the cells forced out a quantity of compressed granulation tissue which was surprising. Recovery was prompt and relief complete.

In another case of frontal-sinus disease the same observation was made. Chiselling away the thickened outer wall gave access to the sinus, which was enormously rarefied and filled with compressed granulation tissue, which once liberated extruded like a sponge through the opening.

It is evident that one of two results must take place in such and similar cases: either an acute process is engrafted upon the latent chronic one, terminating in acute empyema with spontaneous perforation and fistulæ, or the acute suffering and constitutional symptoms become so alarming that surgical interference of some kind becomes imperative.

If acute empyema does not follow, the acute symptoms may gradually subside, in some instances, after months or even years. The crowding or packing with elastic granulation tissue and other inflammatory products produces a distention of these spaces, followed by a slow absorption of their contents and atrophy of their lining-membrane, with thinning of their bony enclosures.

Just such cases enable us to understand the interminable

chronicity and latent course if we assign a similar cause for these cases.

They also teach us that throughout their long course positive clinical evidences are often entirely wanting, and unless acute empyema is added and danger of life threatens, their real nature is overlooked, or they are not at all recognized until this region becomes the seat of unbearable neuralgia for which surgery alone affords relief, and at the same time discloses these unlooked-for pathological changes.

We take up next in order those expressions of excessive pain which belong to the third division of the second group.

In most instances, a history of more recent acute or chronic pathological processes of the middle ear can be obtained.

At the time of the attack of pain, these, however, are either entirely passed or wholly latent. The neurotic factor is almost as prominent as among the first group. The assumption that, as a result of a process in the middle ear and antrum which has run its course, there is excited in the adjacent air-cavities of this region a disturbance of their physiological relationship resulting in their complete shutting off (this in some cases being due to the presence of exudative products, in others to the inflammatory occlusion of the communicating channels between the cells), requires more proof than has so far been afforded by the limited observation of these uncommon cases.

A more rational explanation in confirmed neurotic and hysterical subjects may be that during the long period of convalescence from middle-ear lesions, the harassing symptoms of deafness, tinnitus, and occasional paroxysms of pain which last in such patients for weeks and months, result in physical and nervous depression which a prolonged and renewed concentration of former sufferings precipitates into violent seizures of neuralgia of this region.

In illustration of the probability of this conclusion the two following cases are cited.

CASE 6.—A. P., æt. sixty, a retired merchant of Cincinnati, had just recovered from a tedious attack of acute otitis media, with

perforation and discharge, under the treatment of a conservative practitioner. It was first thought that inflation and the usual treatment, now that the discharge had disappeared, would bring about more speedy return to health. Long confinement, meddlesome sympathy of his friends, and a knowledge of the possible dangers of middle-ear troubles, effectually thwarted this conclusion.

When I first saw him, having been confined to the house for three months, he referred to excruciating suffering in the region of the mastoid. There was great tenderness, no swelling, and little redness. No constitutional disturbance. The pain resisted local and general remedies, and the operation was proposed and practised.

The cortex was removed, the cells, which were empty, broken down for a considerable depth, but the antrum was not opened. My experience with these cases (eight years ago) had not convinced me of the advisability of exploring the antrum in similar cases. The patient recovered rapidly and permanently.

A curious feature was that, during the stage of convalescence or after the operation, an old friend of the patient who had watched the progress, was, as the result of worry, want of occupation, and mental concentration, attacked with the same symptoms, which persisted for six weeks without any active ear trouble. It was simply another illustration of purely neurotic origin. He was threatened with the operation, but eventually recovered without it.

CASE 7.—Another case, Sister D., æt. twenty-six, has had for years chronic catarrhal otitis media with subacute exacerbations. After one of these attacks in the right ear, sensation of fulness and pain over the mastoid were complained of. This, to the patient, a typical hysterical subject, became, after three months, unendurable. A free opening was made; the cells were numerous but appeared normal; the antrum was explored, and in it and in the posterior pneumatic cells dried but not offensive secretion was found in considerable quantity.

Recovery in this case was prompt, but relief from neuralgic pain was not complete. It returned, at long intervals, after one year.

Referring once more to the last division of the second group, and assigning it, because of insufficient proof, to the first group among the purely nervous cases, there neverthe-

less remain the two divisions of the second group which we cannot dispose of by the assumption that they also belong to the first group.

In conclusion, a brief summary may recite the principal points:

Excessive uncontrollable neuralgia *of this region* is an uncommon expression of a neurosis which selects the mastoid region of the ear for its explosive activity.

It has not been thoroughly appreciated either by aurists or neurologists. The former have oftentimes suggested erroneous conclusions and wrong diagnoses because they were misled by the pain to suspect a more pronounced lesion which is not present.

The cases which belong to this category are not of inflammatory origin.

They all have one feature in common and this is a dominant neurotic factor. For this reason pathological findings are absent except in the cases mentioned. For the latter even it is impossible, in the present state of our knowledge, to assume more than that they are in some manner concerned with the paroxysms of pain. The origin of the pain is as mysterious as in other similar cases elsewhere in hysterical and neurasthenic subjects, and for which a perverted nervous activity, due to and associated with various causes, is assigned for want of more positive evidence.

Surgery, opening of the mastoid (Schwartze), if practised with thoroughness, affords prompt and almost certain relief.

Whether the relief which surgical intervention almost without exception affords, rests on any other explanation than that it is a forcible measure of suggestion, or whether it is the means of relieving morbid changes so slight that they cannot be discovered, but which cause a derangement of physiological relationship of function, innervation, and circulation of these pneumatic accessories of the middle ear, must for the present rest, in part, on conjecture.

III.—CHRONIC EMPYEMA.

Chronic empyema of the mastoid cells is so well understood that reference is confined to the more uncommon

experiences with this lesion. Among these must be mentioned the one here briefly referred to, in which neither the antecedent history nor the most careful local examination could discover more than a chronic catarrhal middle-ear lesion with an intact drum membrane.

CASE 8.—Mary F., æt. forty-eight, has been an inmate of the City Hospital for months, both in the wards of the venereal and aural departments. She is a broken-down syphilitic subject with confirmed hysterical tendencies. For months she has been retained, receiving the customary treatment for her chronic catarrhal throat and ear troubles, because she was useful in helping as a chore woman about the ward. She complained of tinnitus and impaired hearing, but in addition almost constantly of excessive surface tenderness of the auricle and region around the right ear. There was never either redness or swelling of this region or displacement of the auricle. The auditory canal was in lumen and appearance normal and free from discharge. The drum was sclerosed, discolored, and relaxed. The fauces showed the results of former destructive disease. There was no fever or other constitutional disturbance, and never any severe paroxysms of pain. Taking into account the almost incessant complaints and the dominant neurotic element, an exploratory operation was resorted to. It disclosed *a thick vascular but rather brittle cortex, and, what was unexpected, an enormous collection of pus.* The posterior cells and antrum less implicated. The entire region was converted into a large cavity freely communicating with the antrum. The patient made a favorable recovery.

This case is mentioned because every local evidence of a pronounced pathological process was absent. Except for the uncommon symptom of persistent hyperæsthesia of the auricle and parts about the ear it was wholly latent. The firmest pressure failed to excite pain. There was no visible participation on the part of the drum cavity and no constitutional disturbance.

Late syphilis and a general undermining of her nutrition were probably the exciting elements for the low grade of inflammatory activity which was present. The more active or direct cause for this insidious lesion was the forcing of micro-organisms or pathogenic products during the active

(destructive) stage of the syphilitic throat lesion along the Eustachian tube into the middle ear, thence into the adjacent pneumatic spaces as the result of inflation, which was persistently practised for weeks.

This confirms an oft-repeated warning that inflation of the middle ear, practised for the relief of a chronic catarrhal middle-ear lesion with patulous Eustachian tubes and relaxed membranæ tympanorum, associated with an ulcerative lesion of the fauces, may, just as in acute aural complications, lead to, or even precipitate, an invasion of the pneumatic cavities. It is of interest, further, because it points to the surgical exploration of this region not alone as justifiable, but as necessary in these uncommon cases, just as it must also be considered for similar latent processes on the part of the nose exciting chronic purulent lesion of the frontal sinus, or on the part of the teeth with the maxillary sinus.

That a similar latent course may occur in more acute disturbances and of more recent origin is borne out by the following case.

CASE 9.—A young man during the stage of convalescence from a severe attack of malarial fever was transferred to my service in the City Hospital. He had been treated for an acute right middle-ear inflammation for several days in the medical ward, and when he was first seen by me the more acute constitutional and local symptoms had passed. There was a large perforation and free purulent discharge. This yielded to treatment, and after four weeks the discharge had ceased and hearing had returned and there was little or no complaint of the ear. It was noticed, however, that he was dull and listless and carried his head in a fixed position and inclined to the right, and he complained constantly of headache, which was general and only at times more marked in the frontal region. These symptoms continued, but neither local tenderness nor swelling nor pain, even on firmest pressure, caused complaint. The temperature was not abnormal, and the only persistent symptoms were general apathy and headache. Examination of the eyes failed to disclose any lesion.

In spite of this negative history, the mastoid was opened. After chiselling through an exceptionally thick and hard cortex,

we found the anterior and middle cells and those of the extreme tip of the process choked with pus, but the antrum was empty. An anomalous course of the sinus led to its injury during the curetting, and a profuse hemorrhage followed. The cavity made by the operation was large and, owing to the excessive sinus hemorrhage, was firmly packed with iodoform gauze and was not disturbed for five days. The subsequent course was favorable.

That this case also was marked by less chronicity and an almost wholly latent course, and that the lesion of the cells was due to micro-organisms which had wandered or were forced by inflation into the deeper recesses of this region and there started an independent focus of activity, is almost certain. Equally so is it that the chief expression of the secondary lesion began in the outermost cells, for it was found that the posterior cells or those nearest to the mastoid antrum were not implicated at the time of the operation; furthermore, the uncommonly thick cortex accentuated the latency of the local symptoms if it did not wholly explain them.

(*To be continued.*)

PURULENT THROMBOSIS OF THE LATERAL SINUS. EPIDURAL ABSCESS. EXTENSIVE SUBPERIOSTEAL ABSCESS WITH ŒDEMA OF THE SCALP, FACE, AND NECK. OPERATION. RECOVERY.

By JOHN DUNN, M.D., Richmond, Va.

On May 20, 1898, I received a letter from Dr. Henry A. Wise, of Williamsburg, Va., asking me to operate on Mr. M., aged seventeen. He suspected serious disease of the mastoid region, although the process itself was not painful, nor was the skin over its surface swollen. He had had the case under observation for about ten days.

"History of scarlet fever; repeated attacks of right-side middle-ear inflammation, and deafness. Just before I saw him he had caught cold, which was followed by severe pain in his head, frontal and occipital, more severe, however, on the right side. *Scalp is very sensitive to the touch, especially over the occiput; there is also great pain in the neck.* Associated with these symptoms he has irregular chills, followed by high fevers, 103° and 104°; then will come profuse sweats; after which temperature sinks to normal. To-day considerable *œdema has taken place at the back of the head over the occiput.* No special pain over the mastoid. Occasionally the ear discharges some foul pus. He complains now of pains in his limbs. The general symptoms are those of sepsis. Patient has never been out of his mind." The main symptoms pointed clearly to purulent thrombosis. I reached Williamsburg late in the afternoon, and found Mr. M. weak and in great pain. There was general œdema of the whole scalp from the nape of the neck to the eyebrows; greatest in amount over the occipital regions and on the right side. This œdema was very marked also over both frontal eminences. No swelling of the eyelids. The neck was swollen in front and on the sides as far down as the collar bones, most marked on the right side. *The slightest pressure over any of the œdematous area, whether occi-*

put, sinciput, or neck, would cause the patient to scream with pain. There was no hypersensitiveness over the rest of the body. Patient's temperature was 101.5°. Examination of the fundi revealed some blurring of the outlines of the papillæ. The patient was so weak, and in such pain, that I could not make a prolonged examination of the eyes. Examination of the ear revealed an almost complete destruction of the drum membrane. In the external ear canal was considerable foul pus. No paralysis of the ocular muscles. The following morning at six o'clock the patient was seen again. The œdema had now spread downward over his face. His eyelids were so swollen that they could not be separated for more than ¼ inch. The skin over both cheek bones was œdematous. *There was no œdema of the ocular conjunctiva*, and it was this point that made me conclude that the œdema of the head and neck was due to cellulitis of the scalp, and not to very extensive intracranial thrombosis.

May 21st under chloroform the usual incision for opening the mastoid was made, and a posterior one from its upper end over the occipital region was added. The bone over the mastoid was found healthy. Operating to enter the antrum, foul-smelling pus was found at the depth of a quarter of an inch. The whole outer surface of the mastoid was then removed. The substance of the mastoid was found to have been transformed into a whitish pasty mass, very foul. While removing this the curette open edinto an epidural abscess posteriorly. On baring the sinus its anterior wall was found to be filled with holes. The lumen of the sinus was partially filled with fibrinous clots. These were spooned out downwards towards the bulb until a fairly free flow of blood was obtained. The same was done in the direction of the sinus backwards. The antrum was very large and communicated freely with the mastoid. The usual dressings were applied after the wound had been scraped and washed. Owing to the œdema of the neck no attempt was made to reach the internal jugular. The patient was left in Dr. Wise's care.

On May 24th, Dr. Wise writes that Mr. M. "is doing nicely; marked improvement in strength; nausea entirely stopped; highest temperature he has had was this morning,—100°; removed the dressings to-day; wound sweet and clean; free from pus; I saw some of the aristol in the antrum as dry as when it was dusted into it; no œdema of the conjunctiva yet; pulse excellent." On May 27th, Dr. Wise writes: "Yesterday I was suddenly called to see M. and found an immense discharge of pus through the old

wound. Pus was boiling out from between the scalp and bone; incisions made through the lower and back part of the scalp; amount of pus which came away almost beyond belief; washed out scalp with peroxide of hydrogen and bichloride. M. is now free from pain; temperature goes to 99° after each dressing; I think that all of the temperature he has had since the operation was due to the formation of this pus under the scalp." On May 29th: "Night before last M. had had a severe chill and must have had a very high temperature. When I saw him in the morning he was drenched with perspiration; temperature subnormal; last night he had fever, 103°, which went gradually down without much sweating; this morning, temperature 102.5°; dressed the wound, which continues sweet and clean; at six o'clock this evening he was very bright; had a good pulse; temperature normal; appetite good. These chills and fevers I think due to extension of the abscess under the scalp." The next day I saw Mr. M., who, with a temperature of 100°, was looking well. I found that there had been an extensive purulent inflammation of the loose tissues between the scalp and the bone, which had resulted in entirely separating the scalp from the bone for more than half of the extent of the surface of the skull. Dr. Wise had made through the scalp several large incisions at various intervals and passed gauze from one to the other for the purpose of drainage. The bone was everywhere bare, a probe showing that at no point over the posterior half of the skull was the scalp adherent to the bone. Peroxide of hydrogen thrown into an incision through the scalp at the upper limits of the separation came out about the occipital protuberance. *The patient had complete paralysis of the right external rectus.* When asked about it he said he had seen double ever since the swelling of his eyelids had gone down. The edges of the optic papillæ were still cloudy. In regard to the œdema of the scalp, Dr. Wise remarked that he had feared suppuration before the pus appeared at the wound, but as the œdema over the cheeks, eyelids, and forehead had gone down so nicely, he had hoped that over the occiput would do the same, and hence he had not made any early incisions. No change was made in Dr. Wise's treatment. The scalp was washed out once or twice daily, according to the amount of discharge obtained. On June 15th, Dr. Wise writes that "Mr. M. is getting on beautifully; the scalp has readhered over almost the entire surface; there is practically no discharge. The only apparent sequela is the paralysis of the external rectus, which persists." On July 30th, Dr. Wise writes:

"M.'s scalp is entirely well. There is some discharge from the external ear canal. This discharge comes from the centre of a small mass of granulations in the centre of the old wound. I can find no dead bone. His general condition is fine. He is as fat as a pig. The paralysis of the external rectus has disappeared."

The above case owes its interest to the extensive cellulitis complicating the inflammatory changes in the mastoid process and lateral sinus. The course of events was probably as follows: Purulent inflammation of the middle ear and mastoid antrum, then purulent mastoiditis, next epidural abscess, then thrombosis of the sinus. The swelling and œdema of the scalp, when first noticed, occupied the anterior part of the occipital region and was probably due to the transmission from within outwards of the infection through the small veins of the anterior end of the parieto-occipital suture, where it lies against the lateral sinus. Had the abscess beneath the scalp been the result of thrombosis of the mastoid vein, it would have affected the tissues of the neck rather than of the vault.

Temporary paralysis of the external rectus has been noted by Hessler among the symptoms of sinus thrombosis.

That perfect readhesion of the scalp, when once separated over so large an area as was here the case, may occur without interference with the nutrition of the skull bones is worthy of note.

Dr. H. Knapp in his article, "Otitic Brain Disease" (ARCHIVES OF OTOLOGY, vol. xxii., No. 2, 1893), mentions two cases similar to the above in that the source of the external swelling was an epidural abscess, secondary to purulent mastoiditis, and the immediate channels of infection were probably the small veins passing through the suture against which the abscess lay. One of these cases ended fatally, and the autopsy revealed a complicating cerebellar abscess; the other recovered after operation. Dr. Knapp adds by way of comment that "nature has many possibilities, but in the affection under consideration (extra-dural abscess) the fortunate outlet of extra-meningeal pus through a new aperture in the cranial bones appears far less frequent than the development of meningitis, thrombo-phlebitis, and brain abscess."

PURULENT MASTOIDITIS COMPLICATED BY EPIDURAL, SUBPETROUS, AND POST-ŒSOPHAGEAL ABSCESSES; DEATH PRESUMABLY FROM INTERNAL HEMORRHAGE.

By JOHN DUNN, M.D., Richmond, Va.

On June 15th there came to the clinic of the Richmond Eye, Ear and Throat Infirmary a negro man, aged thirty-eight, complaining of severe pain in his left ear and the region adjacent. One could see at a glance that he was suffering intensely. The trouble had lasted, he said, for five weeks, and he had taken "a hatful of them capsule pills" without relief. There had been at no time any discharge from the ear; owing, however, to some slight swelling over the region posterior to the external canal, the lumen of the canal was so constricted that only a very small portion of the drum membrane was visible, and the external canal itself could only be partially examined. It was, however, free from secretion. There was little, but noticeable, swelling over the body of the mastoid, more swelling about the tip, and partial facial paralysis of the left side. As the negro was unable to give any clear account of his symptoms, I referred the pain entirely to mastoiditis. He was accordingly operated upon. The usual skin incision was made, and a small amount of whitish pus was found as soon as the periosteum was entered. The whole of the mastoid process nearly to the tip was infiltrated with pus and granulations. Its entire outer surface was removed and the bone was curetted until I felt satisfied that no diseased tissue was left in the mastoid, unless possibly some little about the facial canal. No pus was obtained from the antrum. I concluded that the trouble had originated in the attic, spread thence to the antrum, thence to the mastoid cells, where the inflammation continued to spread, while the inflammation in the antrum had subsided.

That there had never been any discharge from the external canal suggested this to my mind.

On the day following the operation, the great pain from which the patient had suffered was gone. The patient did well for a week, complaining, however, of sleeplessness and *some stiffness in the left side of his neck.* The former I attributed to the fact that he had received no morphine since he entered the infirmary, while he had probably been generously treated to it for the five weeks before; the stiffness in the neck I concluded came from the fact that the insertion of the sterno-mastoid had been cut in getting to the tip of the mastoid. There was present some difficulty in opening the mouth wide. The patient was up and wished to go into the yard. There was, however, a look about his face which, while I could not interpret it, made me apprehensive that I had not found all of the trouble. On the tenth day he was so much better I promised to allow him to go home the following day. The next day, however, he was feeling badly, and in the afternoon had a high fever, temperature 104°, followed by great prostration. June 27th his temperature was 99.5° at 12 o'clock; 101.5° at 7 P.M. Patient passed a fairly comfortable night. The wound was clean and healing beautifully. On June 28th, morning temperature 98.5°, midday 99.5°, and afternoon 99.5°. Complained of nothing but some shooting pains in his head and stiffness in the neck. June 29th, temperature 99.5°, pulse 84. There now began to be present a swelling about the upper end of the sterno-mastoid. Thinking that the cause of the trouble was the formation of an abscess beneath the muscle, nothing was done until June 30th, when under chloroform an incision one inch and a half long was made along the posterior border of the sterno-mastoid muscle, the upper end of the incision corresponding to the tip of the mastoid, and the tissues dissected away until I had gotten beneath the deep fascia. No pus was found. The hard swelling disappeared under chloroform, showing, I thought, that the swelling had been due to spasm of the upper part of the muscle. The skin was now reflected from the post-mastoid region and the bone cut away toward the sinus, which was found at the distance of almost an inch behind the posterior wall of the external auditory canal. When the bone had been removed over the region where the lateral becomes the sigmoid sinus, an epidural abscess containing about a teaspoonful of thick greenish pus was opened. The abscess lay, as far as I could make out, between the sinus

and the inner table of the skull, following the lateral sinus along its course about one half of an inch, and the sigmoid for about the same distance. The abscess contained, besides the pus, a quantity of granulations, so that I could not tell at first whether they were or were not in the sinus. The bone having been removed over the whole of the abscess, its walls were curetted. When this had been done, the sinus wall appeared so healthy that it was not punctured. The abscess was then dusted with iodoform and packed with bichloride gauze.

Temperature, June 30th, evening, 98°; July 1st, morning, 98.5°; evening, 101°; July 2d, morning, 98.5°; evening, 101.5°.

Patient complains, as he had done for several days, of *great pain when he attempted to swallow; indeed, swallowing was practically impossible. When asked where the pain was, he would point to his larynx and say, "Behind that."* No examination of the postnasal space was possible, as the patient could separate his teeth only for a distance of ½ inch. Enough could be seen of the pharyngeal region, however, to say that there was no swelling of the tonsillar regions, or that of the soft palate, while so much of post-pharyngeal wall as was visible was normal in color. Patient still has an unhealthy, anxious look. Fundus of each eye normal. Wound dressed and found to be clean. Injection of morphine given. Patient slept well. No thrombosis of the jugular.

Temperature, July 3d, morning, 98.5°; midday, 98.5°; evening, 101°; July 4th, midday, 98.8°; evening, 101.5°.

Patient complains of *great pain when he swallows, and refers seat of pain to region back of larynx*; cannot open his mouth yet. Examination of the external canal shows its lumen still too small and upper wall extremely sensitive to the slightest pressure. The lumen of the canal did not allow me to make out anything suggesting an abscess in the upper wall, yet I was at a loss to account for the undue sensitiveness of this region to the touch of a probe. Patient volunteered the information that the night before he had drawn from his "nose" into his throat a lot of "matter that tasted mighty bitter." This suggested the possibility of pus in the middle ear, escaping through, or about, the walls of the Eustachian tube, but no postnasal examination could be made, because, as above stated, of the impossibility of the patient's opening his mouth. Patient has every afternoon a rise of temperature and increase of pain, but says he has had no chill at any time since the last operation. July 5th, temperature, morning, 98.5°; 2 P.M., 99.5°.

Operation.—Region of wound examined under chloroform and found to be clean. A few granulations were found between the tables of the bone in the upper part of the wound. Antrum contained only a few granulations; no pus. While probing into the external canal and separating the covering from the bone in the upper posterior angle, the probe went into an abscess from which escaped a considerable amount of pus. It was clear now that pus had escaped from the attic under the skin covering the external canal, and had then disseminated itself. It is to be noted, however, that no pus was found in the antrum. Whether its walls were furnishing pus which drained away into the middle ear, I am unable to say. No fistula leading from the antrum to the dura could be found.

While under chloroform the patient coughed up a considerable amount of pus.

Temperature, July 5th, 7 P.M., 102.5°; July 6th, 1.30 P.M., 101.5°; 5 P.M., 103.7°.

Patient complains of no especial pain anywhere. Says he has now almost no pain in the throat. Condition is, however, visibly unfavorable. When asked if he ever had any pain in his chest, he said none at all. His wife, who acted as his nurse, said that he had expectorated quite freely for some time past, and now and then coughed. She had made no mention of this, as she had thought it connected with the pain in the throat. As the patient had never coughed while I was in the room, I had not had my attention drawn to the possibility of a lung complication. Examination of the chest revealed *extensive pleurisy*, with effusion over the right lower lobe. Some of this effusion was drawn off. Inquiry into the patient's family history revealed the fact that many of his immediate relatives had died of consumption. Treatment for the pleurisy begun.

Temperature, 8 P.M., 101°; July 7th, 9 A.M., 98.5°; 1 P.M., 99°; 7 P.M., 102°.

Wound dressed; found clean and sweet. Patient no longer has any pain in his head or neck, but suffers greatly when any attempt is made to turn his head, or lift it.

Temperature, July 8th, morning, 101°; midday, 100°; evening, 101.5°; July 9th, 99.4°; July 10th, 99°; 3 P.M., 101.5°; 9 P.M., 102°.

Patient's lungs examined. Greater part of the effusion has been absorbed. *Patient, however, has difficulty in swallowing and*

great pain when neck is moved. Swelling under sterno-mastoid has increased; it is, however, not painful on manipulation. Old wound in neck reopened and deep tissues of the neck probed. Could find no abscess. Patient still complains of sleeplessness. Cannot open mouth freely. Expectorates considerably. Dressings in mastoid very wet with pus. Some return of the facial paralysis.

July 11th.—Temperature, morning, 98.5°; evening, 102°. Much discharge on the mastoid dressings.

July 12th.—Temperature, morning, 98.5°; 2 P.M., 101°.

Under chloroform an incision was made through the skin from lower end of the incision for opening mastoid, downwards and forwards, for two inches. *In my endeavor to locate the abscess, firm pressure was made on the swelling in the neck, following which a great quantity of pus was seen to flow from the mastoid antrum.* For a moment I failed to connect the pressure with the flow of pus from the antrum. I was, however, considerably surprised at it, inasmuch as there had been no discharge from the antrum when it was opened a few days previously. Yet I had noticed that since the antrum had been opened, the dressings were unduly wet and purulent. I continued the pressure upon the swelling in the neck, and soon found that the flow in the antrum could be made to cease entirely or to increase very much by lessening or increasing this pressure. The abscess now located was easily reached by cutting away with a small dental pick the tissues medial to the remains of the mastoid tip. The abscess proved to be a large one, and was situated below the inferior face of the petrous portion, around the styloid process and foramen. A large opening having been made in the abscess, and its pockets drained, it was loosely packed with gauze. Evening temperature, 102°.

July 13th.—Morning temperature, 99°; 2 P.M., 103°. Dressings removed; wound and abscess cavity full of greenish pus. Washed out with bichloride. 8 P.M., temperature, 101°.

July 14th.—Morning temperature, 98.5°; pulse, 84; 2 P.M., temperature, 98.5°; pulse, 80. Swelling in neck much reduced. General condition of patient better. 8 P.M., temperature, 98.5°.

July 15th.—Morning temperature, 98.5°; 2 P.M, 99.5°; evening, 100°; neck much diminished in size. Much pus in the abscess.

July 16th.—Morning temperature, 98.5°; midday, 99.5°; evening, 99.5°.

July 17th.—Morning temperature, 98.5°; midday, 99°.

Patient's general condition greatly improved. Considerable pus still coming from neck.

July 18th.—Morning temperature, 98.5°.

Owing to absence from the city from this date until July 28th, I did not again see the patient. The physician in charge reported a large amount of discharge, with considerable evening temperature. No chills. On the night of July 28th, abscess in the neck burst into the œsophagus, and during the night much pus was expectorated. On July 29th examination showed considerable swelling under the upper end of sterno-cleido-mastoid, while the whole side of neck, nearly down to the clavicle, was boggy under deeper pressure. A deep incision was made into the side of the neck, about three fourths of an inch behind the posterior border of the sterno-cleido-mastoid, and about one and a half inches below tip of the mastoid. A large abscess cavity was found communicating with the upper old cavity. The probe revealed extensive baring of the bone on the under surface of the petrous bone. Drainage, peroxide of hydrogen and bichloride.

August 11th.—The discharge has greatly diminished; the patient's general condition seemed good; he did not, however, regain his strength. He still complained of stiffness when he attempted to lift his head, or move it from side to side. He has had two or three passages from the bowels containing blood. (This I attributed to some turpentine he had been taking.)

From now until August 16th I was again away from the city. On my return I learned from his wife that on August 12th patient had complained of being very cold; had had during the evening a passage containing much clotted blood; and, during the night, had grown weaker and weaker. He *died* the following morning; *no autopsy.*

The above history is not without interest. The mistake made was in not recognizing at first that I had to do with a case of Bezold's mastoiditis and in not finding sooner the abscess beneath the petrous bone; the pus thus accumulated and became so generally disseminated in the tissues of the neck. The failure to find pus by the first incision made through the tissues posterior to the sterno-cleido-mastoid was due to the fact that the part entered was too low; the disappearance of the swelling under chloroform made me

suspect it had been due to contraction of the muscle. There was at no time any evidence of thrombosis of the internal jugular. The finding of the epidural abscess was the result of my failure to locate the subpetrous pus. It is very likely that the intracranial abscess would have been allowed to become very much larger, had the abscess in the neck been found when first sought for, inasmuch as the size and depth of the latter would have drawn my attention for a while from the possibility of another abscess elsewhere. In reviewing the case I think it highly probable that there was still another abscess present, one posterior to the œsophagus, and that this abscess did not open into the one under the petrous bone; for not once while I was washing out the latter did the patient ever complain that either the peroxide or the bichloride solution went into the œsophagus. On more than one occasion, while pressing the pus out of the tissues in the neck, the patient asked to spit, but there was no evidence of the sputum containing peroxide of hydrogen. It was this unfound abscess which, until it burst while the patient was under chloroform, caused him to refer his sensations of pain and discomfort to the region directly back of the larynx, and which made swallowing for several days either altogether impossible, or accomplished only with the greatest difficulty. The direct cause of the patient's death was, I believe, hemorrhage, probably the rupture of a vein into this post-œsophageal abscess. No blood ever escaped from the subpetrous abscess or was brought away in the dressings—another reason for believing that there were two distinct cervical abscesses. Again, the accumulations of pus, which took place between the times of the dressings, caused no difficulty in swallowing after the rupture of the abscess into the œsophagus. The bloody stools which I was willing to attribute to the turpentine must, I now believe, be explained by the rupture of a vein into the post-œsophageal abscess. This rupture may have been at first a small one, which was increased the day of the patient's death. After opening and curetting the epidural abscess, there were never present any symptoms of any kind that might be referred to the brain or its membranes.

After the appearance of the bloody stools, the patient complained of severe "aching in his eyes." There were, however, no signs of eye trouble. It is to be regretted that no autopsy was obtained.

Cases of Bezold's mastoiditis have been several times operated on with success; a very instructive case, operated on in the early stages, before the formation of an abscess in the digastric fossa, is given by Dr. H. Knapp in his article on "Otitic Brain Disease" (ARCHIVES OF OTOLOGY, vol. xxii., No. 2, 1893).

A CONTRIBUTION TO THE CLINICAL STAGES AND TO THE TECHNIQUE OF THE OPERATION FOR SINUS THROMBOSIS.

Read before the Section of Ophthalmology and Otology at the N. Y. Academy of Medicine, Nov. 21, 1898.

By FRED. WHITING, M.D.,

AURAL SURGEON TO THE NEW YORK EYE AND EAR INFIRMARY.

THE recent remarkable progress in the successful treatment of intra-cranial infective diseases, which were formerly regarded as inoperable, constitutes a flattering tribute to the value of antisepsis, and to the diagnostic and technical skill of the modern surgeon. It is well-nigh impossible to conceive of a surgical procedure more gratifying in its results than that attendant upon the complete restoration to vigorous health of a man in the plenitude of his powers, who has fallen a prey to intra-cranial extension of infective otitic disease, an affection which may now be regarded as a conquered province wrested from the rapidly narrowing domains of necessary fatality and annexed to the ever-widening territories of successful surgery.

Such successes have ceased to startle the medical world, although by no means so frequent as we anticipate for the future, and from the attitude in which with hesitating credulity the profession accepted the reports of the first few recoveries, we are rapidly advancing to the critical period in which we demand to know why such recoveries are not more frequent. In other words, we now wonder, not that any should survive, but that so many should die. It is this inquisitive faculty which inaugurates all investigation, scientific or otherwise, and by the exercise of which our powers of observation and deduction are measurably heightened.

A careful review of the reported cases of thrombosis of the lateral and sigmoid sinuses, certain features of which affection we propose to consider in this paper, will infallibly lead to the conclusion that when the disease has been recognized early in its course, before purulent disintegration has supervened in the thrombus, the prognosis under skilful and experienced handling has been almost uniformly good. The mere presence of a *non-infective clot* in the sinus does not constitute a direct menace to life. Such clots do undoubtedly form from wounds inflicted upon the vessel during operations in its immediate vicinity and occasion no subsequent disturbance. An *infected thrombus in the first stage* is amenable to almost certainly successful operation. At a more advanced stage, when pyæmic manifestations are present, but before the appearance of metastases, there is still an excellent chance for the patient, and even under the most adverse conditions where the purulent phlebitis has extended into the jugular and metastatic abscesses are present, a small proportion recover after very extensive operation involving resection of the jugular vein. There is recorded one case in which not only was the jugular involved and metastases were present, but septic pneumonia existed as well; still operation was performed and recovery ensued. In view of such evidence, the symptoms presented by any case which shall characterize it as absolutely hopeless will be exhibited only when the patient is *in articulo mortis.* It being fully established that in skilful hands a very high percentage of the mildest cases recover, and of the most hopeless cases a small percentage survive, it would seem that means ought to be forthcoming by the employment of which the rate of mortality in such cases as lie between these two extremes could be appreciably reduced. Such remedy is to be found only in a more comprehensive acquaintance with the symptomatology of the disease which will result in early and accurate diagnosis.

The relative infrequency with which such conditions were diagnosticated but a few years ago contributed to the belief that the lesion was exceedingly rare, but with radical improvements in surgical methods during the last five years,

the total number of successful and unsuccessful cases reported makes a very respectable aggregate which the unpublished failures, could they be recorded, would appreciably augment. This element of unpublished operative failures bears an important relation to the percentage of favorable prognosis, and it is undoubtedly true, not only that all mention of many cases which are recognized and operated upon too late and, therefore, unsuccessfully, is suppressed, but also that numbers of patients die with this disease entirely unsuspected, death being attributed to "obscure head troubles," typhoid fever, and the like. Hence it follows that when we rely upon the statistics of published cases for our estimate of the prognosis of sinus thrombosis, we are taking an unwarrantably optimistic view of this fatal malady, the published reports of which are distinctly misleading, and in no sense accurately represent the rate of mortality. It is my belief that the percentage of mortality in sinus thrombosis is materially higher than the rate commonly attributed to it, for the reason that the temptation to suppress operative failures is of similar import and equal weight with the inducements to publish operative successes. The two factors chiefly concerned, not only in diminishing statistical mortality, but in increasing the number of actual recoveries as well, will be, first, earlier recognition and more intelligent interpretation of symptoms significant of this affection; and, second, improved technique in the performance of the needful operative steps.

It is with the desire of emphasizing the first, and elaborating the second, that this article is contributed.

How then may we accomplish the first of these requisites, namely, the earliest possible establishment of the diagnosis? The prime essential is to firmly impress upon the mind of the general practitioner, under whose supervision these cases, as a rule, first come, the fact that nearly all inflammatory diseases of the brain and its coverings are infective in their nature, and that of such diseases of the brain the majority are otitic in origin. Hence the routine initial step in the examination of all patients exhibiting symptoms of inflammatory intra-cranial affections should be, save in the pres-

ence of other causes absolutely confirmatory, a physical examination of the ear.

How much of an examination is to be made, and who is to make it, are questions which the exigencies of individual cases must often decide. The examination should, of course, be as thorough as possible, and the best procurable skill under all circumstances employed, but under conditions which render the attendance of specially qualified experts impracticable, how much can be legitimately demanded of a busy doctor? This question has been often discussed, and the general practitioner frequently and soundly berated for his shortcomings, but for the most part it must be regretfully admitted to little purpose. A patient can reasonably demand of his doctor that he shall be able to inspect the ear drum, and recognize the presence of a discharge which is not sufficiently profuse to fill the auditory canal and pour from the meatus. Hitherto, attending physicians have flattered themselves upon their attention to diagnostic minutiæ if they have recognized an otorrhœa which was discharging from the meatus, and have regarded as entirely superfluous detail any attempt at more searching investigation. Such superficial inspection will no longer pass muster as a physical examination of the ear, and no physician has any right, with the facilities at hand to-day, to repose supinely in any such attitude of false security. The dangers to be apprehended from a scanty discharge which is noticeable only upon careful scrutiny of the fundus of the canal may be far greater than a more profuse flow which escapes freely from the meatus; for while either is fully competent to originate the infective intra-cranial process, its initiation is more frequently traceable to the revival of latent septic processes which are unaccompanied by any excessive secretion rather than to more acute inflammatory manifestations characterized by copious and offensive discharges, hence the increased liability that a mere perfunctory examination will entirely overlook or misinterpret the source of the difficulty.

It is not within the scope of this paper to dwell upon the bacteriological nature of the infection in sinus thrombosis, and we dismiss the subject with the statement that it is of a

mixed type, the streptococci and the staphylococci predominating, and in proportion as the first mentioned micro-organisms are in excess in such degree is the virulence of the inflammation intensified; the path of infection and method of dissemination as well, are without the field of the evening's discussion, and will be but casually commented upon; nor is it intended to elaborate the symptomatology of the disease beyond the consideration necessary to an intelligent presentation of the essential features of its three clinical stages.

To those desirous of pursuing exhaustive studies of these phases of sinus phlebitis, we commend Macewen's fascinating work, *Pyogenic Diseases of the Brain and Spinal Cord*, or Hessler's statistical encyclopædia, *Die Otogene Pyamie*, which masterly treatises leave little to be desired.

The present contribution is concerned with:

FIRST: *The clinical stages of sinus thrombosis.*

SECOND: *The technique of the operation for the relief of the same.*

The course of sigmoid sinus thrombosis may be conveniently designated for purposes of clinical classification as comprising three stages, characterized by local and systemic manifestations; the anatomical appearances of the sinus wall, the pathological changes in the clot, and the signs of circulatory obstruction may be denominated as LOCAL FACTORS; while rapid and excessive fluctuations of temperature, frequently repeated rigors, peripheral or central metastases, etc., embrace the essential SYSTEMIC SYMPTOMS.

The local and systemic conditions enumerated below constitute the various stages.

FIRST STAGE: *The presence of a thrombus, parietal or complete (chiefly composed of fibrin, red blood cells, exfoliated endothelium, leucocytes, and homogeneous protoplasmic cells), not having undergone disintegration and accompanied by slight or moderate pyrexia, rigors being usually insignificant or absent.*

SECOND STAGE: *The presence of a thrombus, parietal or complete, which has undergone disintegration with resulting systemic absorption, characterized by frequent rigors and pronounced septico-pyæmic fluctuations of temperature.*

THIRD STAGE: *The presence of a thrombus, parietal or complete, which has undergone disintegration with systemic absorption, accompanied by rigors, rapid and great fluctuations of temperature, and central or peripheral embolic metastases, terminating usually in septic pneumonia, enteritis, or meningitis.*

FIRST STAGE: The diagnosis of sinus thrombosis in the first stage is seldom made preliminary to the operation for mastoiditis, owing to the indeterminate character of the symptoms manifested up to that point in the progress of the affection; its detection follows, as a rule, the recognition by the operator of extension of the carious disease through the inner table along the course of the sigmoid groove, or at some point in the immediate vicinity, although there may be, as yet, no perceptible solution in the integrity of the wall, or, on the other hand, there may already be a well defined opening into the posterior cranial fossa, through which granulations from the eroded dura protrude into the pneumatic spaces of the mastoid; the removal of such granulations with adjoining carious structures uncovers the parietal wall of the sigmoid sinus, and reveals the often entirely unsuspected existence of a thrombus, the patient having exhibited no symptoms in any wise significant of sinus implication. It thus follows that the diagnosis of sinus thrombosis, *in the first stage, is, with rare exceptions, consequent upon operation for mastoiditis.*

In this stage, recovery is still possible, although improbable, without operation upon the sinus, the infective process occasionally resulting in a constructive inflammation terminating in cicatricial obliteration of the sinus lumen, a conclusion fervently to be desired but very seldom realized. The anticipation of such a favorable outcome is only to be entertained under most exceptional circumstances, namely, when the virulence of the infection is so far attenuated as to have nearly expended its energies during the invasion of the vessel walls and in the production of the resulting clot, and when the *residual activity* of the pathogenic organisms present in the thrombus is speedily destroyed by the germicidal action of the phagocytes and leucocytes. Under no circumstances can such thrombi be regarded as non-infective;

that the extension to the sinus of an infective inflammation and the introduction into it of infective germs should produce a non-infective clot would be an anomalous state of affairs. That, however, the infection may be sufficiently attenuated, after producing the thrombus, to fail of causing disintegration of the same, in view of the action of the phagocytes and leucocytes, can be readily comprehended.

The subsequent steps in the course of cicatrization are precisely such as are characteristic of effused blood elsewhere about the tissues of the body, and are in no sense distinctive of thrombotic conditions.

The position of those who, with Hessler, maintain that sinus thrombosis in the first stage should be left to the benign care of nature, cannot be successfully defended, for it is a practical impossibility, although, perhaps, theoretically feasible, to assure one's self that the thrombus is not teeming with pyogenic germs which will cause the speedy disintegration of the clot, and contribute easily absorbable matter for distribution to the lungs or other organs; as we know only too well this is precisely what happens in the majority of cases, the transitional period which ushers in the second stage being thus initiated.

If Hessler's advice is followed, the thrombus, being fully located, is not to be removed, but aspiratory puncture is to be performed in several points daily, and any material thus withdrawn submitted to the microscope for investigation of its septic properties. It seems but reasonable to conclude that in a clot of any size numerous small septic foci might exist which the needle would fail to encounter, and, therefore, detect, while the repetition of daily punctures would serve as a dangerous source of secondary infection.

The only safeguard against encountering the increased gravity of the second stage is to operate immediately upon the recognition of the first stage, and the prognosis under such conditions in skilful hands, and in the absence of any complicating chronic disease of the patient, is exceedingly favorable, while the dangers attendant upon sinus thrombosis in the second stage are multiplied both as regards the likelihood of general systemic infection and the operative risks as well.

The transitional period between these two stages is usually brief, and its completion is commonly heralded by a sharp rigor.

THE SECOND STAGE: *The presence of a thrombus, parietal or complete, which has undergone disintegration with resulting systemic absorption characterized by* FREQUENT RIGORS AND PRONOUNCED SEPTICO-PYÆMIC FLUCTUATIONS OF TEMPERATURE.

The diagnosis of sinus thrombosis is usually dependent upon the appearance of symptoms which are not clearly manifested until the second stage of the disease is encountered, when, if the course pursued by the affection is at all typical, there musters in imposing array a sequence of symptoms which are quite irreconcilable, when associated with a suppurative inflammation of the ear, with any ailment other than infective involvement of the sinus. For this reason it happens that the diagnosis is made and surgical aid invoked in the majority of instances, if the medical attendant be alert, in this second stage; the earlier the recognition, the more favorable, of course, being the prognosis. But, in the event of the physician in charge misinterpreting these signs, or, as sometimes happens, the patient, although wisely advised, declining to accede to operation, notwithstanding the urgency of the demand for such interference, the characteristic manifestations of the third stage, with almost certain fatality, may confront the operator and confound his skill before the patient or his lay advisers can be forced to comprehend the exigencies of the case; but when also the ignorance of the doctor abets the stupidity of the relatives, the lot of the unfortunate victim is sorry indeed. The general or systemic symptoms of sinus thrombosis in the second stage are essentially those of septico-pyæmia, and the manifestations are the results of the dissemination through the blood and lymph channels of pathogenic micro-organisms liberated for distribution by disintegration of the thrombus.

With the beginning of the second stage a train of symptoms of increasing gravity manifest themselves in rapid succession. The features of the patient assume a distressed and anxious look with an ashen pallor, the countenance is

frequently suffused with copious, colliquative perspiration, the exhaustive sweating being a significant accompaniment of this stage; there is loss of appetite and constipation, respiration becomes shallow and increased in frequency, *the fluctuations in temperature* are rapid and excessive, associated with *repeated* and *severe rigors*. The marked pyrexia is subject to frequent remissions, and the amplitude of the exacerbation is at times very great, although the febrile period may be exceedingly brief, two hours sufficing in certain instances for a variation of 6° F. This *very high temperature* is significant of the degree of toxæmia present in the case, and is a valuable guide to, or one might say warning of, the septic complications to be anticipated. With such fever there could be prophesied, with almost absolute certainty of fulfilment, multiple metastases and a succession of unfavorable developments. Of 95 cases of metastatic sinus thrombosis recorded by Hessler, but 12 exhibited temperatures of 106° F., and of 26 cases which were *free from metastases*, not one approached this degree. Important clinical deductions may with reason be made from such a statistical array, which begets in the operator confidence, and enables him to offer his prognosis with less hesitation and greater intelligence.

Equally important inferentially is the appearance of *rigors*, which constitute a prominent feature in the first and second stages of sinus thrombosis. They occur early, are frequently repeated, and as the toxæmia increases may even become daily manifestations, accompanied by profuse perspiration. While it is true that chills are the most constant symptom of the onset of infective phlebitis, it is also true that they may be entirely wanting, and 16 such cases are recorded; also 40 in which but a single chill was experienced. Repeated chills may, however, in $\frac{4}{5}$ of the cases be anticipated, and further investigation shows that the metastatic processes in those instances in which the rigor was not repeated were numerically small, with feeble septic powers. On the other hand, when the chills were frequent and prolonged the subsequent sweating was pronounced and debilitating and the associated septic processes proportion-

ately virulent. Allen has reported a case in which with repeated chills there was no sweating until during the few hours immediately preceding death. Such exceptions to the usual rule in the sequence of symptoms serve chiefly to emphasize their fallibility for purposes of diagnosis.

Vertigo is present in a moderate proportion of cases which are uncomplicated, and, like *vomiting*, is more constant when associated with meningitis. Forselles found it present in simple sinus phlebitis with meningitis, in 30 per cent. As a symptom of sinus thrombosis, it is by no means a distinguishing characteristic, and the importance attributed to it should not be over-estimated. As an accompaniment of acute infective conditions, it makes its appearance suddenly, and is apt to diminish as the disease progresses, and then to recur with later unfavorable manifestations; at some times present only on assuming the erect posture, at others asserting itself even during recumbency.

The *pulse* and *respiration* in the first week show moderate acceleration, becoming exaggerated with the passage of time and increasing toxæmia, until in fatal cases of pyæmic thrombosis the pulse rate mounts to 180, or becomes so rapid and feeble as to defy computation, the breathing being also embarrassed, and respirations occurring as frequently as 40 per minute.

Just the reverse of this occurred in a recent case of mine where there was a pronounced alteration in the respiratory rhythm, corresponding to no known variety and exhibiting a peculiar spasmodic hitch or jerk on inspiration which was free from pain; the frequency of respiration was also diminished. These symptoms were apparently occasioned by pressure upon the pons of the two greatly distended occipital sinuses.

Consciousness: There is no symptom of sinus thrombosis more subject to variation than consciousness, which in very many cases, particularly if uncomplicated with meningitis, remains unimpaired up to the moment of death. Again, there may be speedy loss of it associated with wild delirium, or the patient may lapse into a somnolent condition, capable of being roused and interrogated with the result of

eliciting monosyllabic replies; this state usually precedes coma. Loss of consciousness has been observed in 30 per cent. of uncomplicated cases, and in 50 per cent. of cases complicated with meningitis and brain abscess. In 23 cases recorded by Hessler, in which the sinus phlebitis was complicated with meningitis and brain abscess, there was not a single instance of preservation of consciousness throughout the entire course of attack.

A mild form of delirium does not necessarily imply greatly increased gravity in the case and may be due to a minute non-infective cerebral embolus, but if prolonged with occasional periods of violence the prognosis is distinctly bad, for coma supervenes, and speedy dissolution ensues. Symptoms analogous to typhoid may appear in this stage if abdominal manifestations become prominent, and are often responsible for fatal errors of diagnosis.

Septic pneumonia and enteritis with albuminuria and affections of the pericardium and pleura, while occasionally encountered in this stage of the disease, are more often absent, and when they appear are usually to be regarded as manifestations of a rapidly approaching and unfavorable termination.

Simultaneous with these manifestations appear what may be denominated *local signs of circulatory embarrassment* or obstruction, which, with further progress of the affection, become oftentimes very pronounced.

The symptoms originate in engorgemant of the veins tributary to the sinuses of the duramater, or through extension of infective inflammation into neighboring tissues, resulting in phlebitis, or by reason of pressure from the sinus walls distended with clot, or as a result of parietal accumulations pressing upon contiguous nerves. Among the earliest and most constant of these may be mentioned *hemicrania*, occasionally mild in character, and again of unendurable severity, usually radiating from the ear over the corresponding side of the head; this sign is, of course, in no sense a distinctive factor, but it is mentioned first as being the only symptom invariably present. *Tenderness in the upper portion of the posterior cervical triangle* has been a

prominent and easily elicited symptom in every case which has thus far come under my observation, and appears a most valuable aid to diagnosis. It is dependent upon phlebitis of the deep veins of the neck. The anterior and posterior condylar participating with considerable frequency in inflammatory extension from the sinus, *œdema* of this locality appears in conjunction with tenderness, but as a much less constant manifestation; however, when plainly marked, its significance is unequivocal of obstruction in a great blood-channel, and it usually implies that the thrombus has already extended into the jugular bulb, and that infective dissemination has begun.

The so-called *Griesinger's* symptom may be described as œdema of the occipital region, extending downward and implicating the nape of the neck; it is dependent upon phlebitis and obstruction of the mastoid and occipital veins, and should not be confounded with œdema of the mastoid region, so commonly encountered in uncomplicated empyema of the process. In connection with this symptom may be mentioned the fact that Bennet has laid stress upon the diagnostic value of a *distinct point of tenderness* over the site of the foramen of exit of the *mastoid emissary vein* upon slight pressure, when the same pressure applied to the mastoid process over its centre does not occasion similar pain. No great reliance is to be placed upon this observation, for in the personal experience of the writer of this paper this identical point of tenderness has been frequently noted and interpreted to signify the presence of an extradural collection of pus in the cerebellar fossa, usually but not always perisinuous, and my own histories show that in ten such cases the diagnosis was correct, while in only two cases of sinus thrombosis out of ten which I have had opportunity to more or less closely observe could this manifestation be recognized, and then only as corroborative of other much more weighty evidence.

The mastoid foramen has at times served as an avenue of exit for the purulent contents of the lateral sinus, and three such cases are reported by Orne Green, in which there was very extensive infiltration of the whole of that side of the

neck, all the tissues containing pus. Küpper reports a precisely similar case, also with fatal termination. These examples are cited not as being symptomatic, but as an eloquent protest against delayed operation.

A symptom first appreciated by Gerhardt, and described by him, but which, according to Hessler, lacks confirmation, is elicited by laying the finger with sufficient force across the course of the external jugular of the affected side to cause obstructive pressure, when it will be noted that the vessel either exhibits but slight turgescence or none at all, while upon the healthy side the external jugular, although not unduly prominent, becomes, upon the application of similar pressure, engorged to a pronounced degree. A beautiful demonstration of this symptom was furnished by one case of the author's published in Knapp's ARCHIVES OF OTOLOGY, vol. xxvii., No. 1, 1898, in which the phlebitis of the second stage had already involved the internal jugular vein. Nothing more decidedly confirmatory of Gerhardt's observations could be demanded to carry conviction to the most skeptical. Corroborative of this was a later experience with this same case of mine: Several weeks after the diminished flow through the external jugular had been observed and recorded, an abscess formed in the sterno-cleido-mastoid muscle, in opening which it became necessary to carry the incision directly across the course of the vein, which vessel was divided. The cut ends of the vein thus exposed were greatly thickened, appearing to have the firm, tense walls of a large artery, and gaping widely instead of collapsing, as is usual with a vein. There was no clot to be seen in the lumen, but notwithstanding this fact no blood escaped from either end of the divided vessel.

Another manifestation which has recently been remarked with varying degrees of frequency by Stirling in his paper,[1] is a moderate œdema or puffiness of the eyelids of the corresponding side, as a result of interference with the cavernous sinus and engorgement of the ophthalmic vein. Associated with this symptom, intra-ocular inflammatory changes are observed in a considerable number of cases,

[1] *Canada Med. Record*, Nov., 1896.

usually taking the form of neuro-retinitis, and in a few instances where there has been extension of a *non-infective* clot into the cavernous sinus, certain muscular palsies have been noted as a result of pressure.

Kipp[1] found only 4 cases of optic neuritis among over 50 patients examined in the course of chronic suppurative otitis media: of these 2 (or 50 per cent.) died, while of the supposed cases of intra-cranial extension in this list, all those which were without intra-ocular inflammation recovered. Kipp further states[2] that he cannot remember to have seen *optic neuritis* in any case of uncomplicated sinus thrombosis. In this respect his experience differs radically from that of Pitt,[3] who reports 4 such cases, and of Jansen,[4] who reports 9 cases of choked disk, 1 of optic neuritis, and 4 of hyperæmia, in all 14 out of 28 cases of sinus thrombosis. In my own brief experience I have encountered 2 cases of uncomplicated sinus thrombosis terminating in recovery, after operation in the second stage, in both of which was well marked optic neuritis; and in a case which I saw in consultation with Dr. Knapp last summer, the same manifestation appeared, which waxed and waned in direct proportion to the severity of the infective intra-cranial process; the symptom is doubtless often absent, but with equal certainty is frequently present; in any event, an examination of the fundus oculi should never be neglected.

Percussion: Okukeff[5] claims the ability to recognize the presence of a thrombus in the lateral sinus by dulness on percussion of the affected side as compared with the clear tone of the corresponding area of the opposite side. This physical sign must require much skill in its performance and a specially appreciative ear for its recognition, the ordinary observer not being qualified for such refinement of differentiation in high-pitched sounds. With the phonendoscope we may hope, with practice, to distinguish an altera-

---

[1] *Zeitschrift für Ohren.*, vol. viii., p. 275.
[2] *Zeitschrift für Ohren.*, vol. xv., p. 250.
[3] *Brit. Med. Jour.*, March 22, 1890.
[4] *Arch. für Ohren.*, vol. xxxvi., p. 7.
[5] *Arch. für Ohren.*, vol. xxxviii., pp. 169, 175.

tion in the percussion note, but even this instrument, with its exaggeration of sound, has, in my hands at least, probably from lack of experience, failed to substantiate the claims made for its efficiency.

A symptom which manifests itself late in the second, or which may initiate the third stage of sinus thrombosis, is tenderness along the course of the internal jugular in the neck, with perhaps an appreciable cord-like feeling to the infected vein. Such a symptom would, of course, in conjunction with those already enumerated, be regarded as absolutely pathognomonic of a thrombotic condition of the sinus, with jugular extension.

Any of the above-enumerated signs may, in a given instance, be absent; even those reliable indices, fluctuations of temperature and rigors, do not materialize with infallible regularity. A recent case of mine, not as yet reported, had no chill, and his temperature during each of the days preceding the operation ranged, for twenty-four hours, between 99.5° and 101° F., with neither sudden elevation nor decline; after, however, making due allowance for the vagaries of the disease, the second stage should not have progressed very far before its recognition by the surgeon, if he is familiar with the symptomatology and a reasonably acute diagnostician.

When in the second stage of sinus thrombosis a fatal termination ensues, the usually assignable causes will be, in the order of their relative frequency, meningitis, pneumonia, enteritis, brain abscess, general sepsis, collapse and operative shock. Other complications may supervene, but, as a rule, are deferred until, and are characteristic of, the third stage of the malady.

THIRD STAGE: The presence of a thrombus, parietal or complete, which has undergone disintegration with systemic absorption, accompanied by rigors, rapid and great fluctuations of temperature, and CENTRAL OR PERIPHERAL EMBOLIC METASTASES; terminating usually in septic pneumonia or enteritis. With the appearance of the distinctive features of this stage of sinus thrombosis, namely, the central or *peripheral metastases*, *septic pneumonia*, etc., the hopes of

successfully combating the disease rapidly diminish, although so remarkable are the reported cures in this affection consequent upon operations undertaken as a last resort that all hope must not be abandoned until the patient is in extremis.

The diagnosis at this critical period is to the practised observer distressingly clear, and a fatal termination is, save as the result of favorable operation, seldom long delayed.

The array of symptoms which appears so formidable in the second stage is now augmented by additional signs of most dire portent: these are the direct result of the dissemination of septic emboli; or in other words, the new manifestations are due to the distribution of infective material *in larger or smaller masses*, while the characteristic phenomena of the preceding period are attributable to absorption through the capillaries of pathogenic micro-organisms or of infinitesimal fragments of *septic products* calculated to induce general septico-pyæmia, but inadequate, from lack of volume and virulence, to establish new local infective centres; but with the arrest, in their excursion through the circulation, of pyogenic masses is instituted a violent and destructive attack against which no structures of the body enjoy immunity and no tissue of any organ or member of the body can offer more than feeble and ineffective resistance; thus there originate the distinctive features of the third stage of sinus thrombosis or of otogenic pyæmia, namely, embolic metastases. Should the convalescence from this stage be protracted, or the unavoidable fatality be delayed, there may appear a series of abscesses, distributed over the trunk and extremities, as well as the thoracic and abdominal viscera, with the most indiscriminate impartiality. The rapidity with which cellular tissues undergo extensive destruction under the baneful influence of the infective elements thus deposited is astonishing, and can be accounted for only upon the basis of diminished vital force incident to general infection, and the reduced activity of the phagocytes and leucocytes. Embolic metastases may appear immediately after disintegration has taken place in a small portion of the clot, or they may not manifest themselves until complete puru-

lent liquefaction has supervened. They sometimes obtain entrance to the circulation through the small tributary veins in the immediate vicinity, and again are admitted through that more direct and dangerous avenue the internal jugular vein, but whatever their mode of introduction, their evil mission is the same. They are swept along with the blood stream until they encounter a channel sufficiently narrow to arrest their farther progress, at which point they thereupon initiate an infective inflammation, and, conformable to the tissue or organ which harbors the intruder, the symptoms of disordered function or diminished power, with their manifold expressions, should display such urgent signals of distress as must attract immediate attention to the invaded structure.

When in the second stage of sinus thrombosis, either before or after operation, there is a renewal of chills and rapid temperature fluctuations, the formation of metastases is to be apprehended, and a critical inspection of all accessible portions of the body should be exercised, careful scrutiny being directed to the neighborhood of the joints, the fibrous tissue surrounding which is especially prone to attack; interrogation of function of those organs which cannot be inspected must under no circumstances be neglected, for while remedial agencies and surgical procedures may prove ineffective to repair the mischief or to arrest its progress, superficiality in the conduct of a case can by no possibility be justified on the plea of impotence.

Septic embolic masses find their way into the circulation, as has been already stated, with greatest facility through the medium of the jugular vein, hence the urgency of the operation for ligation of this vessel to prevent further infective distribution; that it frequently fails to realize its full purpose, in no wise discredits the procedure. Numerous instances are reported in which subsequent to ligation of the internal jugular metastases have appeared both centrally and peripherally, thus emphasizing the old adage, "All roads lead to Rome." It is nevertheless no very convincing argument to decline closing against invaders the main avenue of entrance to a territory because there exist certain other devious paths

by which admission may at times be effected. Wisdom would seem to indicate, and experience to show, that ligation of the jugular should not be deferred beyond the appearance of the first recognizable metastatic manifestation.

While it is true that no portion of the human body enjoys immunity against the lodgment of septic particles, it is equally certain that the lungs, more often than any other organs, become the repository of infective emboli. According to Hessler, who with indefatigable ardor and tireless effort has tabulated practically all the reported cases of otogenic pyæmia, the lungs are attacked with a frequency one and one-half (1½) times greater than the combined other structures of the body, and in inverse proportion to the virulence of the septic agent and the area of the infarction is the likelihood of a favorable or unfavorable termination greater or less. In the vast proportion of cases, the infarctions are multiple and both lungs are involved, while the lower lobes participate with greater frequency than the upper lobes or apices. When the pyogenic properties of the deposit are attenuated to a considerable degree, contraction and cicatrization of the obturated region may ensue and healing result, but under less favorable conditions the embolus increases rapidly in size, being augmented by fibrin and plastic lymph, which accumulations speedily undergo disintegration by steps analogous to those which characterize the process in the thrombus, and abscess of the lung results, which may perhaps discharge itself into a bronchus, and the patient recovers, but which is more liable to open upon the surface of the pleura and establish a pyopneumo-thorax, or in case it does not rupture into the pleural cavity, to give rise to empyema of the pleura, and failing either of these alternatives, the abscess of the lung is prone to become gangrenous; each of these conditions is fraught with imminent peril to the life of the patient, and may practically be regarded as hopeless.

Metastatic abscesses of the abdominal viscera, kidneys, spleen, and liver occur with relative infrequency, and the collected cases constitute a numerically small addition to the total metastases in the aggregate. The same condition

prevails in regard to the brain, the abscesses of which, in connection with sinus thrombosis, which can with certainty be regarded as metastatic, number but 9, as against 43 which resulted from direct extension of purulent products from the carious bony surroundings.

Peripheral metastases have been recorded in great numbers, and apparently have no selective preferences as regards site, their distribution being universal. Hessler has tabulated 271 such superficial manifestations, and nearly every distinct anatomical structure has been the victim of such a visitation. Not by any means all the metastatic inflammations result in abscess, a moderate percentage fortunately undergoing constructive metamorphosis and organization. In numerous instances septic enteritis also has run a favorable course with complete restoration of normal function. Acute septic parenchymatous nephritis was present in a case of mine already reported, and the subsidence of the inflammation left the organ in unimpaired health.

An interesting motive for discussion is offered in the suggestion that metastatic purulent accumulations may themselves serve as foci of general infection; that, in other words, the circulation, having rid itself of the offending agent by depositing it at some remote part of the patient's anatomy, is liable to reinfection at the instigation of the septic products thus locally developed. However engaging such a theory may appear, any views which are expressed upon the subject must be at the present moment, from absence of all confirmatory data, purely conjectural.

The treatment of metastatic abscess is uniform. Wherever accessible, evacuate the purulent contents immediately, pack with gauze, and allow to granulate.

When death occurs in the third stage of sinus thrombosis, it results in the order of their relative frequency from the following causes: pulmonary and pleural involvement, meningitis, general sepsis, abscess of the brain, and septic enteritis. Other causes have in individual instances been noted, but they represent, for the most part, solitary examples, and their total is numerically inconsiderable.

THE TECHNIQUE OF OPERATION UPON THE SIGMOID SINUS.

The preliminary steps to this operation are precisely such as characterize the usual mastoid operation, *i.e.*, a curvilinear incision in the scalp extending from one inch below the tip upward to a point one-half inch above the temporal ridge, following the general direction of the post-auricular fold. A second incision is made beginning at the centre of the first and extending directly backward toward the occipital protuberance two inches or more as the case may demand; those flaps are elevated and retracted when the operator may rapidly complete the removal with the chisel of the cortex of the mastoid process, and the opening of the underlying pneumatic and diploic spaces with the curette or rongeur, care being especially exercised that the antrum is thoroughly explored; this evisceration of the apophysis will expose within the opening in the bone and running along its posterior border the bulging convexity of the sigmoid groove, the opening of which constitutes the first distinctive step of the sinus operation.

How and where should the sigmoid groove be opened?

How Opened.—The opening of the sigmoid groove may be quickly and conveniently accomplished with the curette or rongeur, but under no circumstances should the chisel be employed for this purpose; the bulging wall of the groove although of dense cortical bone is very thin, and easily yields to firm, slow curetting, the sinus almost never being injured by small detached spicula of bone if these precautions are duly observed. When a rongeur is used to open the groove, an instrument with a beak as broad as possible should be chosen, which will readily eat away the thin bony partition; a sharp-pointed rongeur may, unless great care is exercised, enter the posterior fossa suddenly and with sufficient force to violate the sinus wall.

A method of opening the groove which I have frequently practised has been to place the smooth, blunt handle of a suitable instrument against it, and by gentle tapping with a mallet fracture the wall, which breaks like the shell of an

egg, radiating from the point of applied violence; the small comminutions are readily scraped away with the curette or lifted off with forceps.

Where Opened.—The most accessible part of the sigmoid groove for opening is the knee and descending portion. At these points it approaches near the cortex and comes well forward toward the auditory canal; the knee lies at about the level of the supra-meatal spine, and usually from one-half to two-thirds ($\frac{1}{2}$ to $\frac{2}{3}$) of an inch posterior to it; the position of the groove is, however, very variable, which fact should be constantly borne in mind when operating upon the mastoid cortex and cells preliminary to its exposure; the external conformation of the skull will frequently furnish a valuable hint in this direction, for if the mastoid process is narrow and markedly prominent or convex in contour, one may reasonably infer that the groove will run far forward, approaching the posterior canal wall closely. In a few extreme instances only the thin cortex and inner table have intervened between the sinus wall and periosteum, no diploic structure being present. On the other hand, where the mastoid apophys is is broad and flat, the sinus usually lies at a considerable distance posterior to the canal wall.

When the groove has been opened at whatever point is found most convenient, the further exposure of the sinus is most readily accomplished with the rongeur, the chisel being employed to remove the outer table of the skull wherever its thickness renders difficult the use of the bone forceps; whether the opening in the groove be first enlarged backwards towards the torcular, or downwards towards the bulb, may be a matter for determination in individual instances, but in the majority of cases is immaterial; in any event, all carious bone must be eradicated whithersoever such process may lead. If after the thorough removal of all dead bone the exposure of the sinus is not sufficiently extensive to admit of unembarrassed surgical manipulation, no hesitation need be experienced in removing enough bone to facilitate the procedure which can be rapidly performed without additional shock. Just how much of the sinus it is

necessary to expose in order to remove a thrombus will, of course, vary in direct ratio with the extent of the clot, but it may be anticipated that by so much as the sinus is exposed less than two (2) inches, by just so much are the mechanical obstacles to the operation multiplied.

The question has been raised as to how far in an extreme instance, (as, for example, a thrombus completely obstructing the sinus from the torcular to the jugular bulb) an operator would be justified in removing the sigmoid groove and the overlying cortex. In reply, it may safely be advised to remove whatever is necessary; as a rule, however, it will serve all purposes to remove the groove downward to and including the external margin of the jugular foramen, caution being observed to avoid the posterior condylar foramen behind, and the lower third of the Fallopian canal in front. In uncovering the sinus backward toward the torcular, under exceptional circumstances only will the opening in the skull approach nearer than one and one-half (1½) inches to the median occipital line; beyond this point it is seldom necessary or advisable to remove the bone because of its increasing density and thickness, and the close proximity of the superior longitudinal sinus and torcular; also for the reason that any thrombus which cannot with such exposure of the vessel be removed from its lumen with the curette, must of necessity extend into and involve either the opposite lateral sinus or the superior longitudinal or both. Under ordinary circumstances no such violation of the continuity of the skull is demanded, the thrombus being situated in most instances in the descending portion of the sigmoid sinus, extending to the knee and frequently a short distance above (those cases are exceptional where the clot encroaches greatly upon the lateral sinus), thence downward towards the bulb, and in certain cases still farther into the jugular vein. When the septic phlebitis involves the vein below the bulb, the gravity of the condition is greatly magnified, and more drastic surgical measures must be instituted to surmount the difficulties.

What method is to be pursued in opening the sinus wall after the removal of the sigmoid groove and the exposure

of that portion of the sinus obstructed by the clot? The steps to be employed are here appended in detail and depend upon three conditions which are determined by the presence of:

1. An incomplete or parietal thrombus.

2. A completely obstructing thrombus at the knee or in its vicinity (above or below).

3. A completely obstructing thrombus extending into the bulb or involving the jugular vein, or both.

(1) The first condition, an incomplete or parietal clot, is always extremely difficult of recognition, and were it not for the manifestations of systemic disturbance present, well-nigh impossible. The fact that blood is still flowing through the sinus invalidates the use of the aspirating needle for diagnostic purposes, inspection is of no assistance, for there is no apparent bulging, and we are obliged to depend almost solely upon palpation in estimating the increased resistance in the sinus wall, which usually dimples like a bladder filled with water under the finger tip, and is equally tense in *all directions.* When a parietal clot is present, the wall yields to pressure much more readily along the unobstructed part of the sinus, and as the parietal wall collapses against the visceral, the feeling beneath the finger is as if it rested upon an even, firm surface; while over the affected portion the sensation imparted to the finger is that of contact with a thickened tissue under which lies an unevenly-distributed yielding substance.

Preliminary to opening the sinus the field of operation should be carefully scrutinized, that any fragments of carious bone or necrotic tissue may be detected and removed, then having thoroughly irrigated with bichloride of mercury solution (1 : 5000), the sinus may be attacked under the most favorable conditions possible. In dealing with an incomplete or parietal thrombus the operator must be prepared as soon as the sinus wall is incised to encounter hemorrhage from both directions simultaneously. Therefore, that the loss of blood may not be excessive, it is imperative to obstruct the flow *above and below before the incision is made*, and to continue the pressure after opening the sinus wall and during

the curetting of the same. This control is best maintained in the vicinity of the bulb by carefully and firmly crowding a wick of iodoform gauze between the parietal wall of the sinus and the surrounding bony structures which at this point encircle the sinus like a collar and offer perfect support to any packing; the pressure thus maintained is efficient and greater freedom of movement is permitted the operator for manipulation in this necessarily contracted field if he is unhampered by the presence of an assistant's fingers supplementing the gauze pressure; the control of the sinus at the knee, or the torcular side, of the opening to be made, is satisfactorily preserved by a pad of gauze beneath the left index finger of the operator, it not being safe to thrust gauze between the skull and the sinus wall with force sufficient to arrest the flow of blood from the open sinus because of the undesirable effect of such pressure upon the underlying brain; the blood current being thus held in check, the sinus wall should now be incised with a scalpel in its long axis to an extent sufficient to admit of the convenient introduction and manipulation of a curette with which the clot should be as thoroughly and rapidly removed as is commensurate with safety. The bleeding should not be too firmly controlled or too hastily checked, as the outflow if momentarily favored will often expel loosely attached infective particles which have eluded the search of the curette and might otherwise remain as septic foci. The desirability of the removal of the entire clot finds several opponents in the literature who advocate the wisdom of scraping away only that portion of the thrombus which is purulent or disintegrated and leaving within the lumen of the vessel the fibrino-plastic plug, which will thus prevent the outflow of blood from either end of the incision; in other words, they do not re-establish the circulation either side, but simply pack gauze upon the incision and shut up within the sinus portions of a septic clot which may undergo purulent liquefaction in a few hours and gain access to the circulation, or which may necessitate a second operation and more extensive opening of the sinus with the attendant dangers of additional hemorrhage and shock. The thorough removal of the clot and the re-establishment of the

circulation at the first operation certainly commend themselves as conservative surgical procedures. Just here a word of caution regarding the incising of the sinus wall may not perhaps be amiss. The point of the scalpel should not penetrate deeply into the sinus contents, for often the parietal and visceral walls are closely approximated by the clot and lie almost in contact, and I once saw the point of the knife in this wise thrust through the visceral wall into the brain substance beneath, thus unintentionally opening the subdural and subarachnoid spaces, thereby creating an avenue of entrance for the admission of infective germs to the cerebral structures.

When the evisceration of the thrombus is complete, satisfactory hæmostatic effect will be obtained by firmly pressing a wad of closely folded gauze *upon* the distal extremity of the opening in the vessel and *not crowding any of it into the lumen;* if the gauze is thrust into the sinus, its subsequent removal is attended with annoying bleeding and the blood channel is exposed to the possibilities of renewed infection, while the packing can be removed without exciting secondary hemorrhage.

The bleeding from the jugular bulb is easiest controlled *by packing gauze into it*, the removal of which two or three days later is never followed by hemorrhage of any significance, and usually by none at all, the circuitous course which the vessel follows in this part of the skull resulting in firm and rapid coagulation which successfully resists the pressure in the jugular upon the removal of the gauze.

When the packing controlling the sinus bleeding is in place, the remainder of the wound in the bone and soft parts should be carefully filled with gauze, the pressure of which supplemented by cotton and a firm bandage is usually efficient. Should, however, such measures prove inadequate, a procedure can be adopted which is absolutely certain to maintain ample pressure quite independently of whether the patient displaces or loosens his bandage. This step consists in packing gauze firmly upon the opening in the sinus and then stitching the flaps of the cutaneous wound tightly down upon the packing with heavy sutures. The stitches

can be removed twenty-four (24) or more hours later according to the demands of expediency.

(2) A completely obstructing thrombus at the knee or in its vicinity (above or below).

A completely obstructing thrombus is recognized without great difficulty both by inspection and palpation; the sinus lacks its characteristic smoothness and lustre and is seen to be distended and generally darkly discolored at the site of the clot; granulations may or may not invest the walls. The presence or absence of pulsation is of no material significance. Upon passing the finger along the sinus the roughened area will be at once appreciated in striking contrast to the normal wall elsewhere exhibited, and instead of dimpling easily under the finger the impacted mass has either the consistence and feeling of dough, if it has been formed but a few hours and contains only fibrin, or it is firm, tense, and resisting, if it has existed longer and contains granulations springing from the endothelial lining of the sinus. If not entirely convinced of the exact extent of the obstruction after the employment of the above-enumerated observations, the use of an aspirating needle will definitely define its limits by extracting fluid blood from the patent sinus above and below the clot.

The operative steps to be here pursued are precisely analogous to those just enumerated for the removal of a parietal thrombus; the sinus should be fully exposed above and below the obstruction, and pressure made upon it both at the distal and proximal ends of the clot. The incision must be sufficiently free to admit of the easy introduction and manipulation of a small curette backward and downward, the application of which instrument should be employed upon the visceral wall with caution and upon the parietal wall with vigor.

When, as occasionally happens, the thrombus is recognized very early after its formation and while it is still simply fibrinous and pultaceous, adhering to the parietes of the sinus but loosely, a very short incision is ample, and the expulsion of the bulk of the clot occurs spontaneously, being forced from its site by the pressure of the blood in the sinus,

the elasticity of the meninges behind it, and the expressive impulse imparted by the fingers of the operator.

Where a small firm obstruction exists, the sinus should be very carefully scrutinized between the clot and the bulb, that any respiratory movements of its walls may be detected, for in case of aspiration of the jugular bulb and sinus below the thrombus, danger of aërial embolism is to be apprehended unless the precaution of ligating the jugular preliminary to opening the sinus is observed.

After the thorough removal of the clot, the visceral wall should be carefully inspected with a probe in order that any fistulous tract leading to an abscess in the occipital lobe or cerebellum may be discovered.

Where a very small incision in the sinus suffices for the evisceration of the clot, the firm application of a gauze pad immediately upon it, and of one on the intact sinus wall at each side of it, exercises efficient pressure when supported by cotton and a tight bandage.

(3) A completely obstructing thrombus extending into the bulb or involving the jugular vein, or both.

The recognition of this condition should be, as a rule, attended with few difficulties save only in those instances where the bulb alone is involved. The local symptoms are very pronounced and may be briefly designated as an exaggeration of those already enumerated as characterizing a small complete obstruction, the essential element of difference being the greater extent of sinus involved in the infective occlusion. To an operator who lacks the needful confidence for dependence upon the sight and touch in diagnosing the thrombus, the aspirating needle will afford the desired assurance, for when thrust into the sinus at various points over the suspected area it will exhibit either pus, serum, or nothing at all, as the case may be, but in any event no venous blood.

In this variety of thrombus the incision should begin at its distal extremity, and the re-establishment of the circulation from the torcular side be first attempted. Here it will be necessary to guard against hemorrhage from one direction only, and a gauze pledget under the left index

finger will sufficiently compress the sinus wall to control the flow. The incision beginning at the torcular end of the clot should extend downward towards the bulb about one and one-half (1½) inches. Should the circulation from the torcular be re-established simultaneously with the incision, it need not occasion the operator any especial embarrassment; moderate pressure will hold it in check until he can thoroughly curette from its site that portion of the clot exposed by the incision and irrigate the opening with bichloride of mercury solution (1 : 5000), thus creating a thoroughly aseptic entrance to the vein and a sterile surface upon which to place the permanent gauze hæmostat.

When following the incision the circulation is not immediately re-established, or if the flow prove but scanty, the incision may be extended farther backward in the sinus wall, if the opening in the sigmoid groove admits of it, or the very common procedure may be adopted of carefully introducing a small curette into the lumen of the sinus, with a rotary motion directing the force exerted in scraping upward and outward (that no damage may be sustained by the visceral wall) until there is a rapid hemorrhage, which should be momentarily encouraged, thus favoring the expulsion of any loosely attached infective particles which may have eluded the search of the curette. A permanent gauze hæmostat is now applied in the manner already indicated.

These procedures constitute the steps employed in the first half of the operation, or the re-establishment of the circulation from above.

The second half deals with the re-establishment of the circulation from below, and is conducted as follows: The original incision made in the sinus wall is extended, either with a scalpel or scissors, well downward to the bulb, and curetting again resorted to. The application should be attended with equal care but with greater vigor than above, the tortuosity of this portion of the sinus rendering the attachment of the clot more tenacious and less accessible than near the knee, hence the thorough removal is proportionately more difficult.

The flow of the re-established circulation from this direc-

tion, when the jugular is entirely unobstructed, is very rapid, a fact which should be borne in mind as an index of comparison, and the operator should not rest contented with the restoration of a slow current of blood, which may come from the inferior petrosal sinus, while the bulb still remains occluded, but should persist in the use of the curette until the flow becomes copious and rapid. Provision may be made against too profuse bleeding by digital pressure over the jugular in the neck, to be maintained during the curetting, after which a tampon of iodoform gauze, thrust firmly but not too forcibly into the bulb, gives prompt and efficient control.

It may not be inopportune to recall in this connection the fact that the jugular foramen serves as the avenue of exit for the eighth pair of cranial nerves, and it is entirely within the realms of possibility that the employment of undue force in the introduction of gauze might serve as the source of annoying, if not serious, interference with the functions of the pneumogastric.

The circulation having been re-established from both directions, and the gauze packing being in position, the visceral wall of the sinus, lying exposed between the two tampons, should be carefully investigated with a probe, that any softening or fistulous tract may be detected leading to a subdural collection of pus, or to an abscess of the brain. In the absence of such complications and the sinus wall being intact, the whole should be thoroughly irrigated with bichloride of mercury solution (1:5000), and folded strips of gauze carefully packed into the bone. The extreme angles of the cutaneous flaps should then be stitched, leaving an external wound sufficiently large to admit of unembarrassed inspection and subsequent dressing. This wound must be filled with gauze, covered with cotton, and the apposition maintained by a firm bandage.

The shock attendant upon such an operation as has just been described, prolonged, as it occasionally is, by vexatious delays of one kind or another, is frequently very pronounced. Where its manifestations become urgent toward the end of the operation, they may be speedily alleviated, and the

flagging energies of the heart augmented, by an intra-venous saline injection of from sixteen (16) to twenty-four (24) ounces introduced at a temperature of 105° to 108° F. through the median basilic vein. The effect of this procedure is electrical upon the patient, and most gratifying to the operator. Should it happen that appliances are not at hand for intra-venous infusion, a very efficient substitute for this measure will be found in the injection into the bowel of a pint or quart of normal saline solution at a temperature of 110° to 115° F. This can, of course, be done with a Davidson or gravity syringe, and is a most valuable supplement to the usual hypodermatic stimulation ordinarily depended upon during the administration of the anæsthetic.

The length of time which should intervene between the operation and the first dressing will depend upon the presence or absence of marked systemic disturbances. Should sudden and great fluctuations of temperature or rigors appear, or unaccountable soakage of the dressings be manifest, it is the part of caution to inspect the wound at once, and to readjust dressings and bandages. In the absence, however, of such unfavorable symptoms, the dressings may safely remain undisturbed for three or four days. It will, however, frequently be found a very grateful relief to the patient to have the bandage and outer cotton daily renewed. Before removing the gauze packing of the wound it should be thoroughly saturated with warm solution of bichloride of mercury. This serves to sterilize the secretions from the wound which have permeated and stiffened the dressings, and facilitates the removal of the latter. When the gauze packing of the sinus has been placed in position after the manner already indicated, its removal is occasionally attended with very scanty bleeding, but, in the majority of instances, by none at all. The reapplication of dressings may be made with only sufficient firmness to insure their remaining in position.

In this connection may be appropriately mentioned a procedure which I have adopted in three vexatious and puzzling cases where the difficulties of diagnosis were unusually perplexing, and which commends itself as applicable

to the solution of several confusing conditions liable to be encountered in any suspected case of sinus thrombosis, *the more especially if the site of the clot be at or below the jugular bulb.*

The embarrassment occasioned an operator under these by no means exceptional circumstances will appeal forcibly to many surgeons who have encountered just such uncertainties in the search for a suspected thrombus, and who may, perhaps, have reluctantly abandoned the pursuit to the subsequent detriment of the patient, having lacked the fortitude or, better said, hardihood to risk cutting open a healthy jugular bulb. In the belief that the appended experiment affords a satisfactory solution to this surgical problem, its method of performance is presented in detail.

A recent case affords a graphic illustration of the advantages of this diagnostic step. The patient had pronounced symptoms of sinus thrombosis in the second stage, and all the descending portion of the sinus, including the knee, had been exposed well down to the jugular bulb. The sinus was covered with lymph, which offered but slight resistance to an effort at its removal; its wall dimpled readily under the finger and pulsated plainly. An aspirator introduced at the knee filled at once with dark fluid blood, such as characterizes the contents of a healthy sinus; reintroduced in the descending portion of the sinus, it was again promptly filled with normal venous blood; a third puncture at the horizontal segment of the bulb was equally productive of the same confusing evidence. All the exposed portion of the sinus was evidently filled with fluid blood, flowing into it either from the jugular or from the torcular side. Great reluctance was felt against abandoning the operation, notwithstanding such unproductive efforts at locating the thrombus, which had been indicated by a convincing array of symptoms, and equal hesitation was experienced in making a free incision into what might (symptoms to the contrary notwithstanding) prove to be a healthy blood channel.

In this surgical dilemma it occurred to me that by expressing the blood from the sinus along the axis of the

channel until it was empty and its walls semi-collapsed, and maintaining this state of the vessel momentarily by pressure of the finger ends or gauze pads at each extremity—that then, if the obstructing pressure were suddenly removed from one end of the devascularized channel, the same would immediately fill with blood, provided there was no obstacle to its entrance at the corresponding side, while if such obstacle existed the channel would remain empty. It was merely a practical application of the common experiment of collapsing a vein upon the back of the hand by making digital or other pressure along its long axis from the wrist downward toward the finger tips: the vessel walls remain collapsed because the valves prevent the flow from the proximal side, while the pressure of the finger arrests the current from the distal side. The intra-cranial veins are, of course, not supplied with valves, hence the obstructive pressure must be maintained simultaneously at each side. The manœuvre was a most unqualified and gratifying success, and upon the very first trial completely relieved the perplexities of the situation. The method of its performance was simplicity itself. The left index finger was placed across the sinus at the bulb with sufficient firmness to cause obstructive pressure and collapse of the walls at that point; the right index finger was then placed close beside the left, and with a stroking, stripping movement, carried steadily along the course of the sinus toward the torcular as far as the knee, at which point the finger rested with firm pressure. The result of the procedure was to expel the blood from the sinus and leave its walls in a collapsed condition between the two controlling fingers. An assistant now makes firm pressure upon the jugular vein low down in the neck, so that the backward pressure of the blood current toward the bulb may be as much as possible augmented.

It is now obvious that in case no obstructing thrombus existed in the vein or sinus, the collapsed walls of the latter would be immediately distended with blood upon removing the pressure of either finger. In the case under consideration, after expressing the blood from the sinus, and collapsing its walls, the finger making pressure at the bulb was

withdrawn, but the sinus did not refill, thus demonstrating conclusively that an obstruction existed at the bulb or below in the jugular vein. Upon incising the sinus wall there was no bleeding whatever, so long as pressure was maintained upon the side toward the torcular, but upon discontinuing it copious and rapid bleeding ensued, convincing evidence that the sinus was unobstructed in that direction. It will be readily appreciated that this procedure is especially applicable to the detection of a thrombus situated at the bulb below a point where palpation can be practised with facility, and hence beyond the reach of tactile recognition—a fact which renders the expedient so much the more valuable since the diagnosis of thromboses having their site in the descending portion or at the knee of the sinus is, when the lesion is suspected, usually a matter of no great difficulty. When, however, we can clearly demonstrate that the easily accessible portions of the sinus are unoccluded, we possess in this manœuvre a means of converting suspicion of the existence of a clot at the bulb or in the jugular into absolute certainty, or, failing that, into positive evidence of the absence of such lesion.

The performance of this experiment was in the third of these cases in which reliance was imposed in it quite difficult of execution, owing to the only condition not entirely within the power of the operator to control. The case was an extensive perisinuous extra-dural abscess of the posterior and middle fossæ, and the removal of the carious bony surroundings necessitated an extensive exposure of the granulating dura. Inasmuch as the sinus wall was completely invested with necrotic granulations and plastic lymph which adhered very firmly and resisted moderately forcible application of the curette, a careful scrutiny of the sinus was imperative lest perchance a condition of thrombosis should pass unrecognized. The closer the sinus approached to the jugular bulb, the denser grew the surrounding lymph, and the more resisting the sinus wall to palpation, so that the tactile sense supplied very incomplete and unsatisfactory evidence. Aspiratory puncture was resorted to and apparently normal sinus blood extracted. The expression experi-

ment was then tried, and, owing to added thickness of the walls and their opposing rigidity, was accomplished imperfectly and with difficulty, nevertheless blood did flow into and distend the partially emptied vessel when the obstructive pressure was renewed alternately from either end. No further investigation was undertaken, the sinus being regarded as patent. The patient made a speedy and uneventful recovery. Granulations and plastic lymph upon the sinus wall are of frequent occurrence in suspected cases of infective thrombosis, but will rarely attain to proportions such as will oppose a serious obstacle to the satisfactory performance of this usually simple experiment. A scarcely valid objection to the procedure will be found in the *possibility of detaching from the vessel walls a recently formed and loosely adherent thrombus*, and liberating it for transmission into or distribution through the general circulation. This is, however, a danger of which one need feel but remotely apprehensive, provided due caution is exercised in the performance of the experiment, for since the procedure is designed to demonstrate the presence or absence of an obstruction at the bulb, *all expressive movements along the course of the sinus should be made from the direction of the bulb backwards toward the torcular*, in which event it is quite evident that very little if any increased tension will have been applied to the sinus at the site of the lesion, the force exhibited being displayed in just the opposite direction.

That this experiment will require frequent repetition to determine its exact diagnostic value, I readily admit; that it has, however, on three consecutive occasions relieved me of most embarrassing doubts, I just as stoutly maintain; and that its performance, with care, will demonstrate its merit and solve many a perplexing problem, seems a not too sanguine expectation.

The performance of the experiment is greatly facilitated by liberal removal of the sigmoid groove; an exposure of the sinus in its course of about two inches affording ample space for convenient manipulation.

The steps which I have thus minutely described are those

which characterize all recognized operations upon the sigmoid sinus when the infective inflammatory processes are limited to its course within the skull, and when it is possible to re-establish the circulation both from above and below. In those very extreme cases where the infection has extended into the jugular, and has resulted in a septic phlebitis, possibly suppurative in character, it will be manifestly impossible to re-establish the circulation from that direction; hence, in order that the dissemination of septic material may be anticipated, or, if it has already begun, that further distribution may be prevented, it becomes imperative to ligate the jugular as low down as possible, at the clavicle, and again high up, close to the bulb; the facial vein should also be tied, and the jugular resected close to the ligatures and removed entire from the neck. I make no attempt at describing the details of such operation, for it is in no sense distinctive of sinus thrombosis, and a much more able and graphic description of the procedure can be found in any reputable system of surgery than I could possibly hope to present.

Having failed in the attempt to restore the circulation at the bulb because of the extension of the inflammation into the jugular, and having ligated that vessel after the manner indicated above, the jugular bulb should be thoroughly but not too forcibly syringed out with solution of bichloride of mercury (1 : 5000), the irrigation being directed downward into the bulb through the incision made for the purpose of curetting. The practice of placing the nozzle of the syringe in the divided end of the jugular below the bulb, and washing the contents forcibly upward and out of the opening in the sinus wall may be a cause of serious complications, for if the visceral layer of the wall is softened the injected fluid may rupture it, and pass into the subdural or subarachnoid spaces, distributing infective matter as it goes.

A precaution frequently neglected, but which ought never to be disregarded, is the inclination of the table on which the patient lies. At the moment of opening the sinus wall, the foot of the operating table should be appreciably elevated, by which procedure a double purpose is served: First, the

pressure of the blood in the sinuses of the dura mater is measurably increased and the likelihood of the admission of air to the open vein reduced to the minimum. With the patient lying evenly recumbent and with the heart acting feebly, the pressure within the sinus is very low. If now this pressure be suddenly further reduced by the rapid hemorrhage which accompanies the expulsion of a thrombus, the entrance of air, with fatal termination, must be considered as a not especially remote contingency. The second advantage gained by lowering of the head is a physiological one, namely, the maintenance of the equilibrium of the general intra-cranial fluids which may be seriously disturbed by the suddenly induced anæmia of the brain consequent upon the always rapid and frequently very copious bleeding of the sinus operation. The lower half of the wound made in the neck for the purpose of exposing the jugular vein should be stitched and the remainder packed with gauze and allowed to granulate. In applying the bandage about the neck, a pad of cotton should be laid over the opposite jugular in order to minimize the pressure upon it, since it is now performing the added function of its fellow.

Upon returning the patient to the bed, its foot should be elevated, external heat applied about the patient's body, and hypodermatic cardiac stimulation employed if needful.

Briefly to summarize the essential suggestions of the technique just elaborated, it appears to the writer that a most valuable adjunct to the therapy of sinus thrombosis is *intra-venous infusion* of normal saline solution at a temperature of 110° F. or thereabouts, the quantity employed to be graduated to the exigencies of the occasion—between 12 and 20 ounces; that its employment before the beginning of the operation as a prophylactic against shock in any case where the vital energies are already materially reduced as the result of a protracted struggle against sepsis would be beneficial, I fully believe and shall not hereafter in my own practice under such conditions, should opportunity offer, hesitate to so employ it. It is not an uncommon experience for the heart thus stimulated to again exhibit flagging powers from four to six hours later; this occurrence should be anticipated

and the surgeon be prepared to repeat his infusion in the other arm; the results of which second encouragement to the heart to do its work are apt to be permanent when supplemented by heat and the hypodermatic exhibition of cardiac stimulants.

Aspiratory puncture of the sinus as a procedure of diagnostic importance has, it appears, in the light of broadening experience, received an amount of consideration to which its value does not entitle it. As a diagnostic aid in parietal thromboses it is worthless, and in obstruction of the jugular bulb, when the sinus above is patent, is similarly valueless. With no intention to disparage the needle, it is serviceable then simply as a confirmation test when one is already practically assured of the existence and location of the clot, but in those most puzzling conditions—parietal thrombosis and obstruction in the bulb and upper jugular—where you really need aid, it is a vain dependence; for the latter condition, however, I think that with experience the "*expression experiment*" will prove efficient. *Time*, always an essential factor in all operations of gravity, is nowhere entitled to more respect in its flight than during the sinus operation, and while all surgeons should deprecate the practice of operating against time merely as a pretext for the display of physical force and manual dexterity, which affectation is infallibly exhibited at the expense of caution and thoroughness, in this grave situation the operator should sacrifice every detail save cleanliness and thoroughness to the demands of time, a few moments more or less being important elements in a favorable or unfavorable termination.

It seems not too sanguine an expectation to believe that as our knowledge of symptomatology and technique improves there should be no fatalities in the first stage of sinus thrombosis, that the second stage should furnish only an occasional fatal result, and that the third stage, in the absence of gangrene of the lung and purulent meningitis, should be regarded as a still hopeful surgical condition.

While our present operative technique in intra-cranial infective diseases of otitic origin falls far short of the standard of perfection, and leaves much still to be desired, it becomes

eminently satisfactory in comparison with the disconsolate views entertained by some surgeons upon the subject a few years ago—notably Molthan and von Troeltsch, the former of whom in 1880 expressed himself as follows: "The trephining of the mastoid process when it is the seat of abscess is from a theoretical standpoint entirely irrational: the admission of air, and the consequences of the operation itself, aggravate the inflammation and the suppuration; the pus becomes ichorous and more infective, with the added danger for the patients of pyæmia; and experience, moreover, has taught that through no operation whatsoever is a fatal termination prevented, but, on the contrary, such a result is simply precipitated." (Hessler, p. 465.)

Von Troeltsch is no such prophet of disaster as the writer just quoted, but he also takes a most gloomy view of the prognosis of such cases; still he advocates "hope and work."

Between the despairing attitude of Molthan in 1880 and the buoyant optimism of to-day, unfaltering hope and unflagging effort have successfully bridged a seemingly impassable gulf; while between our present position of reliant confidence in antisepsis and improved surgical methods and the realization of our ambition, the attainment of which anticipates a therapy adequate for a cure of infective sinus thrombosis in every case, there stretches a barrier even more formidable to surmount. "Hope and work" will achieve all things, and with the magnificent progress of the past before us as an animating impulse, who shall challenge our zeal, or deny the possibility of its beneficent fulfilment?

SYSTEMATIC REPORT ON THE PROGRESS IN OTOLOGY DURING THE SECOND QUARTER OF THE YEAR 1898.

ARRANGED BY DR. A. HARTMANN.

Translated by Dr. ARNOLD H. KNAPP.

PHYSIOLOGY OF THE EAR.

101. MEYER, MAX. On the theory of difference tones and auditory perception in general. *Zeitsch. f. Psychologie* und *Physiologie des Sinnesorgane*, vol. xvi.

102. MEYER, MAX. On the intensity of single tones in compound sounds (clangs.) *Ibid.*, vol. xiii.

103. MEYER, MAX. The function of the auditory organ. *Verh. der physik. Ges. zu Berlin*, vol. xvi., No. 5.

101. The author opposes Helmholtz's theory of hearing. This theory explains defects in hearing, islands and gaps, but leaves a number of important normal processes unexplained. The resonator theory rests on Ohm's law, and defines a tone as a sinus-vibration—single vibration ; many facts speak against this law, especially the occurrence of the difference tones. The separation of the excitations through the ear takes place by the differently frequent excitation of the nerveterminals in the cochlea. Pitch is not determined by a particular function of the nerve terminals, but through the various movements of the basilar membrane, caused by the vibrations of the ossicles. Thus every nerve fibre could bring about the sensation of any tone in the scale—of course consecutively—if it were excited in the relative rhythmic manner through movements of the stapes, and with it also of the basilar membrane. By movement of the stapes the membranous cochlear canal is distended—the larger the movement, the greater

is the part of the basilar membrane that is pushed out, and thus the number of excited nerve fibres and the tone intensity are increased; by loud tones the entire basilar membrane is distended. BRÜHL.

GENERAL.

a.—REPORTS AND GENERAL COMMUNICATIONS.

104. BIEHL, C. The frequency of the diseases of the various parts of the ear. *Arch. f. Ohrenheilk.*, vol. xliv., p. 263.

105. KAYSER, R., Breslau. Reports of cases treated in my private clinic for the nose, throat, and ear in 1895 and 1896. *Monatsschrift f. Ohrenheilk.*, No. 4. 1898,

106. DE ROSSI, E. The examination of the ear in railway employés. *Archivio ital. di Otol.*, vol. vi., p. 1.

107. KOLLER, MAX. Annual report for 1897–98 of the Royal Deaf-Mute Institute in Munich.

108 (A and B). HARTMANN, A. The question of physicians for schools. *Berliner Aerzte-Correspondenz*, No. 15, 1898.

104. The figures quoted do not agree with those usually found in statistics owing to the material (soldiers and recruits).

BLOCH.

105. In acute otitis media, after paracentesis KAYSER recommends the dry treatment with iodoform gauze. In curetting an abscess behind the ear in a child, four months old, suffering from an acute otitis media, the dura was injured and a fatal meningitis set in. A case of pyæmia after osteo-phlebitis in the temporal bone is fully reported. KILLIAN.

106. DE ROSSI believes that the functions of the ear should be examined in railway employés not only at the beginning but should be repeated every four or five years. The result of the examination is recorded graphically by means of a diagram.

GRADENIGO.

107. The instruction of those pupils with remnants of hearing, which had previously been begun, was continued during the year; a new division was formed, composed of nine suitable pupils from the lower classes. These pupils received two hours of extra instruction in the week. The results obtained with these younger children were much better than those with the older pupils. A perfectly clear articulate speech, agreeing in rhythm and pitch with the normal speaking, was obtained without difficulty,

and the acquired amount of speech remained permanent with only slight practice. It was quite striking to notice the increased power to read lips and desire to speak.

The author agrees with Bezold that the combined instruction of the half deaf and the totally deaf produces a waiving of the hearing remnants which the former still possess. The Munich academy employ not only hearing exercises but speaking and speech instruction, with use of the faculties of lip reading and hearing and in close connection with the recollection of speech still present. The selection of pupils without the use of the continuous tone-series is unsafe and uncertain. H.

108 (A and B). HARTMANN reports the cases of two children who had remained four years in the lowest class of the public school. The one, after treatment, regained its hearing and was enabled to advance to the higher classes. In the other, the deafness could not be improved. He therefore recommends the appointment of a school physician who should determine the cause of persistent lack of attention, the adoption of an appropriate plan of treatment, or that the child be sent to a school for the deaf.

In the second communication, the case of a child is cited which was regarded as weak-minded because it did not reply to questions. A casual examination showed the child to be a deaf-mute.

b.—GENERAL PATHOLOGY AND SYMPTOMATOLOGY.

108. MATTE, F. Contributions to the experimental pathology of the aural labyrinth. *Arch. f. Ohrenh.*, vol. xliv., p. 249.

108. Inflammation of various parts of the labyrinth were caused by chemical and mechanical irritations and bacterial cultures. The experiments were generally performed on doves. The well known disturbances of equilibrium resulted; sequelæ of the inflammation and osseous formation in the labyrinth capsule were found at the histological examinations. These changes were also observed by MATTE where a small foreign body was inserted into the labyrinth of a dove, and was found to be encapsulated in a thick membrane. BLOCH.

c.—METHODS OF EXAMINATION AND TREATMENT.

109. LUZZATI. The field of hearing in space. *Gazzetta medica di Torino*, March 26, 1896.

110. LUCAE, A. On the mechanism of the sound-conducting apparatus, after use of the pressure probe, and an improvement on this instrument. *Arch. f. Ohrenheilk.*, vol. xliv., p. 245.

111. OSTMANN. Experimental investigation of massage of the ear. *Arch. f. Ohrenh.*, vol. xliv., p. 201. 1 Part.

112. POLITZER. Our present knowledge of rarefaction of air in the auditory meatus and the massage of the ossicles. *Ann. des mal. de l'or., du lar.*, xxiv., 4.

113. MARAGE. Ear trumpets. *Arch. international.*, xi., 2.

114. FERRERI, G. Clinical experience with eucain. *Archivio ital. di Otol.*, vol. vi., p. 83.

109. LUZZATI has shown the value of the auricle in sound perception in some experiments with the watch. The hearing distance in the anterior meridian is much greater than in the posterior. GRADENIGO.

110. On the dead subject, pressure with the pressure probe causes the entire ossicular chain to move inward, and the axial band to be stretched. On this depends the advantage of using the pressure sound over the pneumatic massage. An improvement can only be expected when the disease has not progressed too far, when whispering voice can be heard up to 2 *m*, when Rinne's experiment is positive though shortened, and there is no limitation at the upper end of the scale. The apparatus has again been improved. BLOCH.

111. After an historical introduction, the various methods of massage are described. With the use of two Marey capsules, it is shown that the so-called double massage has no effect, as the air impulse from the Eustachian tube is equalized from the side of the auditory canal. Too violent massage causes hyperæmia and even hemorrhages in the mucous membrane. BLOCH.

112. In this paper, read at the Moscow Congress in 1897, POLITZER describes his and Delstanche's experiments, to show that air rarefaction of the auditory canal causes greater excursions of the ossicles and changes of pressure in the labyrinthine fluid than air condensation. Both methods are then described, when used separately and combined, as to their diagnostic and therapeutic worth. ZIMMERMANN.

113. MARAGE claims that with his masseur-trumpet he can increase the sound, especially repeat the timbre and pitch, and reproduce the action of the masseur of Delstanche. This

small apparatus consists of a flat capsule of ebony, containing a rubber membrane, fitting on one side into the funnel-shaped mouthpiece, and on the other side into a conical opening which is introduced into the auditory canal. ZIMMERMANN.

114. FERRERI has employed eucain in seventy-seven operations on the ear, throat, and larynx, and considers it superior to cocaine. GRADENIGO.

EXTERNAL EAR.

115. BROWN, W. F., London. Reattachment of a bitten-off ear. *Lancet*, No. 3901, 1898.

115. The auricle and a part of the skin over the mastoid of a boy, fourteen years old, were bitten off by a horse. The tragus and a small part of the helix remained. The auricle was washed in warm water, and reattached with eight sutures. Only a small portion of the lowest part sloughed.

MIDDLE EAR.

a.—ACUTE OTITIS MEDIA.

116. MCKERNON, J. F. Report of a case of severe hemorrhage, following paracentesis of the drum membrane. *The Laryngoscope*, May, 1898.

117. BROWN, W. H. Recurrent arterial hemorrhage from the ear. Ligature of internal carotid. Recovery. *Brit. Med. Journ.*, May 7, 1898.

118. DENCH, E. B. The technique of the mastoid operation. *N. Y. Eye and Ear Infirmary Reports*, Jan., 1898.

119. BURNETT, CHAS. H. A case of faucial, nasal, and aural diphtheria. *The Philadelphia Polyclinic*, May 21, 1898.

120. BONAIN. Mastoid osteo-periostitis after acute otitis media, with complications. *Rev. hebdom. de lar., d'otol.*, No. 16, 1898.

116. The case was that of a girl, thirteen years of age, who complained of pain in the right ear, which came on very suddenly, after jumping the rope with other children. The pain being severe, she sought advice. The drumhead was found bulging, and of a purplish color. An incision was made in the most prominent part of the membrane. This was followed by a copious and alarming flow of blood from the external meatus. To control the hemorrhage, which was arterial, it became necessary to make

pressure over the common carotid artery. At the same time, a strip of iodoform gauze was pushed through the opening in the drumhead, while the canal was further packed, the pressure on the carotid being gradually removed. The writer believes that there was rupture of one of the vessels supplying the tympanic cavity, during the violent exercise. GORHAM BACON.

117. BROWN's case was as follows: A child, aged five years, had follicular tonsillitis followed by otitis media and otorrhœa. There was little pain, and only slight rise of temperature. Two weeks later, without obvious cause, free arterial hemorrhage took place from the right ear, about a pint of blood being lost. The ear was packed with gauze and a compress for four days, but a few hours after the removal of the tight dressing, a second violent hemorrhage occurred. A swelling bulging into the soft palate and pushing inwards the tonsil was then noticed, and, believing that the source of the hemorrhage was the internal carotid artery, Brown ligatured that vessel. No further bleeding occurred, and the child ultimately recovered.

ARTHUR CHEATLE.

118. DENCH first calls attention to the importance of having the field of the operation thoroughly sterilized, as well as all the instruments used. He then describes the different steps in the mastoid operation, as well as the Stacke-Schwartze operative procedure. Reference is also made to the operation of removal of carious ossicles, as well as to the operative measures for the relief of intra-cranial complications. GORHAM BACON.

119. The patient, three years old, met with a fracture of the femur and humerus, and was brought to the hospital for treatment. Thirteen days after admission, the glands in the neck were enlarged, and he complained of sore throat. A culture was made and diphtheria was diagnosed. The patient was isolated. Subsequently the disease invaded the nose, as shown by the presence of the Klebs-Löffler bacillus, streptococci, and staphylococci. From the first the ears were probably attacked, as there was a thin discharge from the auditory canals. For the discharge from the ears, a solution of formaldehyde was used with much benefit. BURNETT advises that, in cases of diphtheria with faucial, nasal, and aural discharges, cultures should be made from all these localities until cultures from all these regions are negative. Otherwise there may be reinfection of recovered territories from those still infected, as apparently occurred in this case. GORHAM BACON.

120. To show that, though the outer cells and the mastoid periosteum may seem normal, there may be deeper changes present, BONAIN reports the case of a boy, fifteen years old, where an extradural abscess near the sinus, with destruction of the neighboring bone, was found, and the case of a man, forty-eight years old, where in addition a perforation into the digastric fossa had occurred with gravitation abscess. ZIMMERMANN.

b.—CHRONIC PURULENT OTITIS.

121. ADAMS, J. L., and MCAULIFFE, GEO. Operations in latent mastoiditis of infants. *New York Eye and Ear Infirmary Reports*, Jan., 1898.

122. WHITING, FRED. The significance of aural polypi in connection with carious disease of the tympanum and accessory cavities. *New York Eye and Ear Infirmary Reports*, Jan., 1898.

123. SCHWABACH. Tuberculosis of the middle ear. *Berliner klinisch. Wochenschrift*, Dec., 1897.

124. WINCKLER. Tuberculosis of the middle ear. *Wiener medic. Presse*, Nos. 17 and 18, 1898.

121. In this paper, reference is made to the sutural lines, and the structural defects or peculiarities existing in the bones in children, which often allow the passage of septic material directly to the brain. The symptoms of mastoid disease in children are not very definite, so that the diagnosis is often difficult. ADAMS and MCAULIFFE recommend thorough removal of all septic material in the mastoid process in cases of chronic infantile otorrhœa which do not resolve in a reasonable time after all accessory causes have been removed, and where the drainage is poor. The notes of several cases are given. GORHAM BACON.

122. WHITING reports several cases, and says that the structural changes most commonly encountered in their relative order of frequency are:

1. Superficial caries of the ossicula and tympanic walls.
2. Caries of antrum and aditus with granulations occluding these spaces.
3. Caries of Fallopian canal with destructive osteitis.
4. Caries of tegmen tympani or antri, with perforation into middle or posterior fossa.

The conclusions are that no attempt should be made at the removal of polypi and granulations, but rather that the procedures

so instituted should be more thorough, and under all circumstances include the extirpation of any eroded bony surfaces; and that such operations ought to be undertaken only at the hands of those that possess the requisite surgical skill and moral fortitude to successfully meet any complication which may arise from the infection to which the so-called simple operation has exposed the patient. GORHAM BACON.

123. Seven per cent. of the tuberculous suffer from otorrhœa; in two thirds of the temporal bones of tubercular subjects which had been examined, the tubercular nature of the otorrhœa was confirmed; the otorrhœas of the tubercular amounted to 2.5 per cent. of all otorrhœas; male tubercular subjects are more disposed to otorrhœa than female; the first and fourth decade of life are more prone; an exciting cause may be absent. The tubercular suppurative otitis runs a typical course, especially in advanced phthisis, with a painless onset, a rapid, uncontrollable destruction in the ear, or a subacute course in more favorable cases, and finally rarely as an acute otitis media. The diagnosis can usually be made from the clinical course: painless onset, considerable deafness, early tinnitus, tubercle bacilli in the otherwise not peculiar discharge. The drum membrane is diffusely but not intensely reddened, and thickened or intensely congested, bulging in the posterior half. The perforations, usually multiple, are situated in the lower part of the drum membrane; frequently the defect is total. Follicles are rare. The external auditory canal may be constricted by periosteal thickening, or the bony part may be carious in places. The tympanic mucous membrane is thickened, granulating, and covered with a ropy, tenacious secretion. On the labyrinthine wall there may be rough areas beneath the granulations. The ossicles may be partly present or absent; facial paralysis with extensive caries occurs frequently, though usually just before death; more rarely erosions of the carotid may occur.

Twenty-six temporal bones were examined; in 16 the suppurative process was surely tubercular, macroscopically large areas of destruction were found in the bony and in the soft parts; even the labyrinth was involved. The Eustachian tube usually escaped involvement; the drum membrane was always thickened, the seat of a small cell infiltration with miliary tubercles and giant cells. The manubrium was always destroyed, frequently the branches of the stapes and the long process of the incus were missing.

The mucous membrane of the middle ear and of the mastoid process was generally the seat of a tubercular inflammation; the disease often invaded the underlying bone, and in extreme cases destroyed the Fallopian canal and entered the labyrinth; in these cases pathological changes were found in the membranous labyrinth. The invasion of tubercle bacilli usually took place through the Eustachian canal, though it may occur through the circulation in general tuberculosis.

Prognosis is unfavorable, though the ear process rarely produces death through meningitis or sinus thrombosis. The treatment consists in the general treatment for consumption; locally, the ear is irrigated and drained with gauze. If the bone is extensively involved the radical operation must be considered when the general condition is good; but a cure can only be expected in primary tuberculosis of the mastoid. BRÜHL.

124. WINCKLER has operated upon 9 severe cases of tubercular disease of the middle ear. In 5 cases of extensive granulating tumor, one died from tubercle in the third ventricle, the others recovered. In 4 cases of the ulcerating form of tuberculosis, 1 was healed, the others succumbed to a purulent meningitis. The author concludes that the prognosis is not absolutely bad if the diagnosis be made early. POLLAK.

c.—CEREBRAL COMPLICATIONS OF OTITIS MEDIA PURULENTA.

125. WOODWARD, J. H. A case of cerebellar abscess; autopsy. *N. Y. Med. Journ.*, June 11, 1898.

126. FISHER, E. D. When is surgical interference justifiable in cerebral disease? *N. Y. Med. Journ.*, April 16, 1898.

127. BRONNER, ADOLPH. Notes on a case of extra dural cerebral abscess of aural origin with thrombosis of lateral sinus, in which the sinus was not opened; recovery. *Lancet*, April 2, 1898.

128. MARSH, F. Cases of cerebral abscess in connection with chronic suppurative middle-ear disease. *Brit. Med. Journ.*, April 30, 1898.

129. GERONZI, G. The etiology of cerebral complications of aural origin. *Archivio ital. di Otol.*, vol. xxvii., p. 124.

130. GRADENIGO. On the diagnosis of otitic cerebellar abscess. *Archivio ital. di Otol.*, vol. xxvii., p. 161.

131. JORDAN. Cases of intracranial complications of otitis. *Arch. f. Ohrenhlk.*, vol. xliv., p. 169.

125. A boy, fourteen years of age, was operated on for mastoid abscess of the left side. On making a Wilde's incision, pus was evacuated and a carious opening was found leading to the mastoid cells. The suppurating area was curetted, but the antrum and middle ear were not entered. The boy went home shortly afterwards and was not seen again by the writer for more than a year, when he returned, on account of a recurrence of the otorrhœa and a reopening of the wound over the mastoid. About a year later, he suffered from a third attack. At this time, he was pale and thin. He soon had a chill followed by a temperature of 103.5° F. Other symptoms were severe pain in the middle of his forehead, irritability, stupor, and irregular pulse. He died very suddenly.

Autopsy: Purulent pachymeningitis over the posterior surface of the petrous portion of the left temporal bone, extending from near the internal auditory meatus to the sigmoid groove, which it invaded. The bone beneath was carious and the sigmoid sinus empty. A large abscess was found in the left hemisphere of the cerebellum. GORHAM BACON.

126. In a paper on this subject, after referring to brain abscess as a complication of otitis media, FISHER urged the importance of removing a large area of the skull in cerebral operations, in order that the brain when exposed can be better examined, and also that all possible benefit can be obtained from the relief of the cerebral pressure. He believes that "the removal of a mere button of bone with the trephine certainly exposes the patient to some danger and rarely accomplishes much otherwise."

GORHAM BACON.

127. A boy, aged fourteen years, who had had occasional discharge from the right ear for several years, constant during the last seven months. For six days, pain and swelling behind ear. Very ill. Face flushed, partially comatose, severe pains in head, very giddy, neck slightly stiff on right side. Temperature 101°. Pulse 65. Optic discs congested. Soft red swelling behind ear. Antrum opened, found "only slightly diseased," but attic full of granulations and fetid pus. Pus escaped from basilar groove. Dura mater gray and thickened. Lateral sinus hard and evidently thrombosed. As there were no urgent symptoms and the thrombus was possibly non-septic, BRONNER decided not to open it. Temperature normal on third day. Complete recovery.

CHEATLE.

128. MARSH relates five interesting cases. In three, an abscess was present in the temporo-sphenoidal lobe and recovery took place after operation. In one, meningitis and temporo-sphenoidal abscess were fatal; and in another there was septic thrombosis of the lateral sinus, eight small abscesses, evidently secondary, being found in the white matter after death.

129. GERONZI relates a case where the removal of a polyp from the middle ear was followed by infectious sinus thrombosis, leptomeningitis, and death, and discusses the possibility of a connection between the operative procedure and the development of endocranial complications. GRADENIGO.

130. GRADENIGO gives the various symptoms of a cerebellar abscess. If, in a case of chronic otorrhœa, symptoms of a brain abscess be present, and at operation caries of the sigmoid sulcus, with sinus thrombosis or suppuration in the labyrinth, be found, the presence of a cerebellar abscess is doubtful. Four cases of cerebellar abscess are described in detail, and a case reported where the abscess was supposed to be present, but the diagnosis was not confirmed on exploring the cerebellum and by the subsequent course. GRADENIGO.

131. The report of two fatal cases from the ear clinic at Halle. I. A man, twenty-two years old, right otorrhœa for many years, with pain, furuncle, œdema of the surrounding parts, granulations and fetid pus in the depth, fever, fluctuation behind the ear. Operation. Dura and sinus, covered with granulations, exposed. Later apathy, retarded pulse, headache. On the further appearance of jactation, vomiting, and stupor, the temporal lobe was laid bare and the diagnosticated abscess found. Death five days later, with meningeal and pyæmic symptoms. At autopsy, another abscess and purulent leptomeningitis were found. II. A man, thirty years old, long-standing left otorrhœa and deafness. Pain and general malaise for two weeks, with loss of memory, hesitating speech, amnesic aphasia, and fever. At operation, antrum contained disintegrated cholesteatoma, dura covering the tegmen exposed and found healthy, wall of sinus hyperæmic. Aphasia and apathy increased. Four days later the left temporal lobe exposed and an abscess encountered. Death three days later, with symptoms of meningitis. At autopsy diffuse purulent arachnoiditis, several more foci of disintegration in the brain, and pus in the labyrinth were found. BLOCH.

d.—OTHER MIDDLE-EAR DISEASES.

132. McAULIFFE, GEO. Dilatation and stenosis of the Eustachian tube. *New York Eye and Ear Infirmary Reports*, Jan., 1898.

133. WHITING, FRED. Carcinoma of the mastoid and auricle, originating in the tympanum or antrum, consecutive to chronic suppurative otitis media. *New York Eye and Ear Infirmary Reports*, Jan., 1898.

134. MOURE. The surgical treatment of chronic middle-ear catarrh. *Arch. f. Ohrenh.*, vol. xliv., p. 187.

132. McAULIFFE reports two cases, one of unusual dilatation and the other of stricture of the Eustachian tube. In the former, a successful endeavor was made to narrow the lumen of the tube, by setting up an adhesion or a hyperplastic condition by the application of nitric acid and carbolic acid. In the latter case, catheterization and bougieing were followed by some improvement.

GORHAM BACON.

133. WHITING, after referring to the infrequency of carcinoma of the auricle and mastoid, and the very brief description of the more common physical appearances of the growth usually found in the text-books, reports an interesting case where the growth started in the tympanum and followed chronic suppuration. The growth was very large, and there was extensive caries of the mastoid process and of the osseous auditory canal, with absence of pain until the inflammation extended to the cellular structures. Immediately following the operation, there was entire recession of all inflammatory infiltration of the auricle, face, and neck, but later there was a rapid growth of the fungating granulations in the wound, and the tumor attained a large size. The facial nerve did not become involved until the disease had existed for a long time, and the patient was free from meningitis and sigmoid sinus thrombosis in spite of the fact that all the descending portion of the sinus was exposed to the erosive action of the disease for three months or more. The patient died very suddenly. No autopsy was obtained. GORHAM BACON.

134. MOURE thinks that an operation is justified in sclerosis when the conservative treatment is ineffectual, though only in the cases where a paracentesis of the drum membrane produces a temporary improvement. He then removes the membrane, the hammer, and anvil. Occasionally the tinnitus, or the hearing

alone, is improved ; the results may perhaps only be temporary. Even in that case, an artificial drum may be resorted to.

NERVOUS APPARATUS.

135. HALLOCK, FRANK K. Equilibration and its relation to vertigo. *Jour. of Nerv. and Ment. Dis.*, Feb., 1898.

136. HUTCHINSON, JONATHAN. Doubtful case of congenital syphilis. History of attacks of sudden and quite temporary deafness. Auditory nerve epilepsy. *Archives of Surgery*, Jan., 1898.

137. GRANT, DUNDAS. A case of hysterical nerve deafness, with spontaneous recovery. *Jour. of Laryngol.*, June, 1898.

138. OESCH. What can we hear without the cochlea? *Inaug. Dissert.*, Bâle, 1898.

139. SILVA. Tumor of the posterior cranial fossa. *Bolletina della Societa med.-chir. di Torino*, Pavia, 1897.

135. The chief point of the article is an attempt to show the importance of the relation of the cortical centres to the act of equilibrium. Vertigo, being essentially a psychical phenomenon, may be defined as the consciousness of a disturbance of the body equilibrium. From a purely physiological consideration of equilibration, the act consists of the operation of three sets of factors: first, peripheral end organs with their afferent nerves conducting sensory stimuli ; second, co-ordinating centres receiving these stimuli ; and, third, efferent nerves from these centres conducting motor impulses to the skeletal muscles.

The semicircular canals of the internal ear receive and transmit through the vestibular branch of the auditory nerve, stimuli which indicate the position and balance of the head, and less directly play a part in the precision of movement and general state of equilibrium throughout the body. The author says that while the semicircular canals are undoubtedly a factor of most unique and special character in the act of equilibration, it is still true that their absence or destruction does not prevent the maintenance of the equilibrium. Animals deprived of their canals show marked impairment of their equilibrating power, which is never fully recovered In deaf-mutes and persons who have suffered from destructive lesions of the labyrinth, vertigo is a rare symptom, and cannot be induced experimentally with anything like the frequency that it can in normal individuals. The loss of the

semicircular-canal stimuli is compensated for in great part by the visual and tactile stimuli, but the complex and highly developed acts of equilibration are not possible, and the capacity of the individual to experience vertigo is correspondingly decreased.

GORHAM BACON.

136. A female, aged twenty-six years, with doubtful syphilitic history, suffered with neuralgia and peculiar form of deafness which would come on very suddenly, rendering her stone deaf, and then the hearing would as suddenly return. HUTCHINSON thinks the case syphilitic, and that the attacks of temporary deafness are parallel to so-called "epilepsy of the retina." The idea of the trouble being hysterical does not seem to have arisen.

137. A girl, aged eighteen years, came to DUNDAS GRANT on May 27, 1895, with the history of gradually increasing deafness for three years, the hearing having got much worse after the extraction of some teeth three months before the visit. Only very loud conversation was heard. Watch at six inches. Galton up to mark 3.8. Bone-conduction diminished. Rinne's test positive. Tuning-fork hearing lost for "C_2" and "C"; while for other forks from "C" up to "E^5," the amount of hearing power varied from 3 or 4 up to 15 per cent. Hearing returned after a complication of ailments in January, 1897. CHEATLE.

CHEATLE.

138. The author reviews the opinions on the functions of the cochlea and describes the cases of labyrinth necrosis, with a summary of the accompanying functional examinations. He concludes from these data, including a case observed by Schwendt, that no case exists which proves that man can hear without a cochlea, while many carefully examined cases of almost total necrosis of the cochlea prove the contrary. In one-sided defect of the cochlea the Lucae-Dennert test must be employed.

BRÜHL.

139. A woman, aged twenty-two, was taken ill with vertigo, attacks of unconsciousness, vomiting, right-sided headache, and staggering gait. Later blindness and deafness right, trembling of the upper extremities, dislalia, delirium, right facial paralysis. At autopsy a glio-sarcoma was found underneath the upper cerebellar peduncle and the right restiform body and the right cerebellar hemisphere. The tumor had forced its way into the internal auditory canal, which was twice as large as normal.

GRADENIGO.

NOSE AND NASO-PHARYNX.

a.—GENERAL SYMPTOMATOLOGY AND TREATMENT.

140. ROOT, ELIZA H. Epileptoid seizures apparently due to nasal obstruction. *N. Y. Med. Jour.*, May 21, 1898.

141. ZARNIKO. Cacosmia subjectiva. *Festschrift des ärztlichen Vereins zu Hamburg*, etc., 1897.

142. SEIFERT. On the relation between nasal and ocular disease. *Münchn. med. Wochenschrift*, No. 29, 1898.

140. ROOT's patient, a female, æt. twenty-five, suffered from epileptic attacks for nearly three years, which, of late, had become very frequent and severe, occurring as often as once or twice a week. In the nose a deflected and ulcerated septum was found, and the turbinated bodies, particularly the lower, were enlarged and inflamed. Intranasal adhesions, three in the left and two in the right side, had formed between the septum and inferior turbinated body. Above the bands were small bony protuberances. After the removal of the adhesions the "spells" entirely ceased. M. TOEPLITZ.

141. ZARNIKO relates four cases, and concludes that usually the cacosmia is not subjective but objective; it often depends on empyema of the accessory sinuses (especially of the maxillary antrum), with fetid discharge. The diagnosis should, therefore, only be made after examination of the accessory cavities on the suspected side. He employs Schmidt's canula for diagnostic irrigation of the antrum. BRÜHL.

142. From examinations made at the eye clinic, SEIFERT found a connection with nasal disease in the catarrhal affections, in tuberculosis of the tear passages, in disease of the conjunctiva, and, remarkably, in most cases of ulcus corneæ serpens (rhin. atroph. fœt.). These ocular lesions are due to propagation, while lachrymation, blepharospasm, and ciliary neurosis are reflex disturbances. SCHEIBE.

b.—METHODS OF EXAMINATION AND TREATMENT.

143. ZARNIKO. Miscellanea rhinologica. *Monatsschr. f. Ohrenheilk.*, No. 3, 1898.

144. SCHECH. Reply to the preceding. *Ibid.*, No. 4, 1898.

145. BLÖBAUM. Submucous cauterization with the galvanocaustic needle in the treatment of hypertrophic rhinitis, with de-

scription of an aseptic platinum cautery. *Monatsschr. f. Ohrenkeilk.*, No. 4, 1898.

146. ELLEGOOD, J. A. Another conservative operation for intranasal synechia. *The Laryngoscope*, April, 1898.

143. ZARNIKO pleads for thorough sterilization of all instruments employed in the ear, nose, and throat. After thorough scrubbing with soap and water, all instruments, including the laryngeal mirrors and galvano-cautery apparatus, are boiled in a 1 per cent. soda solution for five minutes. KILLIAN.

144. SCHECH thinks that the mechanical cleansing, with subsequent disinfection with carbolic acid, sublimate, and similar agents, suffices. KILLIAN.

145. BLÖBAUM prefers submucous cauterization, with a burner whose copper wire is fixed by an intermediate piece of ivory, instead of silk thread. The lower turbinate is first anæsthetized with Schleich's mixture No. 2. KILLIAN.

146. ELLEGOOD removes intranasal synechia by surrounding them with a silver wire, which is daily drawn tighter.

TOEPLITZ.

c.—OZÆNA.

147. STEWART, W. R. H. Case of ozæna following removal of inferior turbinate. *Proceedings of the Laryngological Society of London*, March 9, 1898.

147. STEWART'S patient presented herself to him with crust formation in throat and nose, with a considerable amount of fetor, the history being that, in 1893, turbinotomy had been performed for deafness and discharge from the right ear.

d.—NASAL SEPTUM.

148. COOLIDGE, A., Jr. Changes in the turbinated bones in connection with deformities of the septum. *Boston Med. and Surg. Jour.*, June 9, 1898.

148. The turbinated bodies change their shape to correspond with deformities of the septum, tending to maintain slit-shaped channels. In the great majority of deflections of the septum, with or without spurs, the turbinates opposite the convexity recede, while they advance on the concave side. The hypertrophy or atrophy of a turbinated body must be judged, not from its actual size, but from the width of the air-passage. The removal of the hypertrophy is not indicated if opposite a convex

septum, and it is better nasal surgery to operate on the septum. COOLIDGE, in conclusion, appends a case of congenital bony occlusion of the right choana, which was opened with the trephine. M. TOEPLITZ.

e.—DISEASES OF THE ACCESSORY CAVITIES.

149. MILLIGAN, W. The etiology and treatment of suppurative disease of the frontal sinuses. *Lancet*, Feb. 19, 1898.

150. WINGRAVE, WYATT. Microscopical section of lymphoid tissue removed from frontal sinus. *Proceedings of the Laryngological Society of London*, April 13, 1898.

151. DE SANTI, P. Ivory exostosis of frontal sinus, causing pressure symptoms. *Proceedings of the Laryngological Society of London*, March 9, 1898.

152. TURNER, A. LOGAN. On the illumination of the air sinuses of the skull, with some observations upon the surgical anatomy of the frontal sinus. *Edinburgh Med. Jour.*, April and May, 1898.

153. STETTER. Experience in the field of ear, nose, and mouth disease. *Monatssch. f. Ohrenheilk.*, No. 25, 1898.

154. SCHECH. On the pathology of caries of the sphenoid. *Münch. med. Wochenschr.*, No. 27, 1898.

149. A useful résumé of this subject. MILLIGAN advocates median incision when opening is required, and Kuhnt's method of treating the lining membrane. Fifteen cases are related in all; with the exception of a subacute case, other sinuses were also involved. CHEATLE.

150. WINGRAVE's sections of tissue, removed from the frontal sinus by Dundas Grant, showed small cell or lymphoid structure, containing nodules similar to adenoid growth.

151. DE SANTI showed a man suffering from an ivory exostosis involving the right frontal sinus, and which had by pressure caused a suppurating mucocele. The exostosis had been present for five years, but beyond the disfigurement, he had not been troubled until ten days before coming under observation, when the parts at the inner canthus of the eye began to swell and cause pain. CHEATLE.

152. In dealing with the illumination of the maxillary antra, ethmoidal cells, and frontal sinuses, TURNER conducted his observations along three lines :

(i.) Examination of skulls.
(ii.) Examination of presumably healthy individuals.
(iii.) Examination in cases of disease.

The paper is an instructive one and deserves careful study. He points out the inequality of the transmission of light through healthy *antra*. Out of twenty-four skulls examined, only nine illuminated equally on both sides. This inequality is due to anatomical variations, in healthy conditions, but may be artificially produced by not placing the light accurately in the middle line. In diseased conditions of the interior of the nose, such as ethmoidal disease, polypi, or other cause of obstruction, the subjective sensation of light is diminished on the obstructed side, and the cheek illumination is hardly so bright. He relates a case of undoubted unilateral *ethmoidal disease*, in which the nasal bone on the same side was in shadow, while the one on the opposite side was illuminated brightly. In examining for illumination of the nasal bones in connection with the subject of ethmoidal disease, greater variations were observed in healthy individuals than in the antra. In illuminating the *frontal sinus*, a short tube made of rubber, bone, or ivory is fitted over the light, the tube projecting slightly. The open end of the tube should be applied to the floor of the sinus, a short distance above, and slightly external to, the inner canthus of the eye. He points out that the floor is very thin over a certain area, around which the bone is thicker. This thin area lies below the supra-orbital margin, and occupies mainly the inner segment of the orbital roof. He has measured the distance of the inner margin of this thin area from the middle line of the nose at its root, and finds it on the average to be 17 *mm*. The inner edge of the tube should therefore not be placed nearer the middle line than this, if it be desired to obtain the full benefit of this thin area. The lamp should be placed well under the supra-orbital margin. If the eyeball is turned downwards a little more space is obtained.

With regard to the value of transillumination of this sinus, from the point of view of diagnosis, he considers it to be comparatively small, but from the point of view of treatment it may be more, for if the sinus does illuminate, it is possible to define its limits both vertically and horizontally, and at the same time the position of the septum can be mapped out, and its relation to the middle line. An interesting account is given of the variation in the size of the cavity, and position of the septum. The *mastoid cells* he illumi-

nated by means of a powerful light (five-candle lamp) placed on the mastoid, while a speculum was introduced into the meatus, but the results upon living persons did not prove satisfactory; at the best, both in skulls and in the living, only the most superficial of the mastoid cells were lit up. ARTHUR CHEATLE.

153. STETTER operates on the maxillary antrum from the face, with a line of incision similar to Dieffenbach for resection of the superior maxilla, without cutting through the upper lip. This is a singular procedure, as it is well known that the lower half of the facial side of the antrum can be best reached from the mouth.

KILLIAN.

154. Chronic suppurative catarrh of the sphenoidal cavity is by far not so dangerous as the carious processes. The latter are usually dyscrasic, and occur especially in syphilis and in tumors. Therapeutic measures should be cautiously attempted. Three cases are reported. SCHEIBE.

f.—NEW GROWTHS.

155. YEARSLEY, MACLEOD. Papilloma of the septum nasi. *Proc. Laryng. Soc. of London*, April 13, 1898.

156. ORO. Two cases of rhinoscleroma. *Giornale ital. delle malattie veneree e della pelle*, 31st year, No. 2.

157. HEERMANN. Two cases of rhinoscleroma in Germany. *Deutsche medic. Wochenschr.*, No. 22, 1898.

158. BRAULT. Malignant tumor of the naso-pharynx in a small child of three and a half years. *Ann. des mal. de l'or., du lar.*, xxiv., No. 5.

159. NEWMAN, DAVID. Naso-pharyngeal papilloma. *Proceedings of the Laryngological Society of London*, March 9, 1898.

160. MILLIGAN, W. A case of foreign body in the naso-pharynx. *Jour. of Laryng.*, June, 1898.

155. YEARSLEY removed a papilloma from the cartilaginous septum of a patient twenty-six years old, about three-quarters of an inch inside the vestibule.

156. ORO comes to the following conclusions: Rhinoscleroma may be found in isolated foci throughout the upper respiratory tract; the disease is a specific granuloma; the bacillus of Frisch is the pathogenic agent, and that it best be named infectious scleroma of the upper air-passages. GRADENIGO.

157. HEERMANN describes two cases of scleroma confirmed

by bacteriological examination. Both patients were females, and one came from East Prussia and the other from Silesia, both regions where this disease is not endemic. In the first case, the affection remained localized for a long time to the anterior part of the nose, and extended later to the naso-pharynx. The second patient presented a mixed form, a large subglottic tumor and cicatricial changes in the naso-pharynx, while in the anterior part of the nose a fresh eruption in the form of soft tumors, the size of coffee beans, had taken place. NOLTENIUS.

158. In this case, obstructed nasal respiration, dysphagia, and dyspnœa were present during the last three months. A large tumor occupied the pharynx, entered into both nasal cavities, and had caused the right cheek and eyeball to protrude. BRAULT did not consider the case to be a fibroma of the naso-pharynx, and regarded it as a sarcoma originating in the pharyngeal tonsil. In chloroform narcosis, after preliminary tracheotomy and section of the soft palate, the growth was removed with a forceps, and the nose and naso-pharynx were curetted. The child was discharged in a week. Nothing is stated about the subsequent history. The microscopic examination of the tumor showed in places a fibro-myxomatous structure, in others that of a round-celled sarcoma with connective-tissue stroma. ZIMMERMANN.

159. NEWMAN showed a very large papilloma, the size of a hen's egg, which he had removed from the naso-pharynx of a young man.

160. A boy, aged three years, "swallowed a marble." A few hours later, on examining the throat, the soft palate was seen to be slightly bulged forwards, and to be somewhat tense. Under chloroform the marble was found to be firmly wedged between the septum and post-pharyngeal wall.

g.—OTHER DISEASES OF THE NOSE.

161. CHAPMAN, GEO. L. Rhinitis fibrinosa. *Medical News*, April 30, 1898.

162. KELLY, A. BROWN. Cysts of the floor of the nose. *Jour. of Laryng.*, June, 1898.

163. ANNANDALE, THOMAS. Practical suggestions in connection with the treatment of some deformities of the nose. *Brit. Med. Jour.*, Dec. 4, 1897.

164. OETTINGER. A case of heredito-syphilitic saddle-shaped nose. *Münch. medic. Wochenschr.*, No. 24, 1898.

165. GUYE. The plica vestibuli and the aspiration of nasal alæ. *Münch. medic. Wochenschr.*, No. 26, 1898.

166. SAENGER. Subjective dyspnœa in dryness of the mucous membrane of the nose and throat. *Münch. medic. Wochenschr.*, No. 15, 1898.

167. JAGONI, C. A. Certain rare diseases of the floor of the nose. *Arch. ital. di Otol.*, vol. vi., p. 63.

168. RETHI. Treatment of polypoid rhinitis. *Wien. klin. Wochenschr.*, No. 18, 1898.

161. After a careful synopsis of all former investigations upon the subject, CHAPMAN gives three full clinical reports, one of a boy aged six, and the other two of boys aged ten. In all cases the staphylococcus was found. M. TOEPLITZ.

162. KELLY relates three cases, all in females. Situated, in each case, at the anterior end just behind the junction of the skin and mucous membrane. In two, puncture alone produced a cure. In the third, dissecting out was necessary. Kelly also deals with the development of this part of the nose in connection with this cyst formation.

163. In order to keep in proper position the nasal bones and other nasal structures in cases of recent comminuted and depressed fracture, and also after operation for the relief of deformity, the result of old-standing injury or disease, ANNANDALE, after raising the structures to their proper position, "slings" them in the following way: A piece of sheet lead is formed into an arch with a ledge upon each side which rests on the cheeks; the arch being made higher than the nasal bones when they are brought into proper position. A sharp steel pin is then passed through the base of the nose from side to side, at the point which seems best for support, a notch being cut in the leaden arch on each side for its introduction; a piece of silver wire is then passed round each end of the pin and over the arch. A movable nut on the point of the pin is screwed home until the proper amount of lateral pressure to assist in moulding and keeping the nose in good position is obtained. A small cap is then screwed onto the point of the pin to prevent injury to the cheek.

In cases of old-standing depression, he first exposes the anterior nares by turning up the upper lip after dividing the mucous membrane; he then introduces a pair of small bone forceps and separates the nasal bones from their connection with the superior maxillæ, in some cases nipping across the nasal processes of the

superior maxillæ, so as to use them also in forming a firmer nasal support; the case is then treated in the manner above described.

A plastic operation in order to cover over an ugly opening, resulting from the loss of the entire nose and surrounding textures of the cheek, is also described. A flap is cut from the forehead and left attached at its upper end; another is cut from the upper lip terminating a little above the coronary artery. The edges of the opening are then pared, and the two flaps having been separated from their attachments, except at their bases, are brought together and stitched over the opening. The centre of the upper lip is thus considerably raised; but when the circulation has been thoroughly established, a second operation, as in hare-lip, is performed to bring the edges of the drawn-up portion into apposition. The paper is illustrated. ARTHUR CHEATLE.

165. GUYE recommends in place of the Schmidt-Feldbausch instrument, a rubber ring which is to be inserted in the anterior nares. According to Bolk, man is the only animal that has hairs in the nasal vestibule. SCHEIBE.

166. The dyspnœa disappeared after the improvement of the dry rhinitis. SCHEIBE.

167. JAGONI reports four cases. The first was a large cyst in the hard palate on the right side, presumably originating from a tooth. The floor of the nose fluctuated. The second case showed caries of the floor of the nose; the third was an abscess, and the fourth a hematoma. According to the author, hematoma has not been previously reported in this locality.

GRADENIGO.

168. Insufflation, painting, and cauterization do not accomplish much. Removal of isolated hypertrophy of the ends of the turbinates is sufficient, but if the middle is also involved, some of the mucous membrane, and even some of the bone, should be removed. He employed Hartmann's scissors. Gauze is inserted after the operation and remains for two days. Severe complications were not met with. POLLAK.

h.—PHARYNGEAL TONSIL.

168A. CHAPPELL, WALTER F. Forceps and curette for the removal of adenoids. *N. Y. Med. Rec.*, April 16, 1898.

169. MCCAW, J. F. Adenoid vegetations. *N. Y. Med. Journ.*, April 30, 1898.

170. PREBLE, WALLACE. Secondary hemorrhage following the removal of adenoid vegetations. *Boston Med. and Surg. Journ.*, May 19, 1898.

171. FARLOW, JOHN W. On some forms of adenoid disease which are often overlooked, and on conditions which may simulate adenoid disease. *Boston Med. and Surg. Journ.*, April 21, 1898.

172. Post-nasal adenoids. Operation. Death under anæsthetic. *Lancet*, June 25, 1898.

173. SMITH, EUSTACE. Adenoid vegetations and laryngeal stridor. *Lancet*, March 19, 1898.

174. ZIMMERMANN. Etiology of pseudo-croup. *Münch. medic. Wochenschr.*, No. 29, 1898.

175. JORDAN, MAX. The operative removal of fibromata of the base of the skull. *Münch. medic. Wochenschr.*, No. 21, 1898.

176. HOPMANN. The operation for hard fibroma of the base of the skull, with remarks on nasal polypi. *Ibid.*, No. 21, 1898.

168A. The size of the instruments used should be based upon actual measurements of the naso-pharynx at different ages. CHAPPELL prefers the curette, on account of its sweeping antero-posterior movement, which can be rapidly executed without an anæsthetic. The blade should be narrow, the width of the fenestra near the shaft half the size of the blade. The cutting edge may be coarsely serrated. M. TOEPLITZ.

169. MCCAW selects three cases from his records, in order to demonstrate how many different conditions can be cured by the removal of the growth. In the first case a severe bronchitis and "bilious attacks," in the second a condition of croup or asthma, and in the third muscular twitchings (reflex neuroses) and impaired cerebration were successfully operated upon.

170. On the seventh day after the removal of a moderate growth of adenoids under ether in a girl, aged eleven, a sudden hemorrhage occurred, which was stopped by cold syringing. Six and a half hours later, another bleeding was controlled by posterior plugging, but after twelve hours a sudden gush of blood ended the life. There was no history of bleeder, but the blood of the first bleeding was only partly clotted. PREBLE enumerates twenty-one cases of such hemorrhages taken from the literature of the last ten years. True secondary hemorrhage, several days after operation, occurred only in five cases, three French and two Danish. M. TOEPLITZ.

171. Adenoids may often exist without producing mouth-breathing, and the latter may be caused by other conditions than adenoids. The so-called catarrhal adenoids in older children represent the first condition, in which the growth, although comparatively small, requires eradication for other symptoms than mouth-breathing. The conditions which, apart from adenoids, may cause mouth-breathing, are as follows: deviations, spurs and ridges of the septum, relaxation of the alæ, catarrhal secretions, chronic eczema of the anterior nares, extreme narrowness of nasal passages, anterior and posterior hypertrophy of turbinates, congenital occlusion of the posterior nares, swelling of posterior end of vomer, retro-nasal fibromata, posterior polypi, narrowness of the naso-pharynx, small distance of soft palate from posterior pharyngeal wall, high-arched, hard palate with protruding incisors, extreme size of tongue, specific rhinitis and pharyngitis with adhesions. M. TOEPLITZ.

172. In a note the *Lancet* records the case of a child, aged ten years, who was given chloroform for the removal of adenoids in the Birmingham General Hospital by an experienced anæsthetist. The child was recovering from the anæsthetic at the time of the operation, which was rapidly performed. Death was believed to be due to shock reacting upon a nervous system incompletely protected by full anæsthesia. Respiration was noticed for one and a half minutes after the circulation had become imperceptible. CHEATLE.

173. A case of congenital laryngeal crowing, of a marked type, ceased within a few days of the removal of post-nasal growths. EUSTACE SMITH attributes the stridor to a spasmodic contraction of the ary-epiglottic folds, and believes this was due to irritation set up by the adenoids. CHEATLE.

174. According to ZIMMERMANN, there is a connection between adenoids and pseudo-croup, for on the removal of the former the attacks of pseudo-croup ceased. The author has operated on six of eleven cases, and in only one case (a child three and a half years old) a short attack was noticed a week later. H.

175. JORDAN recommends the combined nasal and upper-jaw retraction method for exposure of the field of operation, and removes the tumor with the periosteum in all cases where the radical operation is indicated. He reports two successful cases healed without deformity. SCHEIBE.

176. With aid of the velitractor the soft palate is pulled for-

ward, and under guidance of the finger the tumor is shelled out and removed with the forceps, snare, or sharp spoon. The operation is performed in full narcosis with overhanging head. Good results. SCHEIBE.

SOFT PALATE, PHARYNGEAL AND BUCCAL CAVITIES.

177. LINCOLN, R. P. On pharyngeal mycosis. *Medical News*, April 30, 1898.

178. TOEPLITZ, MAX. Mycosis pharyngis leptothricia. *N. Y. Med. Journ.*, June 25, 1898.

179. HELSHAM, W. M. A case of absence of soft palate, and cleft tongue; congenital. *Australasian Med. Gazette*, April 20, 1898.

180. DOWNIE, WALKER. Operation for primary epithelioma of the uvula. *Glasgow Med. Jour.*, Feb., 1898.

181. LACK, LAMBERT. On lupus of the pharynx and larynx; treatment. April 28, 1898.

182. BLOCH. The etiology of rheumatism. *Münch. medic. Wochenschr.*, Nos. 15 and 16, 1898.

183. JESSEN. The tonsils as entrance for severe general infections. *Münch. medic. Wochenschr.*, No. 23, 1898.

184. AVELLIS. Clonic spasm of the palatal muscles, with noise in the ear, etc. *Münch. medic. Wochenschr.*, No. 17, 1898.

185. ROSENBERG, A. Pharyngeal communications. *Berliner klin. Wochenschr.*, No. 18, 1898.

177. LINCOLN has seen three cases, two in males and one in a female, which he describes. For treatment he uses the galvanocautery and pyoctanin powder rubbed into the parts.

M. TOEPLITZ.

178. After a brief description of the benign mycotic affections of the oral pharyngeal cavities, TOEPLITZ describes two forms of mycosis leptothricia, a diffuse and circumscribed form; the latter is then fully and elaborately dwelt upon. He gives extensive reports of three cases of his own observation, the third associated with phthisis pulmonum. The affection can be well differentiated from diphtheria, acute follicular and chronic follicular tonsillitis, and tonsillar concretions. The history of the disease and the literature upon the subject are carefully reviewed. The bacteriology, pathological anatomy, and culture experiments are fully discussed. The contrary views of Siebenmann and his followers, that the

affection is due to transformation of the lacunæ epithelium into horny matter with leptothrix threads upon the freely prominent cones, are also explained. The paper concludes with a complete bibliography.

179. An infant two days old was unable to suck, and fluids returned through nose. HELSHAM found complete absence of the soft palate, its position being represented by a large oval, window-shaped opening, through which the roof of the naso-pharynx with the projecting vomer could be seen. The free edge of the opening was attached by a fold, on either side, in front of the tonsil, to the lower jaw, behind the position of the last molar tooth. The tongue was completely divided, from behind forward to the extreme tip, where the two parts were united and anchored short behind the gums. On crying, the two halves rose in two ridges, almost meeting along their free border; otherwise there was little or no movement in the organ; the father was a Japanese, the mother an Australian. ARTHUR CHEATLE.

180. DOWNIE removed the uvula, on which was an epitheliomatous ulcer, from a man aged fifty-six, who had had difficulty of swallowing for two months and pain for a few days. There was no glandular enlargement. Downie states this to be only the second case recorded. CHEATLE.

181. LACK draws attention to the curative action of arsenic given internally, without local treatment, for lupus of the pharynx and larynx, and regards other means of treatment as seemingly superfluous. With regard to lupus of the nose, arsenic has not the same efficacy, local treatment being also necessary. Cases are related. Lack states: "No satisfactory explanation has yet been given of the fact that lupus of the throat differs so remarkably from other forms of tubercular disease of the same region and affecting the same tissues, although the affections are histologically and, as far as we can judge, etiologically identical. The administration of arsenic seems to still differentiate these affections, apparently curing one and having no influence on or acting adversely in the other. Further, we find that arsenic is most beneficial in lupus of the pharynx and larynx, less so in lupus of the nose, and, as far as my limited experience goes, without appreciable influence on lupus of the skin." ARTHUR CHEATLE.

182. This paper treats of the relation of rheumatism to pyæmia and its connection with angina and other primary suppurative foci. BLOCH relates thirteen cases where rheumatism appeared in

the course of a chronic middle-ear suppuration. We do not think that many will agree with him in regarding the otorrhœa as an etiological factor. SCHEIBE.

183. Four cases are described where a severe septic inflammation or a pneumonia took its beginning through the tonsils, which was verified by the bacteriological examination. SCHEIBE.

184. After the first section, the noise ceased for ten days and then recurred, to continue uninterruptedly notwithstanding further operations. The affection is a symptom of general nervousness. SCHEIBE.

185. ROSENBERG'S patient was a man of forty years, with whitish patches on the tonsils, anterior pillars of the fauces, uvula, and soft palate, who complained of an uncomfortable sensation in the pharynx and slight dysphagia. Rosenberg gives the name non-specific leucoplacia of the pharynx to this condition, as it surely was not of syphilitic or mycotic origin. The discolored patches were raised, surrounded by an inflammatory zone, and could not be removed with the curette. The author believes that this is a case of thickening and superficial cornification of the epithelium. Recovery took place after application of chromic acid. Two cases of pharyngeal hemorrhage are also reported; in one the bleeding came from a tonsillar crypt, and in the other from a varicose vein on the posterior pharyngeal wall. MÜLLER.

REPORT OF THE TRANSACTIONS OF THE SECTION ON OPHTHALMOLOGY AND OTOLOGY OF THE NEW YORK ACADEMY OF MEDICINE.

By Dr. W. B. MARPLE, Secretary.

OTOLOGICAL MEETING OF NOVEMBER 21, 1898.

The President, Dr. E. Gruening, in the chair.

Dr. E. Gruening presented a patient with **Extensive Suppuration in the Mastoid and Surroundings, which had Developed after the Perforation of the Drum Membrane in Acute Otitis Media had Closed, and the Patient Appeared Cured.**

"The patient whom I present here to-night came to my office in the latter part of September. His right cheek and the retro-maxillary region were swollen, and the tip of the mastoid and an extensive post-mastoid area were tender. The drumhead was whole, and with the right ear the patient heard the watch at three inches (audibility of watch twenty-four inches), and would follow ordinary conversation. He stated that in June last the ear had been painful, and was lanced by an aurist. It discharged about two weeks, and after that time the patient thought his ear was well. At the operation performed at the Mt. Sinai Hospital, October 1st, abscesses were found in the digastric fossa, under the parotid gland, in the substance of the sterno-cleido-mastoid muscle, and around the lateral sinus. The tip of the mastoid was carious.—The case demonstrates that in cases of purulent otitis media the perforation in the membrana tympani may close and the patient appear improved, while the process of destruction continues in the direction of the lateral sinus and the tip of the mastoid."

Dr. H. Knapp, in commenting on the gravity of these cases

and the extension of the suppurative process in the case of the President, so thoroughly and successfully dealt with by the operation, begged to be excused for calling attention to a former case of his own in which the autopsy had revealed a small hole in the medial wall of the tip, an epidural abscess and meningitis in the posterior cranial fossa, and a perforation in the roof of the digastric fossa, which, by the liberation of pus in the cranium, had caused a sudden disappearance of a three days' comatose condition, to be followed, after a day's well-being, by death.

Dr. ARNOLD H. KNAPP presented a patient with a **Bezold's Mastoiditis without Perforation of the Drum Membrane, with Recovery after Operation.** The patient was twenty-two years old, and had suffered from tinnitus and deafness for three months. The symptoms of a Bezold's perforation of the mastoid then suddenly appeared, while the middle ear and the drum membrane had never exhibited any acute inflammatory symptoms. Recovery after removal of entire mastoid. (Detailed report to appear in the ARCHIVES OF OTOLOGY.)

Dr. FREDERICK WHITING read a paper entitled **A Contribution to the Clinical Stages and to the Technique of the Operation for Sinus Thrombosis.** (Published in this number of these ARCHIVES.)

Discussion.—Dr. ROBT. ABBE said "that the procedure had been greatly advanced, and many cases had undoubtedly been saved by beautiful technique. He has operated upon many of these cases; upon more formerly before the specialist had absorbed the field. He has had some bad cases, and has noted with pleasure and profit the points made by Dr. Whiting. His operative rule now is to investigate every possible source of infection in the mastoid area from the attic cells to the jugular. Immediately after the appearance of Ballance's paper he was inspired to make an initial ligation of the jugular. This did not always save the bad cases. Then his ardor abated and he often did less, relying simply upon reaching pus, but secondary operations became more frequently necessary, and the second operations were the ones he found so frequently fatal. Do everything necessary, survey the whole field, at the first operation! Clean out the mastoid area, and take away enough bone to expose possible deeper trouble. Dr. Abbe had not observed the shock spoken of by the other gentlemen unless much blood had been lost. Shock is largely a question of hemorrhage. Possibly the jarring of the

skull may also be a small factor, but the principal cause is hemorrhage, and in this situation the latter can be controlled so readily as to make it ordinarily slight. It is important to get at the deepest pus foci. If the bony wall is not sufficiently exposed, cut away the mastoid, reach the digastric groove, and, if necessary, lay open the sinus. Otherwise the case does badly, and a second operation becomes necessary. Often in washing out the jugular a clot which was not removed from the bulb interferes with efficient irrigation. He has lost cases where such a clot had escaped his curetting. The symptoms of chronic mastoid pyæmia are interesting, especially when they simulate malaria. The cessation of discharge, with simultaneous onset of headaches, is a very important symptom. He himself has never felt the cord-like jugular in chronic cases referred to by others. According to his experience, the corded appearance and feeling have always been glandular. If he finds in these cases a chain of glands along the internal jugular, he regards this as evidence that the vein is thrombosed. One point in Dr. Whiting's paper he can hardly approve of, and that is the *milking out* of the sinus, as there is a risk of discharging infective material into other venous channels. He would regard it as unsurgical, when the jugular had not been ligated, thus to roughly handle the infected vein in its lower portion. In several cases which he had seen the delicate barrier of intravenous lymph or septic clot confining the putrid contents of the sinus could easily have been broken down by rough handling."

Dr. B. Alex. Randall, of Philadelphia, characterized the paper as masterly and leaving little room for criticism, since most of the doubts and disputed points had been well canvassed and the grounds of the advanced position fully substantiated. But we are not all in such command of the subject, and Dr. Whiting's rather masterful tone might make it seem simpler to others than they are likely to find it. Sinus thrombosis is not always easy of diagnosis, especially if brain abscess or other cause of pressure reverse the usual high temperature and rapid pulse, while rigor or other characteristics are lacking. He did not believe that he had often failed to recognize cases or to give them needed relief, although he had been less radical than the essayist. We should not go farther nor faster than we see our way, but could and should prepare ourselves to follow this admirable lead; and he would endeavor to profit by the many valuable and to him new

points brought out by Dr. Whiting. Shock will always be a most serious drawback to the radical interventions, and the importance of saline injection or transfusion may well be reiterated, if our patients are to survive after most logical diagnosis and ideal operation.

Dr. C. J. KIPP said that he could add little. In regard to his report in reference to the ophthalmoscopic signs, referred to by Dr. Whiting, he would say, however, that those observations were made previous to 1885. In subsequent observations he has found optic neuritis present in fifty per cent. of the cases. But it is not of great diagnostic importance as between abscess of the brain, meningitis, and thrombosis. As to the technique he can add little. For himself he often finds it difficult, if not impossible, to make the diagnosis between brain abscess, meningitis, and thrombosis. He recently operated on a case where all the symptoms of sinus thrombosis were present, but found a perisinuous abscess. Patient was very feeble, condition bad. So he stopped the operation. The symptoms continuing, he concluded to open the sinus, but before doing this made a lumbar puncture, and found pus cells in the fluid withdrawn, and consequently decided against further operation. Patient died of meningitis. Possibly lumbar puncture might be resorted to more frequently to advantage, as the procedure, when carefully done, is innocuous. Our patients die sometimes from shock, sometimes from hemorrhage. He thinks the transfusion of hot saline solutions of great value. Unless the symptoms point pretty unmistakably to a thrombus, he is doubtful whether we should proceed so far as to open the sinus.

Dr. GORHAM BACON remarked that there was little to be added to what Dr. Whiting had already said. He wished, however, to emphasize, first, the importance of an early operation. In a case of sinus thrombosis seen a year ago, the operation was performed one week after the onset of the acute otitis media. Recovery followed, undoubtedly because the operation was done so early. Another case was operated upon recently after the inflammation of the middle ear had been going on three weeks. There was thrombosis of the sinus and internal jugular, and the patient died. Microscopic examination of the pus from the internal jugular vein showed streptococcus alone. It is, second, important to find out early (microscopically) whether streptococci are present in the discharge from the ear. They are often found, and are destructive. It is, therefore, advisable to determine, as soon as

possible, the bacteriological nature of the infection. He wanted to indorse, furthermore, what Dr. Whiting had said of the value of the transfusion of the normal saline solution. In his last case, after transfusion and lowering of the head, the condition of the patient very promptly improved, and, without doubt, by this means the patient's life was prolonged for a week. The patient died of a leptomeningitis, which he probably had very early in the disease.

Dr. J. E. SHEPPARD said that he esteemed it a privilege to listen to such a paper. His own experience with this condition is somewhat limited. An important point is whether to ligate or not the jugular vein. Most recent statistics show that there is the largest percentage of recoveries where the vein is tied before any other operative procedures are resorted to. He had had a case where symptoms of sinus thrombosis had developed a week after the ear trouble. Temperature, 105° (with chills), which was thought to be due to malaria. Patient seen the third day after the first chill. He made the probable diagnosis of sinus thrombosis from the chills and alternating high and low temperatures. No other symptoms. Eye ground normal. Ear discharging moderately. Slight evidence of mastoid trouble. No tenderness over the jugular vein, though there was tenderness over the mastoid emissary vein. Operation undertaken the next day, and sinus exposed. The case was seen also by Dr. Gruening, and they could not be sure that a thrombus was present, though there was a perisinuous abscess. They waited three days. The symptoms continued. He then evacuated the sinus. Ten days after, rigors reappeared, with choked disc on the affected side. These were the only additional symptoms. The jugular vein was then tied off and removed; pus was found in the bulb. The sinus was exposed back to the torcular, showing an infected thrombus. The case recovered without any metastatic abscesses. His experience leads him to approve of previous ligation of the jugular, which he will always do in these cases. He asked whether it might not be possible that the high fever was due to the absorption of toxines in the second stage, and to bacterial invasion in the third stage.

Dr. HOWARD LILIENTHAL, referring to a point mentioned by Dr. Sheppard, emphasized the importance of ligating the jugular, more especially in cases which have reached Dr. Whiting's second or third stage of the disease. From experience in two cases where he had been called to ligate the vein he believed that this

procedure should be the first step of every operation done in the second or third stage of the infection, while it might be omitted in operations during the first stage. The ligation of the vessel should *precede* any chiselling of bone or any palpation of the sinus or the soft parts about it, so that in the event of the dislodging of septic matter from the thrombus during the necessary operative manipulations the door of entrance to the circulation might be closed in advance. The ligation was not a bloody operation and would usually cause but little shock.

In closing the discussion, Dr. WHITING said: "In response to Dr. Abbe's criticism upon the danger of detaching loosely adherent particles from the wall of the sinus in the 'expression experiment,' I do not regard it as significant for the reason that the manœuvre is designed to detect the presence of a clot at the bulb or in the upper portion of the internal jugular and when *correctly performed* does not increase the pressure at these points; the stripping movement along the vein is always made *away from the bulb* and *toward the torcular* over a section of the sinus which, as the operator has already assured himself, is free of obstruction; the probability of the procedure as thus executed conducing to the dangers of the distribution of infective material must be regarded as remote."

Paper by Dr. HERMAN KNAPP: **Two Cases of Otogenous Pyæmia. The One Fatal. Autopsy. The Other Ending in Recovery.** On account of the late hour Dr. K. mentioned only briefly the most important features of the cases. In the first, death was caused by metastases in the lungs, which had been present when the patient came under his care. On opening the sigmoid sinus, hemorrhage from above, not from below. No abnormity along the internal jugular. At the autopsy an occluding septic clot was found; the internal jugular was empty and so much contracted that it was difficult to detect and recognize it.

The second case had metastases in many joints. The patient was operated on several times. At the last time a septic clot of 1¼ inch of the transverse portion of the lateral sinus was removed. The patient collapsed so alarmingly that one litre of salt solution was injected into a vein of the arm. The patient had to be hurried to his bed and stimulated for several hours. He made a good recovery. The last operation, during the speaker's absence, had been made by Arnold H. Knapp. (The paper will appear in the February, 1899, number of the ARCHIVES OF OTOLOGY.)

Adjourned.

BOOK REVIEW.

A Manual of Otology. By GORHAM BACON, A.M., M.D., Professor of Otology in Cornell University Medical College, New York. With an Introductory Chapter by CLARENCE J. BLAKE, M.D., Professor of Otology in the Harvard Medical School, Boston. In one handsome 12mo. volume of 400 pages, with 109 engravings and 1 colored plate. Cloth, $2.00 *net*. Lea Brothers & Co., Publishers, Philadelphia and New York.

Lea Brothers send for review a new text-book, under the title: Bacon and Blake on the Ear. At the first glance this title seems to be a misnomer, all that is written by the pen of Dr. Blake being very appropriate introductory remarks, of three pages, on the importance and the study of otology. When, however, we read the book all through, we find the dual authorship well sustained, the first half reflecting Dr. Blake's practice, commended and endorsed, in very numerous places. The opportunity of seeing Dr. Blake at his work, and discussing many points with him, is gratefully acknowledged by the author in the last sentence of the preface of his book: "In the preparation of this Manual I am greatly indebted to the kind assistance of my friend and colleague, Dr. Cl. J. Blake, of Boston."

The second half of the text-book, the purulent affections of the middle ear, the diseases of the mastoid and their intracranial complications, bears the original stamp of the author; the discussion is based on his own observations, and the description illustrated by numerous typical cases from his own practice, with many well-executed original drawings. It will be difficult to find so large an amount of practical information expressed in so clear and impressive language. The happy narrative style, remaining easy in spite of all its condensation, contrasts favorably with some long-winded text-books of continental European

authors. Particularly instructive are the chapters on caries and necrosis of the temporal bone, the diseases of the mastoid, intracranial abscess and sinus thrombosis, where the descriptions of the symptoms, the indications and the technique of the operations, clearly show that the author draws on a large stock of personal experience.

Passing the different parts of the book in review, some remarks suggest themselves. The anatomical introduction, a condensation of the corresponding chapters of Gray's anatomy and the fundamental treatise of Politzer into fifty pages, will be welcome to the student and practitioner. The physiology of the hearing organ, one page and a half, is too meagre, even for the least ambitious scholar. Otology receives a peculiar charm through the wonderful laws of sound and the physiological position of the second of the higher senses. That these laws govern important practical applications in diagnosis and treatment is clear from the interest taken in the investigations of Bezold, Stanislas v. Stein, Barth, Blake, and others.

In the methods of examination, p. 88, it is stated: "The rays of light, striking the head-mirror at an angle of 45°, should be reflected into the ear canal." This is not the best arrangement. As in ophthalmoscopy, so in otoscopy the rays of light should fall upon, and be reflected from, the mirror as nearly vertically as possible. This gives the best illumination and the sharpest image, especially when, as in ophthalmoscopy, auxiliary lenses are used behind the sight-hole of the mirror, be it for magnifying or correcting purposes.

Page 60: "The speculum should be held by the thumb and index finger of the left hand, . . . while the auricle, held between the index and middle fingers of the same hand, should be drawn upward," etc. The reviewer has been taught to hold the speculum and the ear in the following way: When the light is on the *right* side of the surgeon, the speculum should be held by the thumb and index finger, and the auricle moved by the middle and ring fingers of the *left* hand; when the light is on the *left* side of the surgeon, the speculum should be held and moved with the *right* hand in the same way as before with the left. In the former case the mirror should be before the surgeon's right eye, in the latter before his left, and the surgeon should rather keep both his eyes open than shut the one not looking through the sight-hole. This technique, somewhat inconvenient at first, but soon learned, gives

much greater play and steadiness to the speculum than when the latter is handled in the manner described in the author's manual.

Page 71 : "The Politzer bag should hold about eight ounces." A twelve-ounce bag is more efficient.

Page 145 (acute purulent ot. med.) : The author is a warm advocate of incising the drum membrane. The reviewer, while likewise acknowledging the benefit of this little operation, is of the opinion that paracentesis can be overdone. The author supports his opinion by a case of scarlet-fever otitis media. "The left ear subsequently became inflamed and painful, when a free incision was made in the drumhead, with the result that the left membrana tymp. subsequently healed and the hearing on this side became normal, while in the right ear, in which the perforation had taken place spontaneously, most of the drumhead was destroyed." Apart from the fact that a single case furnishes an argument of little weight, it seems the rule that of dual organs the one first affected with acute infective disease stands a poorer chance than the other. In gonorrhœal ophthalmia, for instance, this fact is undisputed.

In the treatment of circumscribed otitis externa (furunculosis), page 103, a galaxy of local and general remedies are recommended: the artificial leech, Leiter's coil, early and free incision, conical carbolized poultices, carbolic glycerin, bichloride or boric-acid solution in order to prevent the microbes from advancing; menthol, hydrogen peroxide; small doses of calomel internally. The sulphide of calcium, in one-twentieth to one-tenth grain doses, administered every three hours, has seemed to me to have a most curative effect in many cases. Large doses of iron, nourishing diet. Cod-liver oil and the syrup of the hypophosphites [a pet remedy of the author]. Boric acid or the white precipitate ointment of mercury should be applied very lightly to remove the itching when the furuncle has disappeared." We think the general practitioner who in a manual seeks condensed information might get along with fewer remedies.

Page 204. In the treatment of chronic catarrh of the middle ear the old introduction of irritating substances, chloric ether, tinct. of iodine, chloroform, spir. vini, is mentioned, though without warm indorsement, by the author. The reviewer is afraid that all those remedies are frauds, producing a temporary hyperæmia and succulence of an atrophic mucous membrane, making it more elastic for the time being, but leaving it more atrophic later.

The operative technique of stapedectomy might well have been accorded less space in a student's compendium, especially when the description winds up with the sentence (page 219): "The results following extraction of the stapes have been decidedly unsatisfactory, and the operation of stapedectomy has been generally condemned.

Whereas these few criticisms do not detract from the value of the manual anything essential, there is nothing to criticise in the latter part. A good deal of valuable information is furnished in every particular. On page 282, for instance, the importance of the epidemic appearance of influenza of late is given from the annual reports of the New York Eye and Ear Infirmary. "But a few years ago only 12 to 20 cases of mastoid disease were recorded. In 1896 there were 135, in 1897 even 161 mastoid operations." This increase may not all be due to the appearance of influenza.

The author justly dwells on the importance of the readiness of the aurist to make cultures from the pus in purulent otitis media and mastoiditis, page 297. He considers streptococci the most destructive bacteria in the ear.

At the end of page 326 a child is mentioned who had symptoms of cerebellar abscess, including choked discs, with retinitis; a cure was effected by the removal of granulations from the middle ear, with the establishment of proper drainage. The neuro-retinitis disappeared.

This somewhat long review of a students' text-book may be explained by the fact that the reviewer has taken great pleasure and derived a good deal of instruction from the reading of this manual. A compendium up to date by a competent man, well acquainted with literature, and possessing personal skill and experience, is the most direct and least cumbersome source of instruction, not only for the student, but also for the riper practitioner. To the latter it is the visit of an old friend who comes from foreign lands and tells him what other people believe and do and how they do it. Dr. Bacon's text-book is heartily recommended.

H. K.

MISCELLANEOUS NOTES.

APPOINTMENTS.

Privat-docent Dr. E. BLOCH, Freiburg i/B., Extraordinary Professor.

The Titulary Extraordinary Professor HERMAN STEINBRÜGGE, of Giessen, to a regular salaried Extraordinary Professor of Otology.

Dr. FRED. WHITING, New York, Professor of Otology at the New York Polyclinic.

At the University of Copenhagen an official oto-laryngological clinic has been established and put into the hands of Professor E. SCHMIEGELOW.

One German university after the other is receiving an official, well equipped, and liberally supported oto-laryngological clinical institute, consisting, as for instance that of Rostock (Mecklenburg), of a spacious hospital, with dispensary, laboratory, operating theatre, working and consulting rooms for the executive medical officer (Prof. O. KÖRNER), two salaried assistants, nurses, isolating rooms, and private rooms for patients of the professor. The clinical institute of Halle (H. SCHWARTZE) has long been famous; that of Berlin (LUCAE, professor; JACOBSON, JANSEN, and others, assistants), the same; Strassburg, Breslau, Marburg, Bonn, and others are in way of construction. These institutions, for competent treatment of patients and scientific research, are as ideal as all the other modern institutions in the German universities, and yet the German students are not examined in otology—a strange inconsistency, soon to disappear.

Prof. JOS. GRUBER, one of Austria's celebrated otologists, having attained the limit of age, resigned his professorship at the

University of Vienna. His clinic at the General Hospital has been merged in that of Prof. A. POLITZER.

Dr. GORHAM BACON, Aural Surgeon to the New York Eye and Ear Infirmary, has been appointed Professor of Otology at Cornell University Medical School, New York. He began his lectures in October, 1898. The students will be examined in otology for their degree.

OBITUARY.

Hofrath Dr. HEINRICH SCHMALTZ, the well-known aurist, died in Dresden.

Dr. J. E. H. NICHOLS died in the summer of 1898. He was surgeon to the Manhattan Eye and Ear Hospital. An able, well informed, and skilled specialist, and an active and beloved member of the New York and American Otological Societies. His premature death is generally deplored.

Dr. J. J. B. VERMYNE, of New Bedford, Mass., died in the summer of 1898. He was born at Sutphen, Holland, 1835, educated as a physician for the Dutch navy, and served twelve years in the East and West Indies. He took part in the Franco-German war, under the Red Cross, and was decorated by the French and Dutch governments. Then he devoted several years to the study of ophthalmology and otology, and built up a large practice in New Bedford. He was Secretary of the Am. Otological Society for nineteen years, esteemed by all his colleagues for his proficiency, integrity, punctuality, and his literary attainments.

ANNOUNCEMENT.

The Thirteenth International Medical Congress will be held in Paris, from the 2d to the 9th of August, 1900. The Organization Committee of the Otological Section consists of the following gentlemen: GELLÉ, *President;* CASTEX, *Secretary;* BOUCHERON, DUPLAY, LADREIT DE LA CHARRIÈRE, LANNOIS, LŒWENBERG, LUBET-BARBON, MÉNIÈRE, MIOT, NIMIER.

For information on scientific matters, apply to M. LE DR. CASTEX, 30 Avenue de Messine, Paris; and for business matters (railway tarifs, lodgings in Paris, etc.), to M. LE DR. CHAUFFARD, Secrétaire Général du Congrès, 21 Rue de Guillaume, Paris.

Communications and papers may be in English, German, or French.

Sixth International Otol. Congress, London, August 8th to 12th, 1899. See p. 470 of this volume.

The Ninth International Ophthalmological Congress will be held at Utrecht, August 14th to 18th, 1899.

Contents of the latest issue of the Zeitschrift für Ohrenheilkunde (Germ. Ed. of these Archives).

Vol. XXX., Nos. 3 and 4. Published November, 1898.

XIII. E. Bloch, Freiburg i/B. On uniform notation of the methods and results of functional examination of the ear.

XIV. V. Urbantschitsch, Vienna. I. On hearing defects in deaf-mutes. II. On the practical pursuit of methodical hearing exercises in deaf-mute schools.

XV. R. Panse, Dresden. Tinnitus aurium.

XVI. Fr. Röpke, Solingen. Report on three cases of temporal-lobe abscess operated on, ending fatally.

XVII. P. Manasse. On giant-celled mucous cysts in polypi and inflamed mucous membranes (lithographic plate).

XVIII. Fred. Whiting, New York. Symptomatology and treatment of pyæmic sinus thrombosis, with three successful cases. (Translation from the English edition.)

XIX. E. Bloch. Primary closure of the retro-auricular wound after radical operations.

XX. Grunert, Halle. Reply to the preceding communication.

XXI. L. Treitel, Berlin. Supplement to my paper on carcinoma of the ear.

Systematic report on the progress of otology during the second quarter of 1898 (translated in this number). Report on the otological section at the seventieth meeting of the German physicians and naturalists in Düsseldorf.

Miscellaneous notes.

INDEX OF AUTHORS AND SUBJECTS.

VOL. XXVII.

ABBE, R., Discussion on Sinus Thrombosis, 577

Abscess, Cases of Extradural, 300; Epidural, with Facial Paralysis, 250; Extradural, Operation, Death Following, 362; Melancholia from an Otitic Extradural, 467; Subdural, 302

Accessory Cavities, Reports on Affections of the, 89, 199, 288, 380, 560

Actinomycosis of the Mouth, 94

Adenoid Vegetations, in Adults, 95, 391; Operations for Removal of, 96

ALDERTON, Cholesteatoma of Attic and Antrum, 261; Trephining of Stapes in Otitis Sclerosa, 361; Tuning-Fork Reaction in Affections of the Sound-Conducting Apparatus, 360

American Otological Society, Report of Transactions of, for 1898, 355

Anatomy, Reports on, 179

Antrum, Transillumination of the, 560

Attic Suppurations, Treatment of, 98

Auricle, Carcinoma of the, 555; Neoplasms on the, 466; Perichondritis of the, 302; Tuberculous Tumor of the, 462

BACON, Discussion on Sinus Thrombosis, 574; Double Mastoid Disease, 355; Review of Manual of Otology, 577

BEZOLD, Statistical Report of the Ear Patients Treated during the Years 1893–1896 Inclusive, 309; The Determination of One-Sided Deafness, Six Additional Cases of Necrosis of the Labyrinth, 158

BLAKE, Blood Clot in Mastoid Operations, 358; How Intracranial Pressure can be Utilized in Hemorrhages, 358

BLOCH, E., Appointment, 581

Book Reviews, 395, 577

Bougie, Results of Use of, 306

Brain, Abscess of the, with Fistula into Ventricles, Optic Aphasia, Recovery, 115; Cases of, 209, 237, 247, 264, 358

Bright's Disease, The Ear Affections in Acute and Chronic, 444

BURNETT, C. H., A Case of Tetanus, 263; Ætiology of Acute Mastoiditis, 262

Caisson, Observations Made in the, of the Effects of Compressed Air on the Human Ear, 1, 74, 78

Cerebral Complications of Purulent Otitis, Reports on, 81, 135, 187, 276, 375, 552

Cholesteatoma, Cases of, 261, 299

COE, Three Cases of Brain Abscess Following Otitis Media, 237

Congresses: Meetings of International Medical, of Paris, 582; of International Ophthalmological, of Utrecht, 582; of International Otological, of London, 470
Craniotomy, Cases of, in Purulent Otitis, 82

Deaf-Mutism, Reports on, 271, 461
Deafness, The Determination of One-Sided, 158
DENCH, A Case of Chronic Suppurative Otitis Media, Followed by Cerebral Abscess and Suppurative Meningitis, Operation, Death, Autopsy, 247; Brain Abscess, 263; Ossiculectomy, Wounding of Jugular Bulb, Septic Thrombosis of Internal Jugular, Operation, Recovery, 297
Detonating Balls, Injuries to Ear from, 469
Diplacusis, Binauralis, 74, 365; Unilateralis, 269
DUNN, Purulent Mastoiditis Complicated by Epidural, Subpetrous, and Post-Œsophageal Abscesses, Death, Presumably from Internal Hemorrhage, 498; Purulent Thrombosis of the Lateral Sinus, Epidural Abscess, Extensive Subperiosteal Abscess with Œdema of the Face, Scalp, and Neck, Operation, Recovery, 494

Ear, Relation of Disease of the, to that of the Eye, 181, 463
Embolism of the Ear, 463
EULENSTEIN, Contributions to the Knowledge of Pyæmia, 125
Examination and Treatment, Reports on, 182, 269, 358, 546
Exostosis, Case of Obturating, 106
External Ear, Reports on, 77, 183, 271, 366, 370, 548

Fallopian Canal, Surgery of, in Otitic Facial Paralysis, 105
Five Thousand Ear Patients, Report on Treatment of over, by Bezold, 309
Functional Examination of the Ear, 325

General Literature, Reports on, 72, 180, 267, 364, 545
German Otological Society, Report of Meeting of the, 469
GREEN, Suppuration of the Labyrinth, 357
GRUBER, JOS., Resignation of, 581
GRUENING, Abscess in Temporo-Sphenoidal Lobe, 358; Extensive Suppuration in Mastoid and Surroundings, 571; Mastoiditis with Cholesteatoma in a Child, 304; Streptococcus Mastoiditis Followed by Erysipelas, 304
GUTMANN, A Case of Bezold's Mastoiditis with Extension to the Posterior Part of the Neck, 23

Harmonics, Test of Hearing with, 460
HARRIS, Marked Improvement in Hearing as a Result of Use of Bougie, 306
Hearing, Tests for the, and Tone Exercises, 103; Theory of, 461
HEIMAN, The Most Important Cases of Middle-Ear Suppuration in the Military Hospital at Warsaw in 1896, 421
Hemorrhage, Use of Intracranial Pressure to Stop, 358
Hydrorrhœa, Case of Nasal, 388, 397

JACOBSON, "Lehrbuch der Ohrenheilkunde," Review of, 111
JOLLYE, A Case of Internal-Ear Disease Following Mumps, treated with Pilocarpine, Recovery, 20

KIPP, Accidental Opening into Semicircular Canal, 262; Discussion on Sinus Thrombosis, 574
KNAPP, ARNOLD H., Bezold Mastoiditis without Perforation of the Drum Membrane, 572

KNAPP, H., Obturating Exostosis, 106; On Radical Tympano-Mastoid Operations, 148; On the Functional Examination of the Ear, with an Exhibition of Bezold's Continuous Tone-Series, 325, 359; Perichondritis of the Auricle, 302; Report of Transactions of American Otological Society, 355

KOERNER, Escape of Cerebro-Spinal Fluid through the Nose, in Connection with Atrophy of the Optic Nerves, Probably Caused by the Perforation of the Wall of the Sphenoidal Sinus by a Tumor of the Hypophysis, 397

KÜMMEL, Further Contributions to the Pathology of Intracranial Complications of Ear Affections, 135

Labyrinth, Alterations in, after Primary Epithelioma of Middle Ear, 464; Anæmia of the, Treatment of, 191; Cartilaginous Interglobar Cavities in the, 438; in the *Torpedo ocellata*, 462; Six Cases of Necrosis of the, 158; Suppuration of the, 357

LESTER and GOMEZ, Observations Made in the Caisson of the New East River Bridge as to the Effects of Compressed Air upon the Human Ear, 1

LEWIS, Cholesteatoma Complicating Bezold's Mastoiditis, 299; Extradural Abscess, Operation, Death, 362; Two Cases of Mastoiditis of an Uncommon Character, 409

LILIENTHAL, HOWARD, Discussion on Sinus Thrombosis, 575

LUBARSCH, Chloroma in the Temporal Region, 450

MANASSE, A Case of Double Cerebral Abscess, with Fistula into the Ventricles, Optic Aphasia, Recovery, 115; On Cartilaginous Interglobar Cavities in the Capsule of the Human Labyrinth, 438

Massage, Investigations on, 468

Mastoid, Blood-Clot in Operations on the, 358; Carcinoma of the, 555; Case of Double Disease of the, 355; Inflammation of, with Cholesteatoma, in a Child, 304; Papers on Operations on the, 473, 494; Purulent Inflammation of, 498

Mastoid Diseases, Accompanied with Pachymeningitis and Extradural Abscesses, 404; Unusual Cases of, 409

Mastoiditis, A Case of Bezold's, 23, 257, 299; Ætiology of Acute, 262; Cases of Streptococcus, Followed by Erysipelas, 304

Mastoid Operation, Radical, Described, 105, 148

MCKERNON, Bezold's Mastoiditis, with Double Perforation, 257; Operation for Subdural Abscess, 302; Three Cases of Intracranial Abscess, 209

Ménière's Disease, 284; *see* Nervous Apparatus

Middle Ear, Inflammations of, in Nursing Infants, 96, 181; Mild Cases of Tuberculosis of the, with Formation of Fibrinoid, 129; Reports on the, 79, 184, 273, 371, 548; Rupture from, into Inner Ear, in Acute Suppuration, 465; Sarcoma of the, 282; Use of Rubber Bougies in Chronic Inflammations of the, and of the Tube, 97

Middle-Ear Extension, Reports on, 83, 187; Suppuration, Malignant Tumors after, 469

Miscellaneous Notes, 113, 206, 470

MORF, The Affections of the Ear in Acute and Chronic Bright's Disease, 444

Moscow Congress, Report of Transactions of the Otological Section of the, 95

Mumps, Internal-Ear Disease Following, Cured by Pilocarpine, 20

Naso-Pharynx, Reports on Diseases of the, 91, 202, 285, 379, 391, 558

Nervous Apparatus, Reports on Affections of the, 85, 190, 378, 556
New York Academy of Medicine, Report of the Transactions of the Sections of Ophthalmology and Otology at the, 108, 297, 571
New York Otological Society, Meeting of, 259
NICHOLS, J. E. H., Death of, 582
Nose, Foreign Bodies in the, 386; Neoplasms of the, Reports on, 88, 197, 290, 383, 562; Reports on Diseases of the, 85, 193, 379, 558; Reports on Septum of the, 87, 196, 288, 380, 559; Sarcoma of the, 383; Symptomatology and Pathology of the, Reports on 85, 196, 286, 379, 558; Therapeutics of the, Reports on, 86, 380, 558

Ossicles, Caries of the, 372; Operations on the, Followed with Thrombosis of Internal Jugular Vein, 297
Otitic Pyæmia, Treatment of, 99, 100, 102, 185
Otitis Externa, Alcohol Treatment of, 466; Case of Primary, 106
Otitis Media, in Infants, 463; Reports on, 80, 186, 274, 372, 550; Surgical Treatment of, 102
Otology, Auto-Infection in, 104; Establishment of Clinics of, in German Universities, 581
Otomycosis, Boric Acid and Zinc Oxide in, 361
Ozæna, Reports on, 195, 287, 559

PASSOW, On the Retro-Auricular Opening after the Radical Operation for Chronic Middle-Ear Suppuration, 223
Pathological Specimens, Exhibition of, 466
Physiology, Reports on, 72, 180, 363, 544
PREYSING, Sinus Disease, of Otitic Origin, and General Infection, Central Deafness in Suppurative Affections of the Cranial Cavity, 341; Two Cases of Pachymeningitis Externa and Extradural Abscess Occurring in Acute Mastoid Disease, 404
PRITCHARD and CHEATLE, The Onset of Inherited Syphilitic Deafness, 415
Pyæmia, Contributions to the Knowledge of, 125

Radical Operation, On the Retro-Auricular Opening after the, for Middle-Ear Suppuration, 223; Transplantation of Skin after the, 469
RANDALL, A., Discussion on Sinus Thrombosis, 573
Report, Systematic, of the Progress of Otology from the Second Quarter of the Year 1897 to the Second Quarter of 1898, 72, 179, 266, 363, 544
Round Window, Puncture of the, in Vertigo, Tinnitus, and Some Labyrinthine Affections, 104

SATTLER, A Contribution to the Surgery of the Temporal Bone, 473
SCHEIBE, On Mild Cases of Middle-Ear Tuberculosis and Accompanying Formation of Fibrinoid, 129
SCHMALTZ, H., Death of, 582
Semicircular Canals, Accidental Opening of, 262
SHEPHARD, Case of Sinus Thrombosis, 357; Discussion on Sinus Thrombosis, 575
Sinus, Diseases of the, Due to Otitic and Rhinitic Affection, 341
Sinus Thrombosis, Various Papers on, 26, 108, 188, 278, 357, 494, 506
Skull, Fractures of, and Ear Affections, 192
Stapes, Operative Treatment of Anchylosis of the, 469; Trephining of, in Otitis Sclerosa, 361
STEINBRÜGGE, H., Appointment, 581
Symptomatology and Pathology, Reports on, 73, 180, 268, 365, 546
Syphilis of the Ear, 285, 415

Tensor Tympani, Reflex Excitability of, in Waves of Sound, 462
Tests, Scheme for Uniformity of Hearing, 459
Tetanus, A Case of, 263
THEOBALD, Treatment of Otomycosis with Insufflation of Boric Acid and Zinc Oxide, 351
Thrombosis, Isolated, of the Jugular Bulb, 468
Tinnitus and Vertigo, Treatment of, by Perforating the Round Window, 104; Papers on, 468
TOEPLITZ, The Radical Operation, 304
Tonsillotomy, Hemorrhage Following, 335
Tonsils, Diseases of the, Reports on, 294; Relation of Hypertrophy of the, to Tuberculosis, 466
Tuberculosis of the Ear, 129, 274, 466, 551
Tuning-Fork, Reaction of, in Ear Diseases, 369
Tympanum, Tumor of the, 464

Velum, Pharynx, and Oral Cavity, Reports on Diseases of the, 91, 203, 295, 392, 565
VERMYNE, J. J. B., Death of, 582

WHITING, A Case of Perisinuous Subdural Abscess with Facial Paralysis, 250; A Contribution to the Clinical Stages and to the Technique of the Operation for Sinus Thrombosis, 506; A Contribution to the Symptomatology and Treatment of Pyæmic Sinus Thrombosis Based on Three Successfully Operated Cases, 26; Extradural Abscess with Extirpation of the Petrous Pyramid, 300; Appointment, 581

"Year Book of Treatment," Review of, 395

ZIMMERMANN, Hemorrhage Following Tonsillotomy, 335
ZWINGMANN, Report of the Transactions of the Section of Otology at the Moscow Congress of 1897, 95

Die vier auf der and

Fall 6 rechts.

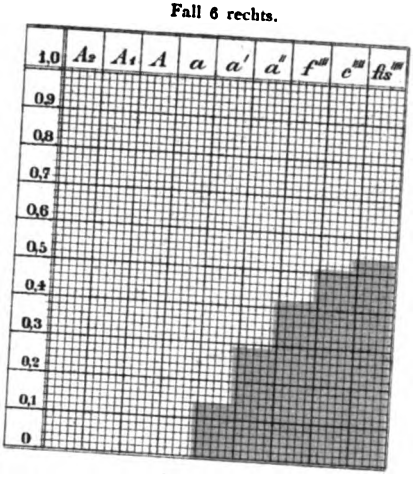

Fa

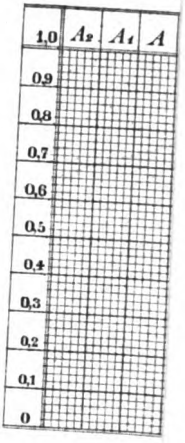

Fall 6 links.



Fa

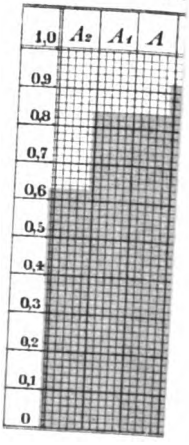

Die drei auf d

Fall 4 links.

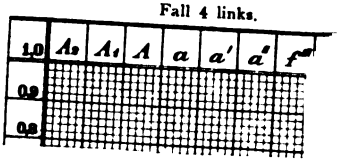

ren Seite annähernd normal hörenden Labyrinthlos

Labyrinthlose Seite.

links.

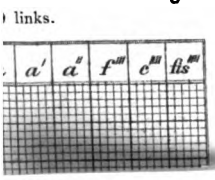

Fall 2 links.

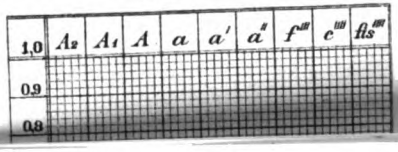

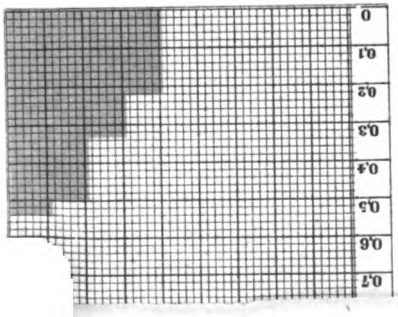

Fall 4 rechts.

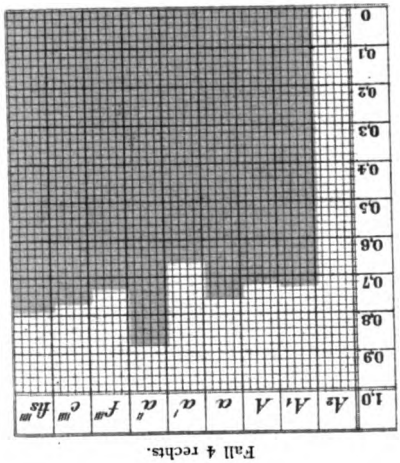

Bezold.

KGL. UNIVERSITÄTS-DRUCKEREI VON H. STÜRTZ, WÜRZBURG.

rinthlos

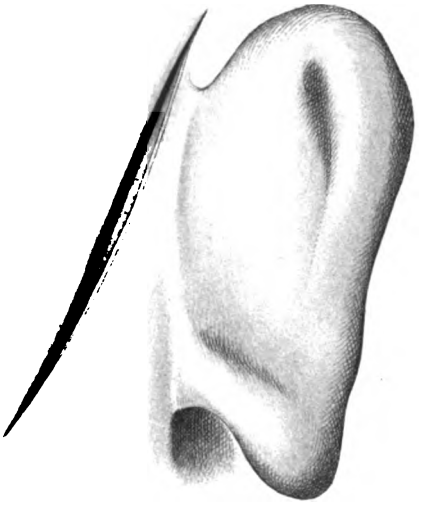

Fig. 1

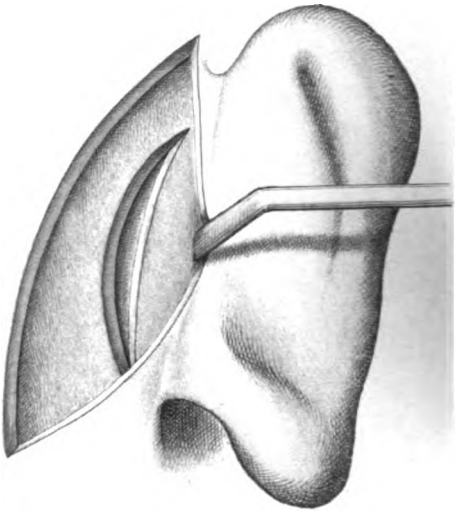

Fig. 2

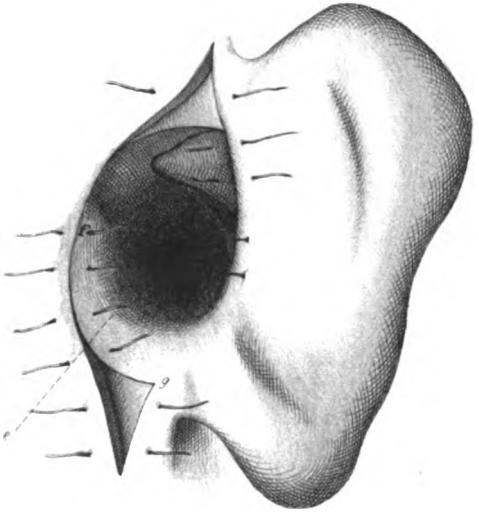

Fig. 5.

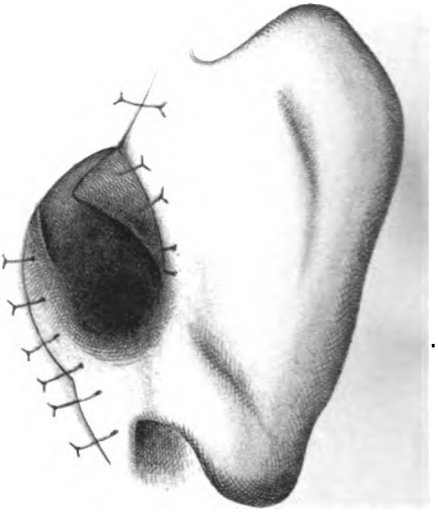

Fig. 6.

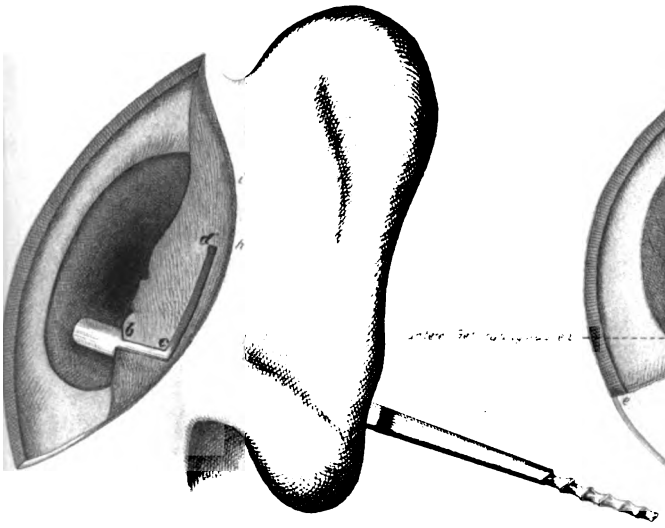

Fig. 3.

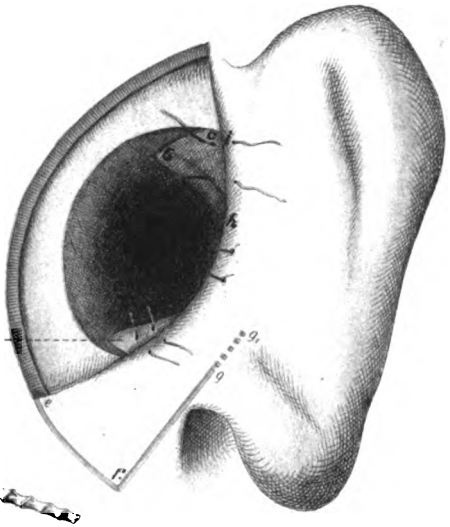

Fig. 4.

Fig. 7

Fig. 8

Fig. 9

1.

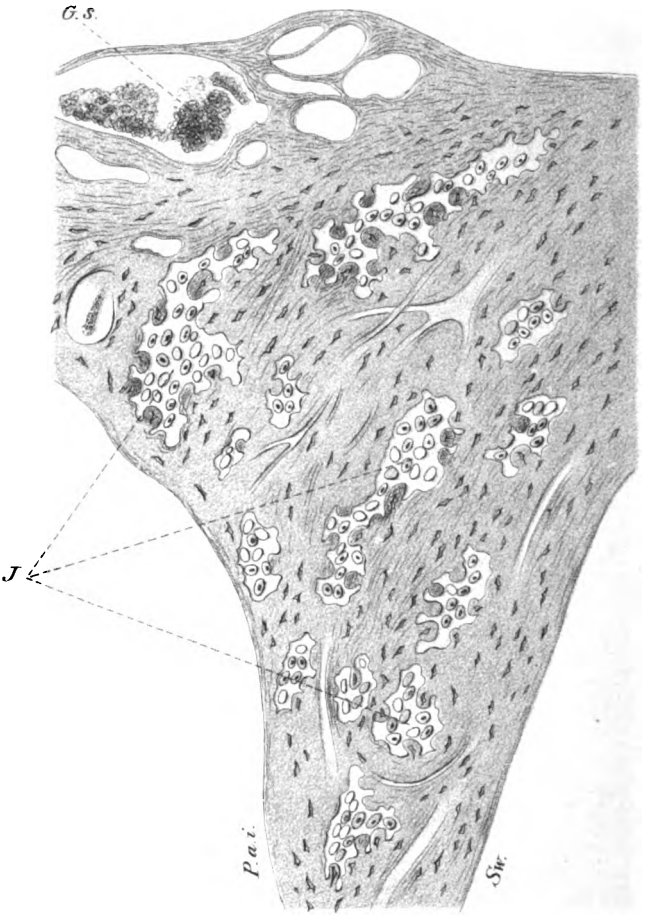

E. Kretz del. C. Krapf lith.

2.

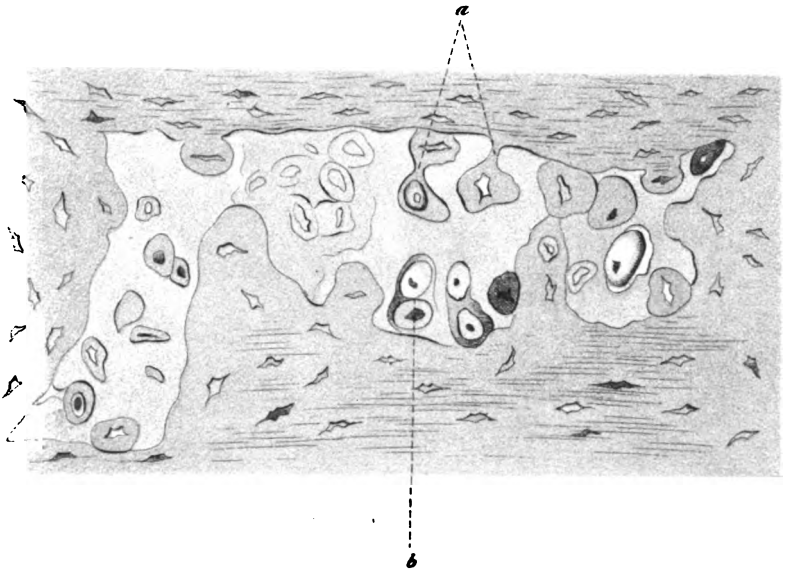

3.

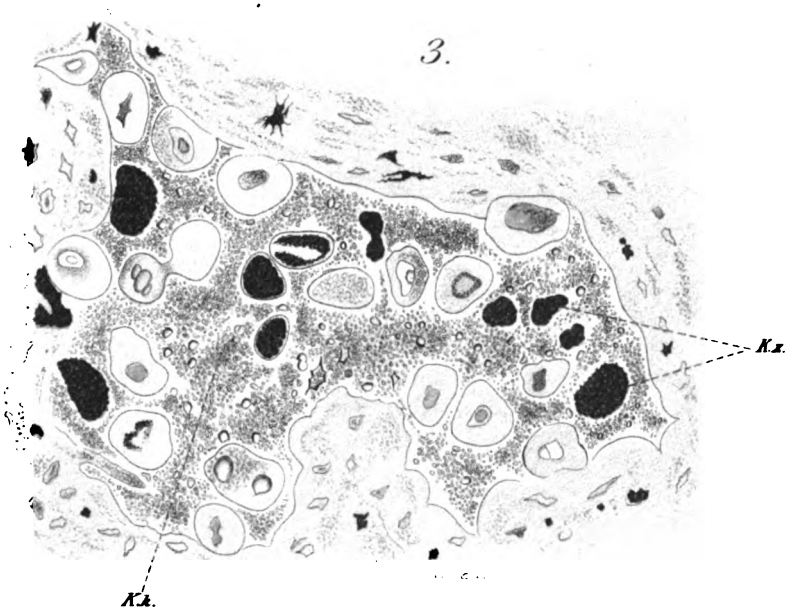

Verlag v. C. F. Bergmann in Wiesbaden

edies, and instruments, and to discuss in a progressive, yet conservative spirit all questions of present importance.

The ARCHIVES contain exclusively original papers on all branches of Ophthalmic and Aural Surgery, and original reports on the progress of Ophthalmology and Otology throughout the world. The original papers occupy about three-fourths of the space, and their scope embraces all subjects of scientific and practical interest in the departments of Ophthalmology and Otology.

Special attention is paid to the preparation of the Reports on the Progress of Ophthalmology and Otology. These Reports are intended to furnish *complete, systematic, and early reviews* of the current Ophthalmological and Otological literature of the world, and the work of preparing them is divided among a specially selected number of collaborators.

Under the heading of "Miscellaneous Notes" there will be published all kinds of professional news that concerns the Oculist and Aurist, *e.g*, appointments, honors, resignations and vacancies, new ophthalmic and aural hospitals, prize questions and essays, announcements of Society meetings, etc.

Each volume contains besides a specified table of contents, an index of subjects and authors, both of the original papers and the reports, and a general index of the preceding seven years is added to every seventh volume.

Original papers of value from any source are solicited.

Communications for the English edition of the ARCHIVES OF OPHTHALMOLOGY should be addressed to DR. H. KNAPP, 26 West 40th Street, New York, those for the ARCHIVES OF OTOLOGY either to DR. H. KNAPP, or to DR. U. PRITCHARD, 26 Wimpole Street, W., London, England.

G. P. PUTNAM'S SONS, Publishers

NEW YORK
27 & 29 WEST 23D STREET.

LONDON
24 BEDFORD ST., STRAND.

PUBLISHER OF THE GERMAN EDITION
I. F. BERGMANN
20 Schwalbacher Strasse, Wiesbaden.

EDITORIAL NOTE.

In asking for continued support of the ARCHIVES from subscribers and contributors, the Editors offer no new program, but point to the record of the work that has been accomplished during the past twenty-eight years. At the first appearance of the ARCHIVES in 1869, they constituted the only periodical of their class in America, and had only a few predecessors in Europe. The international character of the ARCHIVES was a novel and distinctive feature.

The original program of the ARCHIVES to publish only original papers in semi-annual independent numbers has, in the course of years, been extended by the addition of reviews of the current ophthalmological and otological literature.

With the eighth volume, in 1879, the combined ARCHIVES, issued semi-annually, were divided into two separate journals, issued quarterly, and each of about the same size as the combined journal, and the reviews were converted into quarterly reports, systematic and comprehensive, though concise, on the progress of ophthalmology and otology.

Since that date, the ARCHIVES have developed into an extensive and conveniently arranged storehouse of knowledge for the instruction of the student and for reference by the practitioner and the investigator.

For more than ten years, the valuable material offered to the ARCHIVES has been so abundant that it has not been practicable to utilize for the English edition the full series of papers from the German, or the converse. Many articles had to be abridged, while of others abstracts only could be printed. Any one of our readers could, however, have secured, and can secure in future, from the American editor, or the German publisher, the loan of the original papers presenting the complete text.

It is the purpose of the editors to arrange, in the department of Reports, for the review of every publication which in their opinion contains material that can be called distinctive and important. It is, of course, impossible, within the limits of the ARCHIVES or of any similar journal, to give attention to every publication in their department of science. We may state further that it is not a part of our program to furnish a complete report on the *bibliography*, but only on the **progress** of ophthalmology and otology.

Though the systematic arrangement of the reviews is of importance for reference and comprehensive information, we shall publish, as early after the meetings as practicable, reports of the proceedings of societies, always bearing in mind that the ARCHIVES are not intended to be only a repertory of knowledge, but also a journal of news.

It is natural that the English edition of the ARCHIVES should give the advantage of time and space to Anglo-American contributors over the German, and *vice versa*. It is evident, however, that the association of the two editions lends strength to each, furnishing to the authors a wider circulation for their papers, and to the readers a larger and more diversified field of information.

NOTICE TO CONTRIBUTORS.

The editors and publishers of the ARCHIVES beg to offer some suggestions to authors who propose to favor them with their contributions.

1. As original communications the ARCHIVES can accept only such papers as have never been printed nor are intended to be printed in other journals. If a preliminary communication on the subject of a paper has been published, the author is requested to state this in the letter accompanying his manuscript. It is understood that contributors to these ARCHIVES and editors of other periodicals will make no abstracts of original papers published in this journal without giving it due credit for the same.

2. Authors will receive gratuitously twenty-five reprints of their articles. If a greater number is desired,—notice of which should be given at the head of the manuscript,—only the additional cost of presswork and paper will be charged to the author.

3. In preparing manuscript for the compositor it is requested that the following rules be adhered to :

a. Write on one side of the paper only.

b. Write without breaks, *i. e.*, do not begin a new sentence on a new line. When you want to begin a new line or paragraph at a given word, place before it in your MS. the sign ¶.

c. Draw a line along the margin of such paragraphs as should be printed in smaller type—for instance, all that is clinical history in reports of cases, etc.

d. Words to be printed in *italics* should be underscored once, in SMALL CAPITALS twice, in LARGE CAPITALS three times, **condensed** and **heavier** antique should be so marked.

e. Let the title of your paper indicate its contents. If it is a general title, for instance, Clinical Contributions, mention the subject of each special communication,—for instance : CASE I. Lenticonus posterior ; CASE II. Bilateral homonymous hemianopsia, etc. These special titles will appear in the table of contents of each number and each volume, under the heading of the general title, lest they be overlooked. Illustrations should be carefully drawn on separate sheets.

4. Authors receive proofs for revision, which they should correct and return without delay. We beg, however, to remind our contributors that changes in the copy are equivalent to resetting, causing so much additional expense. We therefore request them to make, if possible, no alterations at all in their MSS., or, at least, to limit them to what is of essential importance.

ISSUED BI-MONTHLY. VOL. XXVII., No. 6

ARCHIVES

OF

OTOLOGY

EDITED IN ENGLISH AND GERMAN

BY

DR. H. KNAPP
OF NEW YORK

DR. O. KÖRNER
OF ROSTOCK

DR. A. HARTMANN AND DR. U. PRITCHARD
OF BERLIN OF LONDON

DECEMBER

NEW YORK
G. P. PUTNAM'S SONS, 27 & 29 WEST 23D STREET
AND NEW ROCHELLE, N. Y.
LONDON: 24 BEDFORD STREET, STRAND
WIESBADEN: J. F. BERGMANN'S Verlag
PARIS: J. B. BAILLIÈRE, 19 Rue Hautefeuille

1898

Price, per Number, 75c. (3s.); Per Year, $4 00 (16s.)
Ophthalmology and Otology, together, per year, $9 00 (£1 16s. 6d.)
Entered at the Post-Office, New Rochelle, N. Y., as Second-Class Mail Matter

SCHOOL OF OPHTHALMOLOGY AND OTOLOGY

AT THE

N. Y. OPHTHALMIC AND AURAL INSTITUTE.

44 & 46 East 12th Street, NEW YORK.

A *regular course* of instruction is given uninterruptedly from October to the middle of June, inclusive, comprising the following studies:

1. Dispensary Practice of Eye, Ear, Nose, and Throat Patients. Daily from 2 to 4 o'clock by the attending surgeons and assistant surgeons.
2. Regular Clinics in Dispensary, Hospital, and Operating Room. Held by Dr. HERMAN KNAPP, daily from 3 to 5 o'clock. $5 a month.
3. Practical Exercises in Operating on the Eye and Ear in the Deadhouse and Laboratory. By Dr. R. O. BORN. $15.
4. Physical Diagnosis of Eye Diseases. By Dr. F. E. D'OENCH. $10.
5. Refraction and Motility of the Eye. By Dr. H. H. TYSON. $10.
6. Diagnosis and Treatment of Ear, Nose, and Throat Diseases. By Dr. M. TÖPLITZ. $10.
7. Histology and Bacteriology of the Eye and Ear. By Dr. W. A. HOLDEN and Dr. ARNOLD H. KNAPP. $15.

Fee for the whole regular course, $100; for examination and diploma, $15.

As *special studies*, are offered:

(a) Topographical Anatomy of the parts concerned in the operations on the Eye, Ear, Nose, and the Surrounding Cavities, at hours to suit. By Dr. ARNOLD H. KNAPP. $10.

(b) Physiological Optics and Acoustics applied to Ophthalmology and Otology. By Dr. A. DUANE. $10.

(c) Original Investigations in the Laboratory of the Institute.

The School is only for Graduates of Medicine. They can enter at any time, select their studies, and pursue them as long as they choose.

The Institute grants the following *certificates*:

1. **Certificate of Proficiency** to those who attend the regular course and pass a satisfactory examination, written, orally, and practically. Signed by the President, Vice-President, Secretary, and the teachers of the Institute.
2. **Certificate of Attendance** to those who attend the full course, without undergoing an examination. Signed by the teachers.
3. **Certificate of Attendance to Single Courses,** specifying the study and time of attendance. Signed by the teacher.

For further particulars apply to

DR. H. KNAPP, 26 West 40th Street, New York.